in vivo *36*: 839-847 (2022)
doi:10.21873/invivo.12771

Preoperative Ultrasound-guided Sub-areolar Biopsy in Predicting Occult Nipple Involvement in Breast Cancer Patients: Proposal for a Methodological Approach

VITTORIO ALTOMARE[1], PAOLO ORSARIA[1], ANTONELLA GRASSO[1], LORENZA CAGGIATI[1], EDY IPPOLITO[2], FRANCESCO PANTANO[3], MATTEO SAMMARRA[4], CARLO ALTOMARE[4], GIUSEPPE PERRONE[5], GABRIELLA GULLOTTA[5] and RITA CARINO[1]

[1]*Department of Breast Surgery, Campus Bio-Medico University, Rome, Italy;*
[2]*Department of Radiation Oncology, Campus Bio-Medico University, Rome, Italy;*
[3]*Department of Medical Oncology, Campus Bio-Medico University, Rome, Italy;*
[4]*Department of Radiology, Campus Bio-Medico University, Rome, Italy;*
[5]*Department of Anatomical Pathology, Campus Bio-Medico University, Rome, Italy*

Abstract. *Background/Aim: The prediction of a sub-areolar tissue infiltration in breast cancer (BC) patients could be helpful in selecting the best functional outcome according to several reconstructive oncoplastic or radical techniques. This study aims to evaluate the diagnostic performance of preoperative ultrasound (US) guided sub-areolar biopsy (SAB) in detecting occult nipple involvement, in comparison with the definitive pathological examination of tissue after surgery. Patients and Methods: We prospectively recorded clinical and pathological data of 46 consecutive patients scheduled for breast conserving surgery or nipple-areola sparing mastectomy. All cases underwent preoperative SAB and the results were compared with the histopathology of the dissected tumors and their biological characteristics. All parameters were correlated with nipple involvement by univariate and multivariate analysis. Results: The sensitivity, specificity, overall accuracy, positive predictive value, and negative predictive value of the SAB examination for nipple staging were 60%, 97.5%, 75% and 95.2%, respectively. According to the clinicopathological features, the bivariate analysis did not show a significant interaction between patient age, tumor size or type, lymph node status, lymphatic vascular invasion, histologic grade, ER, PR, Ki-67 status, HER2 amplification, multifocal or multicentric disease and positive NAC assessment (p>0.05). Conclusion: A preoperative sample of retroareolar tissue obtained by US-guided biopsy could be considered a reproducible, mini-invasive diagnostic procedure useful to facilitate immediate breast reconstruction with implants or through conservative oncoplastic approaches, thereby guiding clinical practice.*

This article is freely accessible online.

Correspondence to: Paolo Orsaria, Alvaro de Portillo Street 200, 00128, Rome, Italy. Tel: +39 3282492485, e-mail: orsaria@aol.it

Key Words: Breast cancer, core needle biopsy, nipple areola sparing, immediate reconstruction, oncoplastic surgery.

Among large cohort studies the sub-areolar tissue involvement in breast cancer (BC) patients varies from 5.6% to 26.4% (1). Furthermore, the definition of this pathological feature could be helpful in selecting the best functional outcome according to several reconstructive techniques of conservative oncoplastic or radical surgery, with a major role in determining the rate of "nipple sparing" mastectomy and immediate reconstruction (2-3). In this context, although multi-parametric analyses show significant correlations between areolar malignancy and several prognostic factors like tumor stage, node metastases, central location, skin retraction, proximal margin width, extensive intraductal component, high nuclear grade and human epidermal growth factor (HER2) overexpression, several predictive models still indicate a heterogeneous spectrum of results (4-7). Even the standard diagnostic imaging techniques (ultrasound, mammography, magnetic resonance) play an important role in determining the oncological safety of nipple areola complex (NAC) preservation representing valuable predictive tools of local pathology with variable levels of sensitivity (33%-67%) and specificity (88%-94%) (8). In particular, MRI is a sensitive investigation for NAC involvement with good positive (PPV 96.3%, range=88.8%-100%) and negative predictive values (NPV 67.95%, range=56.7%-79.2%), especially in cases of local contrast enhancement, or low tumor-areola distance (cut-off 5 mm:

PPV 82.3%, NPV 79.6%). Thus, by integrating these criteria it is possible to determine new preoperative evaluations with an optimal sensitivity (82.5%) and specificity (88.9%) (9). However, intraoperative histological evaluation through a frozen section analysis of the retroareolar tissue remains one of the most accredited options for applying a parenchymal surgical preservation compatible with the viability of the complex. This procedure is characterized by low false negative (FN) rate (1.5%-16.2%) and high accuracy (84.6%-95.4%) but involves an increased surgical time with resource management implications and negative consequences on the cognitive function of patients (10-15). The costs of this examination, in relation to the time interval required, must therefore be related to potential advantages derived from the favorable perspective to not carry out further surgery to ensure a radical treatment (NAC removal). However, the overall balance of the following parameters may be marginally negative, despite several potential benefits in oncological and reconstructive clinical practice (16).

Nowadays, radio-guided core needle biopsy (CNB) represents a standard technique to analyze suspicious breast lesions or structural alterations highlighted by diagnostic imaging. Furthermore, the preoperative histological abnormality characterization ensures a reliable assessment of several prognostic and therapeutic characteristics based on the expression of biological and molecular profiles (17). This minimally invasive outpatient procedure is generally practiced under local anesthesia, through a real-time imaging processed under ultrasound (US) or stereotactic support and is characterized by a minimal incidence of complications with favorable evolution (bleeding, hematoma, infection, pain) (18). Therefore, the pathological evaluation provided by micro-histological sampling obtained by a suitable instrumental and radiological assistance is a significant prerequisite for the correct planning of therapeutic management in order to increase the quality standards. In this context, the morphological categories reported by the European Guidelines classification system (B1-B5), offer new interpretative frameworks with variable dimension risks that require a multidisciplinary assessment (19-20). At the same time, the fine needle aspiration cytology (FNAC) also plays an important role in the preoperative identification of nodal malignancy with a high level of specificity (92.5%-98.8%) able to discriminate patients designated for selective lymph node biopsy rather than axillary dissection even before neoadjuvant treatment (21-22). Therefore, in this study, the possibility to predict an occult pathological NAC malignancy by US-CNB, in all patient candidates for breast cancer surgery, is proposed as an experimental method in the programmatic evaluation of different conservative or demolitive surgical procedures (23). The aim of the current research is to investigate the diagnostic performance of imaging-guided sub-areolar biopsy (SAB) in detecting NAC tumor involvement, evaluating the concordance between histopathological features of this preoperative tissue sampling with the definitive pathological examination of tissue after surgery.

The value of several clinical and biological parameters is also assessed to verify any possible relationship with the outcome of the procedure (retroareolar histological positivity or negativity by preoperative radio-guided SAB). Furthermore, the ability of this technique to guarantee oncological safety and the quality of reconstructive results with and without the use of prosthetic implants will be evaluated, through a selective comparison of locoregional disease free survival for a period of at least two years, with the aim of defining the impact of this procedure on the NAC recurrence rate. Thus, the comparative analysis of the accuracy of this diagnostic modality could be useful in determining modern and heterogeneous perspectives on the nipple areola complex preservation, as well as accurate local preoperative staging, in order to get the best oncological and functional results.

Patients and Methods

Patient selection. The analysis included a series of 46 consecutive Nipple-Sparing Mastectomy (NSM) or central segmentectomy performed for breast cancer at the Academic Breast Unit of Campus Bio-medico, University of Rome from October 2018 to April 2021. We obtained the data regarding patient history, surgical treatment, preoperative and final histopathological report through the prospective institutional database. All the elegible patients treated at our Institute provided informed written consent (ethical statement n. 04.19 PAR V ComET CBM).

Elegibility criteria. This pilot study with interventional and non-pharmacological design used the following inclusion criteria: Patients were eligible if they were older than 18 years, had a histological diagnosis of invasive breast cancer within 3 months, had a primary tumor deemed technically appropriate for surgical resection, and had no clinical evidence of regional nodal or distant metastatic disease. We did not exclude patients based on tumor size, age or lymph node status and previous primary systemic treatment. Furthermore, in our institution we routinely measured the tumor-nipple distance by breast preoperative mammogram (MX) or magnetic resonance imaging (MRI) when performed according to the indications. Conversely, a NAC preserving surgery was not offered to women with either clinical or radiological nipple involvement, as well as to locally advanced BC with skin retraction, inflammatory or Paget disease and pathologic nipple discharge with C5 and C4 cytological findings.

Study design and conduct. All cases were prospectively recruited for preoperative US-guided sub-areolar biopsy (14G needle, 3-5 specimens obtained in a variable location of tissue from 3-8 mm with respect to NAC) in order to assess the presence of tumor local spread, before any oncoplastic or reconstructive treatment. Women fasted for at least 5 hours before the outpatient clinical procedure,

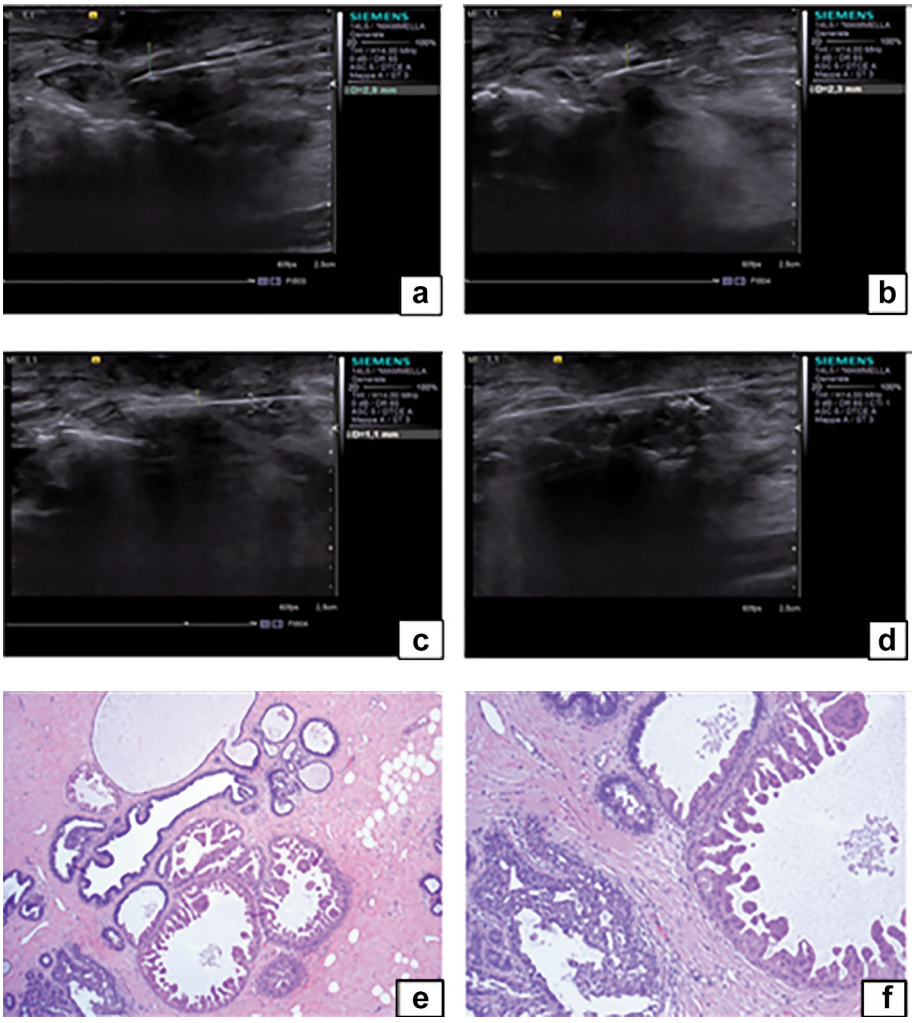

Figure 1. *Preoperative US-guided sub-areolar biopsy. (A, B) Screenshots from the procedure using 14 G core needle to analyze the tissue under the nipple at different levels in order to verify occult infiltration. (C) Fourteen gauge biopsy needle positioned adjacent to the nipple. The coordinates for optimal needle position can be read from the top of the screen, to confirm several positioning of the sampling (e.g., 2.9, 2.3, 1.1 mm), (D) Sampling of the sub-areolar tissue with the cutting cannula released. (E, F) No malignancy was found and subsequently confirmed after final patohological sub-areolar tissue assessment. Histopathological results revealed non atypical hyperplasia with cystic degeneration.*

usually performed under local anesthesia (5-10 ml of 1% lidocaine without vasoconstrictor). After that the antisepsis of the exposed area was ensured by means of sterile gauze pad and antiseptic solution, the subareolar tissue to be biopsied was identified with the transducer and subsequently collected after a 2-3 mm periareolar incision made on the numbed skin with a scalpel blade (Figure 1A-D). Once the samples were obtained, the area was compressed for at least five minutes, and a dressing was then applied, with ice on the biopsy site. It was requested to avoid more intense physical exertion for at least two days. Pain relieving and anti-inflammatory medications were prescribed as necessary, avoiding the use of acetylsalicylic acid for seven days after the procedure.

Patients were required to proceed with NAC preservation when tissue examination showed no evidence of malignancy, and to undergo NAC removal if cancer cells were detected from histological sections (Figure 1E, F). The breast tissue removed during radical or conservative surgery was marked on the areolar side to obtain ductal tissue just beneath the base of the nipple for permanent histological sections of 4 μm each at 10 μm intervals. These were subsequently stained by hematoxylin and eosin and evaluated by a pathologist with specific expertise in breast pathology. If a negative CNB turned out to be positive at final examination, we recalled the patient and removed the NAC. Finally, a data comparison between preoperative and final subareolar tissue analysis was performed in order to assess the accuracy of the US-guided sampling.

Classification of groups and staging. The size of the breast tumours was measured and classified according to the American Joint Committee on Cancer (8th edition) staging criteria, *i.e.*, T1a-b (<10 mm), T1c (11-20 mm), T2 (21-50 mm), or T3 (>50 mm) (24). The number, maximum size, and nuclear grade of the involved invasive

BC and axillary LN metastases were also examined by histopathology. The intrinsic BC subtypes were identified according to the clinicopathological criteria recommended by the 2013 St. Gallen International Expert Consensus Report (25). The patients were categorized based on the receptor status of their primary tumour as follows: luminal A [oestrogen receptor-positive (OR+) or progesterone receptor-positive (PR+) and HER2–]; luminal B HER2– (OR+, HER2–, and at least one of Ki-67 "high" or PR "negative or low"); luminal B HER2+ (OR+, HER2 overexpressed or amplified, any Ki-67 value, any PR); HER2 (OR– or PR– and HER2+), or basal (OR– or PR– and HER2–). Tumours were considered HER2-positive only if they were scored as 3+ by immunohistochemistry (IHC; strong, complete membrane-staining in >10% of cancer cells) or showed HER2 amplification (ratio >2) using fluorescence *in situ* hybridization (FISH). In the absence of positive FISH data, tumours scored as 2+ on IHC were considered negative for HER2. Tumours were also classified as luminal or non-luminal according to hormone receptor expression. The primary disease was classified as multifocal at the time of initial diagnostic work-up if the radiologist or histological assessment available after surgery described two or more tumors separated by ≥1cm of normal-parenchyma.

Furthermore, when available data regarding preoperative distance from cancer to nipple (measured using MG and MRI) were available, they were prospectively collected and correlated with the final pathological sub-areolar tissue assessment.

Statistical analysis. The diagnostic performance of US-guided sub-areolar biopsy in detecting NAC involvement was analyzed based on the calculation of sensitivity [TP/(TP+FN)], specificity [TN/(TN+FP)], PPV [TP/(TP+FP)], and NPV [TN/(TN+FN)]. The overall accuracy was calculated as the percentage of all TP and TN out of the total number of cases. Furthermore, the associations between occult nipple malignancy and clinicopathological factors (age, invasive tumor size, nuclear grade, lymphovascular invasion, ER, PR and HER2 status, molecular subtypes, and Ki-67 labeling index) or radiological data were examined. Continuous variables were evaluated by Student's *t*-test (2 sided); categorical variables were evaluated by the chi-square test or Fisher's exact test where appropriate. A value of $p<0.05$ was considered statistically significant. All statistical and stratified analyses were performed using IBM SPSS 23 software (IBM, SPSS Statistics, Chicago, IL, USA).

Results

The series included 41 mastectomy (34 nipple sparing and 7 skin sparing) and 5 therapeutic mammoplasty or breast conserving surgery. Table I shows demographic information on patients' and primary tumor characteristics. The median age at the surgery was 49.8 years (range=38-75 years), and 34.8% (*n*=16) of the patients were peri- or postmenopausal. The average tumour size was 2.2 cm (range=0.2-3.8 cm), while the median tumor-NAC distance, measured by MX or MRI was 29 mm (range=7-62 mm) and 26 mm respectively (range=7-58 mm). The primary disease was classified as multifocal in 33 (71.7%) and multicentric in 21 (45.6%) at the time of initial diagnostic work-up, and nine (19.5%) of these 46 patientsreceived neoadjuvant chemotherapy before surgery.

The most common histotype in the primary tumor was invasive ductal carcinoma (29/46=63%), followed by ductal carcinoma *in situ* (10/46=21.7%), invasive lobular carcinoma (6/46=13%) and mixed or special histotypes (1/46=2.1%). A ductal carcinoma *in situ* (DCIS) was associated with invasive disease in more than half of invasive breast cancer cases (26/36=72.2%), while defining nuclear grade, 19.6% (*n*=9) were scored as G1, 36.9 % (*n*=17) as G2, and 43.5% (*n*=20) as G3.

The incidence of luminal and non-luminal infiltrating tumours was 86.1% and 13.9%, respectively.

The majority of patients had luminal A tumors (17/36=47.2%), followed by luminal B HER2-tumors (11/36=30.5%), HER2-positive luminal B (3/36=8.3%), non-luminal HER2-positive (3/36=8.3%), and triple-negative (2/36=5.5%). Overexpression of c-erbB-2 was found in 6/36 cases (16.6%) and fourteen patients (14/36=38.8%) had a high Ki-67 expression (≥20%). Most ductal *in situ* carcinomas were over 10 mm (8/10=80%) and with prevailing hormone receptor positivity (9/10=90%).

Thirty-three (71.7%) of the 46 patients were staged as pN0, and thirteen (28.3%) had ipsilateral axillary LN metastases according to the gold standard. N stage was categorized by the staging system of the American Joint Committee on Cancer (8th edition): 9 patients (19.5%) were in N stage 1, 3 (6.5%) in N stage 2, and 1 (2.1%) in N stage 3. There were 13 patients (28.3%) in stage 0, 18 (39.1%) in stage I, 11 (23.9%) in stage II and 4 (8.7%) in stage III.

In all cases, we performed preoperative sub-areolar biopsy section examination in order to predict occult NAC involvement. In 4/46 cases (8.6%) the section of the SAB was positive for cancer, and in 4/4 cases (100%) the NAC was removed. The histology of the positive SAT was 2 DCIS (high grade with comedonecrosis), and 2 DCI+DCIS (1 high grade Luminal A and 1 high grade HER2 subtype, both of them with T2 pathological stage). Overall, only 3 of 4 cases (75%) had tumor in the sub-areolar tissue sampling at conclusive pathology (Table I).

Concordance between the preoperative SAB and postoperative paraffin-embedded sections of retroareolar tissue. We compared the original report of the preoperative SAB examination with the result of the paraffin-embedded post-operative specimen. Out of 46 examinations of the SAB, 42 (91.3%) yielded negative results and 4 (8.7%) yielded positive results. Two of the 42 negative SAB specimens turned out to contain cancer cells at the sub-areolar side permanent section (false negative rate 4.7%); conversely, one out of the 4 positive specimens at SAB section turned out to be negative (false positive rate 25%).

The statistical analysis of the SAB examination showed a sensitivity (Se) of 60%, a specificity (Sp) of 97.5%, a positive predictive value (PPV) of 75%, a negative predictive value of 95.2%, and an Accuracy of 93.4% (Table II).

Table I. *Comparison of patient and clinicopathologic features according to NAC involvement*.

Characteristics	Occult nipple involvement			*p*-Value	Characteristics	Occult nipple involvement			*p*-Value
	Total, N (%)	–, n (%)	+, n (%)			Total, N (%)	–, n (%)	+, n (%)	
Age at diagnosis	46			0.884	Pathological stage	46			0.845
<50 years	30 (65.2)	27 (90)	3 (10)		0	13 (28.3)	12 (92.3)	1 (7.7)	
≥50 years	16 (34.8)	14 (87.5)	2 (12.5)		I	18 (39,1)	17 (94.4)	1 (5.6)	
Tumor type	46			0.570	II	11 (23.9)	9 (81.8)	2 (18.2)	
IDC	7 (15.2)	7 (100)	0 (0)		III	4 (8.7)	3 (75)	1 (25)	
IDC and DCIS	22 (47.8)	19 (86.4)	3 (13.6)		Histology grade	46			0.163
ILC	2 (4.4)	2 (100)	0 (0)		Grade 1	9 (19.6)	9 (100)	0 (0)	
ILC and DCIS	4 (8.7)	3 (75)	1 (25)		Grade 2	17 (36.9)	16 (94.1)	1 (5.9)	
DCIS only	10 (21.7)	9 (90)	1 (10)		Grade 3	20 (43.5)	16 (80)	4 (20)	
Others	1 (2.2)	1 (100)	0 (1)		ER	46			0.520
Multifocal	46			0.301	≥50	40 (86.9)	36 (90)	4 (10)	
Absent	13 (28.3)	13 (100)	0 (0)		<50	6 (13.1)	5 (83.3)	1 (16.7)	
Present	33 (71.7)	28 (84.9)	5 (15.1)		PR	46			0.514
Multicentric	46			0.648	≥20	32 (69.6)	28 (87.5)	4 (12.5)	
Absent	25 (54.4)	23 (92)	2 (8)		<20	14 (30.4)	13 (92.8)	1 (7.2)	
Present	21 (45.6)	18 (85.7)	3 (14.3)		Ki67	36			0.826
Neoadjuvant Cht	46			0.979	≥20	14 (38.9)	13 (92.8)	1 (7.2)	
Yes	9 (19.5)	8 (88.8)	1 (11.2)		<20	22 (61.1)	18 (81.8)	4 (18.2)	
No	37 (80.5)	33 (89.2)	4 (10.8)		HER2	36			0.887
Tumor size	46			0.374	0	13 (36.2)	12 (92.3)	1 (7.7)	
≤2 cm	31 (67.4)	28 (90.3)	3 (9.7)		1+	12 (33.3)	11 (91.6)	1 (8.4)	
>2 cm	15 (32.6)	13 (86.7)	2 (13.3)		2+	5 (13.9)	4 (80)	1 (20)	
Tumor classification	46			0.365	3+	6 (16.6)	5 (8.3)	1 (16.7)	
Tis	10 (21.7)	9 (90)	1 (10)		BC subtype	36			0.786
T1	24 (52.2)	23 (95.8)	1 (4.2)		Lum A	17 (47.2)	15 (88.2)	2 (11.8)	
T2	9 (19.6)	6 (66.7)	3 (33.3)		Lum B–	10 (27.8)	9 (90)	1 (10)	
T3	3 (6.5)	3 (100)	0 (0)		Lum B+	4 (11.1)	4 (100)	0 (0)	
Nodal metastasis	46			0.612	HER2	3 (8.4)	2 (66.7)	1 (33.3)	
Negative	33 (71.7)	30 (90.9)	3 (9.1)		Basal	2 (5.5)	2 (100)	0 (0)	
Positive	13 (28.3)	11 (84.6)	2 (15.4)		BC profile	36			0.988
Lymph node status	46			0.335	Lum	31 (86.1)	28 (90.3)	3 (9.7)	
N0	33 (71.7)	30 (90.9)	3 (9.1)		Not Lum	5 (13.9)	4 (80)	1 (20)	
N1	9 (19.6)	8 (88.9)	1 (11.1)						
N2	3 (6.5)	2 (66.7)	1 (33.3)						
N3	1 (2.2)	1 (100)	0 (0)						

The 2 false negative SATs at the permanent section were: 1 case of high-grade DCIS and 1 cases of low-grade DCIS. The false-positive SATs were classified as low-grade DCIS, but at permanent section the specimen was negative.

Correlation between clinicopathological criteria and occult nipple involvement. In relation to the above findings, the bivariate analysis did not show a significant interaction between patient age, tumor size or type, lymph node status, lymphatic vascular invasion, histologic grade, ER, PR, Ki-67 status, HER2 amplification, multifocal or multicentric disease and positive NAC assessment ($p>0.05$). However, the frequency of nipple involvement at conclusive pathology tended to be slightly higher in younger patients (<50 years), extended tumors (>2 cm) with multifocality and increased histological grade (G3), associated *in situ* component or comedonecrosis and axillary nodal involvement, even if these data were not associated with a strong statistically relevant relationship ($p>0.05$). Furthermore, the mean tumor-to-nipple distance seen on mammography or magnetic resonance imaging was respectively closer (26.4 mm and 18.6 mm) for NAC positive compared to NAC negative tumors (30.4 mm and 27.6 mm), but with no significant difference ($p>0.05$). The median follow-up period was 18.6 months (range=6-36 months). At the time of analysis, no patient showed nipple areola recurrence, and one case of the 46 (2%) developed distant metastases with consequent death.

Discussion

In recent years, surgical techniques have evolved to less invasive and cosmetically acceptable approaches with

Table II. *Tumor characteristics associated with NAC involvement at post-operative final pathology.*

		Patient with occult nipple involvement										
	>50 years	Multifocal	Multicentric	pT stage	pT (cm)	pN Stage	*In situ* component	Grading	Ki67≥20	Her2 score	Subtype	SAB
Case 1	0	1	1	Tis	5	N0	0	G3	–	–	–	+
Case 2	0	1	1	T2	4	N0	1	G3	0	0	LumA	+
Case 3	0	1	0	T2	2	N2	1	G3	0	1	HER2	+
Case 4	1	1	1	T2	2	N1	1	G3	1	0	LumB-	–
Case 5	1	1	0	T1	1	N0	1	G2	0	0	LumA	–

SAB: Sub-areolar biopsy; +/–: positive/negative.

equivalent oncologic safety. In this context, nipple sparing mastectomy represents the latest tecnique in breast cancer management, popularized not only for prophylactic but also for therapeutic indications, with improved psycological and aesthetic outcomes (26, 27). Furthermore, even if traditionally, central tumors have been treated with a mastectomy for both oncological and cosmetic reasons, nowadays new established oncoplastic procedures and concepts have become ideal in the treatment of risk locations when the complexity of NAC preserving is required, if oncologically sound (28). Thus, since the areola complex is one the focal point of the breast, it is important to conduct an optimal preoperative patient selection in order to get a future long-term viability of the preserved nipple after both radical or conservative procedures. From available data, the accuracy of the intraoperative frozen section is similar to that of permanent histology in predicting NAC involvement, with a relatively low false-negative rate among studies between 6.8% and 11.8%, but also depending on institutional expertise and resources (14, 29). Moreover nipple-areaolar recurrence has been extremely low in some retrospective studies, ranging between 0 and 8.5%, potentially involving the ability of adjuvant treatments to eliminate potential residual disease or the chance that this not become manifest during the follow-up (30-31).

The overal incidence on NAC involvement in this study was only 10% (5/46) at permanent paraffin histology, concordant with previously reported rates of 3-25% and further supporting the concept that a majority of patients with breast cancer are appropriate candidates for nipple-sparing procedure (32, 33).

In order to facilitate surgical planning, other groups have explored the relationship of several preoperative radiological parameters with the likelihood of NAC involvement, but unfortunately clinical criteria, alone or in combination with mammography (MX) or ultrasound scan (US) are associated with variable or limited accuracy, and no added benefit to intra-operative histological assessment (34). In this regard, only data on the NAC evaluation by the MRI are the most accurate parameter to improve the sensitivity and specificity of pathological evaluation, according to several axial tumor-nipple distance cutoffs or local enhancement (35). Also, a study by Billar *et al.* supports the use of only 2 independent factors in the preoperative prediction of NAC involvement: the identification of clinical NAC abnormalities and the presence of abnormal imaging of the NAC, with a relatively high NPV of 92% or 89%, respectively, and the absence of these factors conveys a low probability of NAC disease (8). However, contrary to prior reports, no distinct cutoff value can be recommended as a safe tumor distance to allow for NAC preservation in our study, probably becouse this parameter was not recorded for many patients, which is indicative of the variability in radiology reporting (36, 37). Evaluation of a larger sample size may elicit further understanding of the TND predictive value maybe expanding the inclusion criteria for the conservative surgical management and providing valuable data about a controversial subject in the literature (38).

Thus, preoperative assessment of the NAC is important as it may help to select the best surgical strategy and inform the patients about the likelihood that it could be removed. Indeed, if the NAC is preserved, one-stage breast reconstruction with immediate placement of the prosthesis can be planned in selected cases, without compromising oncologic safety. Conversely, if the NAC has to be sacrificed, a two-stage reconstruction with the placement of a skin expander is generally preferable (39). Moreover, it is well known that exaustive preoperative information may significantly influence the choice of breast cancer patients on their favourite type of surgery and reduce their feelings of regret and dissatisfaction with the operation (40).

According to our experimental approach a preoperative sample of retroareolar tissue obtained by US-guided biopsy must be sent for evaluation before surgical treatment, in order to facilitate immediate breast reconstruction with implants or through volume displacement procedures, and achieve quality cosmetic outcome while providing high

patient satisfaction when oncologically safe. In the same way, relatively to new conservative perspectives for breast cancer, the possibility of characterizing the absence of residual pathological tissue (complete pathological response) after neaoadjuvant treatment by core needle biopsy before the planned surgical step was recently proposed as an experimental method for evaluation of new diagnostic and therapeutic purposes (41, 42). However, results are still conflicting with a variable range of false-negative rates and negative predictive values, implying that the method has yet to be standardized and refined.

Thus, we strongly believe that recognizing which patients are at high risk for pathologic NAC involvement is best done preoperatively for both surgical planning and patient education. In fact, a variety of factors have been associated with nipple involvement in patients with breast cancer, including larger tumor size, shorter tumor-to-nipple distance, central location, lymphovascular invasion, node metastases, advanced stage or grade, extensive *in situ* component, ER/PR-negative and HER2-positive status, but the majority of these parameters are primarily obtained after the surgery is completed (7, 43, 44). Moreover, due to the statistical heterogeneity detected with certain clinical criteria, there is still no consensus across the studies and the data are conflicting (45). The objective of this study is therefore to identify and evaluate a new preoperative approach that could be predictive of NAC involvement in patients undergoing treatment for breast cancer to better assist with operative planning.

Limitations of this study include the relatively small number of cases and moreover, it does not a dress the complexities of patient selection, which clearly involves many factors including both patient and physician concerns and biases. As such, our protocol should be considered exploratory in nature. Optimally, we would have had sufficient cases to evaluate the impact of different clinicopathological criteria in determining nipple involvement, but further studies with increased numbers and longer follow up may ascertain potential differences between these parameters, thus aiding in assessment for nipple sparing candidacy.

In summary, our study has shown that clinical criteria do not appear to contribute to the accuracy of preoperative biopsy results in the NAC assessment and considering their limited role to predict positive retro-areola margins, our experimental pre-operative approach may allow more patients to be considered for more conservative procedures with what is likely to be minimal risk.

Conflicts of Interest

The Authors have no conflicts of interest to declare in relation to this study.

Authors' Contributions

V.A., P.O. and A.G. performed the study, L.C., M.S R.C. and E.I. contributed to the collection of samples, analysis, and data management. E.I., G.G., F.P, C.A. and P.O contributed to the interpretation of data with generation of graphics and review of the article. P.O, A.G. and E.I. wrote and revised the manuscript. V.A provided supervised the retrospective evaluation of data. All Authors read and approved the manuscript.

Acknowledgements

Special thanks go to the dedicated specialists in the Breast Care Unit of Campus Bio-Medico University Hospital of Rome, Italy.

References

1 Rusby JE, Smith BL and Gui GP: Nipple-sparing mastectomy. Br J Surg *97(3)*: 305-316, 2010. PMID: 20101646. DOI: 10.1002/bjs.6970

2 Brachtel EF, Rusby JE, Michaelson JS, Chen LL, Muzikansky A, Smith BL and Koerner FC: Occult nipple involvement in breast cancer: clinicopathologic findings in 316 consecutive mastectomy specimens. J Clin Oncol *27(30)*: 4948-4954, 2009. PMID: 19720921. DOI: 10.1200/JCO.2008.20.8785

3 Chandarana MN, Jafferbhoy S, Marla S, Soumian S and Narayanan S: Acellular dermal matrix in implant-based immediate breast reconstructions: a comparison of prepectoral and subpectoral approach. Gland Surg *7(Suppl 1)*: S64-S69, 2018. PMID: 30175066. DOI: 10.21037/gs.2018.03.05

4 D'Alonzo M, Martincich L, Biglia N, Pisacane A, Maggiorotto F, Rosa GD, Montemurro F, Kubatzki F, Sismondi P and Ponzone R: Clinical and radiological predictors of nipple-areola complex involvement in breast cancer patients. Eur J Cancer *48(15)*: 2311-2318, 2012. PMID: 22647686. DOI: 10.1016/j.ejca.2012.04.017

5 Morimoto T, Komaki K, Inui K, Umemoto A, Yamamoto H, Harada K and Inoue K: Involvement of nipple and areola in early breast cancer. Cancer *55(10)*: 2459-2463, 1985. PMID: 2985236. DOI: 10.1002/1097-0142(19850515)55:10<2459::aid-cncr2820551025>3.0.co;2-l

6 Lüttges J, Kalbfleisch H and Prinz P: Nipple involvement and multicentricity in breast cancer. A study on whole organ sections. J Cancer Res Clin Oncol *113(5)*: 481-487, 1987. PMID: 3040768. DOI: 10.1007/BF00390043

7 Pirozzi PR, Rossetti C, Carelli I, Ruiz CA, Pompei LM and Piato S: Clinical and morphological factors predictive of occult involvement of the nipple-areola complex in mastectomy specimens. Eur J Obstet Gynecol Reprod Biol *148(2)*: 177-181, 2010. PMID: 19926200. DOI: 10.1016/j.ejogrb.2009.10.021

8 Billar JA, Dueck AC, Gray RJ, Wasif N and Pockaj BA: Preoperative predictors of nipple-areola complex involvement for patients undergoing mastectomy for breast cancer. Ann Surg Oncol *18(11)*: 3123-3128, 2011. PMID: 21861222. DOI: 10.1245/s10434-011-2008-5

9 Machida Y, Shimauchi A, Igarashi T, Hoshi K and Fukuma E: Preoperative breast MRI: reproducibility and significance of findings relevant to nipple-areolar complex involvement. Breast Cancer *25(4)*: 456-463, 2018. PMID: 29464515. DOI: 10.1007/s12282-018-0845-9

10 Crowe JP, Patrick RJ, Yetman RJ and Djohan R: Nipple-sparing mastectomy update: one hundred forty-nine procedures and clinical outcomes. Arch Surg *143(11)*: 1106-10; discussion 1110, 2008. PMID: 19015470. DOI: 10.1001/archsurg.143.11.1106

11 Benediktsson KP and Perbeck L: Survival in breast cancer after nipple-sparing subcutaneous mastectomy and immediate reconstruction with implants: a prospective trial with 13 years median follow-up in 216 patients. Eur J Surg Oncol *34(2)*: 143-148, 2008. PMID: 17709228. DOI: 10.1016/j.ejso.2007.06.010

12 Alperovich M, Choi M, Karp NS, Singh B, Ayo D, Frey JD, Roses DF, Schnabel FR, Axelrod DM, Shapiro RL and Guth AA: Nipple-sparing mastectomy and sub-areolar biopsy: To freeze or not to freeze? Evaluating the role of sub-areolar intraoperative frozen section. Breast J *22(1)*: 18-23, 2016. PMID: 26510917. DOI: 10.1111/tbj.12517

13 Kneubil MC, Lohsiriwat V, Curigliano G, Brollo J, Botteri E, Rotmensz N, Martella S, Mastropasqua MG, Iera M, Coelho MB, Intra M, Orecchia R, Rey P, Rietjens M and Petit JY: Risk of locoregional recurrence in patients with false-negative frozen section or close margins of retroareolar specimen in nipple-sparing mastectomy. Ann Surg Oncol *19(13)*: 4117-4123, 2012. PMID: 22820937. DOI: 10.1245/s10434-012-2514-0

14 Duarte GM, Tomazini MV, Oliveira A, Moreira L, Tocchet F, Worschech A and Torresan RZ: Accuracy of frozen section, imprint cytology, and permanent histology of sub-nipple tissue for predicting occult nipple involvement in patients with breast carcinoma. Breast Cancer Res Treat *153(3)*: 557-563, 2015. PMID: 26358710. DOI: 10.1007/s10549-015-3568-z

15 Morales Piato JR, Aguiar FN, Mota BS, Ricci MD, Dória MT, Alves-Jales RD, Messias AP, Filassi JR and Baracat EC: Improved frozen section examination of the retroareolar margin for prediction of nipple involvement in breast cancer. Eur J Surg Oncol *41(8)*: 986-990, 2015. PMID: 26002985. DOI: 10.1016/j.ejso.2015.04.019

16 Alperovich M, Reis SM, Choi M, Karp NS, Frey JD, Chang JB, Axelrod DM, Shapiro RL and Guth AA: Cost Analysis of Intraoperative Subareolar Frozen Section During Nipple-Sparing Mastectomy. Ann Surg Oncol *23(2)*: 490-493, 2016. PMID: 26438436. DOI: 10.1245/s10434-015-4882-8

17 Munch-Petersen HD, Rasmussen BB and Balslev E: Reliability of histological malignancy grade, ER and HER2 status on core needle biopsy *vs*. surgical specimen in breast cancer. APMIS *122(9)*: 750-754, 2014. PMID: 24372587. DOI: 10.1111/apm.12213

18 Meyer JE, Smith DN, Lester SC, Kaelin C, DiPiro PJ, Denison CM, Christian RL, Harvey SC, Selland DL and Durfee SM: Large-core needle biopsy of nonpalpable breast lesions. JAMA *281(17)*: 1638-1641, 1999. PMID: 10235159. DOI: 10.1001/jama.281.17.1638

19 Non-operative Diagnosis Subgroup of the National Coordinating Committee for Breast Screening Pathology: Guidelines for non-operative diagnostic procedures and reporting in breast cancer screening. Sheffield: National Health Service Breast Screening Programme, 2001.

20 Orsaria P, Grasso A, Carino R, Caredda E, Sammarra M, Altomare C, Rabitti C, Gullotta G, Perrone G, Pantano F, Buonomo OC and Altomare V: Heterogeneous risk profiles among B3 breast lesions of uncertain malignant potential. Tumori *106(2)*: 115-125, 2020. PMID: 31451072. DOI: 10.1177/0300891619868301

21 Ciatto S, Brancato B, Risso G, Ambrogetti D, Bulgaresi P, Maddau C, Turco P and Houssami N: Accuracy of fine needle aspiration cytology (FNAC) of axillary lymph nodes as a triage test in breast cancer staging. Breast Cancer Res Treat *103(1)*: 85-91, 2007. PMID: 17033920. DOI: 10.1007/s10549-006-9355-0

22 Orsaria P, Grasso A, Ippolito E, Pantano F, Sammarra M, Altomare C, Cagli B, Costa F, Perrone G, Soponaru G, Caggiati L, Vanni G, Buonomo OC and Altomare V: Clinical Outcomes Among Major Breast Cancer Subtypes After Neoadjuvant Chemotherapy: Impact on Breast Cancer Recurrence and Survival. Anticancer Res *41(5)*: 2697-2709, 2021. PMID: 33952501. DOI: 10.21873/anticanres.15051

23 Aryal KR, Lengyel AJ, Purser N, Harrison N, Aluwihare N and Isgar B: Nipple core biopsy for the deformed or scaling nipple. Breast *13(4)*: 350-352, 2004. PMID: 15325673. DOI: 10.1016/j.breast.2003.12.007

24 Amin MB, Edge S, Greene F, Byrd DR, Brookland RK, Washington MK, Gershenwald JE, Compton CC, Hess KR, Sullivan DC, Jessup JM, Brierley JD, Gaspar LE, Schilsky RL, Balch CM, Winchester DP, Asare EA, Madera M, Gress DM and Meyer LR: American Joint Committee on Cancer (AJCC). Cancer staging manual. Eighth edition. Springer, New York, 2017.

25 Goldhirsch A, Winer EP, Coates AS, Gelber RD, Piccart-Gebhart M, Thürlimann B, Senn HJ and Panel members: Personalizing the treatment of women with early breast cancer: highlights of the St Gallen International Expert Consensus on the Primary Therapy of Early Breast Cancer 2013. Ann Oncol *24(9)*: 2206-2223, 2013. PMID: 23917950. DOI: 10.1093/annonc/mdt303

26 Hartmann LC, Schaid DJ, Woods JE, Crotty TP, Myers JL, Arnold PG, Petty PM, Sellers TA, Johnson JL, McDonnell SK, Frost MH and Jenkins RB: Efficacy of bilateral prophylactic mastectomy in women with a family history of breast cancer. N Engl J Med *340(2)*: 77-84, 1999. PMID: 9887158. DOI: 10.1056/NEJM199901143400201

27 Kissin MW and Kark AE: Nipple preservation during mastectomy. Br J Surg *74(1)*: 58-61, 1987. PMID: 3828737. DOI: 10.1002/bjs.1800740118

28 Farouk O, Attia E, Roshdy S, Khater A, Senbe A, Fathi A, Hamed EE, Mesbah M, Shehatto F, El-Saed A and Denewer A: The outcome of oncoplastic techniques in defect reconstruction after resection of central breast tumors. World J Surg Oncol *13*: 285, 2015. PMID: 26409877. DOI: 10.1186/s12957-015-0688-1

29 Stolier A, Stone JC, Moroz K, Hanemann CW, McNabb L, Jones SD and Lacey M: A comparison of clinical and pathologic assessments for the prediction of occult nipple involvement in nipple-sparing mastectomies. Ann Surg Oncol *20(1)*: 128-132, 2013. PMID: 23010730. DOI: 10.1245/s10434-012-2511-3

30 Munhoz AM, Aldrighi CM, Montag E, Arruda EG, Aldrighi JM, Gemperli R, Filassi JR and Ferreira MC: Clinical outcomes following nipple-areola-sparing mastectomy with immediate implant-based breast reconstruction: a 12-year experience with an analysis of patient and breast-related factors for complications. Breast Cancer Res Treat *140(3)*: 545-555, 2013. PMID: 23897416. DOI: 10.1007/s10549-013-2634-7

31 Babiera G and Simmons R: Nipple-areolar complex-sparing mastectomy: feasibility, patient selection, and technique. Ann Surg Oncol *17 Suppl 3*: 245-248, 2010. PMID: 20853041. DOI: 10.1245/s10434-010-1256-0

32 Sikand K, Lee AH, Pinder SE, Elston CW and Ellis IO: Sections of the nipple and quadrants in mastectomy specimens for

carcinoma are of limited value. J Clin Pathol *58(5)*: 543-545, 2005. PMID: 15858129. DOI: 10.1136/jcp.2004.022665

33 Schecter AK, Freeman MB, Giri D, Sabo E and Weinzweig J: Applicability of the nipple-areola complex-sparing mastectomy: a prediction model using mammography to estimate risk of nipple-areola complex involvement in breast cancer patients. Ann Plast Surg *56(5)*: 498-504; discussion 504, 2006. PMID: 16641624. DOI: 10.1097/01.sap.0000216946.83252.e4

34 Ponzone R, Maggiorotto F, Carabalona S, Rivolin A, Pisacane A, Kubatzki F, Renditore S, Carlucci S, Sgandurra P, Marocco F, Magistris A, Regge D and Martincich L: MRI and intraoperative pathology to predict nipple-areola complex (NAC) involvement in patients undergoing NAC-sparing mastectomy. Eur J Cancer *51(14)*: 1882-1889, 2015. PMID: 26210374. DOI: 10.1016/j.ejca.2015.07.001

35 Moon JY, Chang YW, Lee EH and Seo DY: Malignant invasion of the nipple-areolar complex of the breast: usefulness of breast MRI. AJR Am J Roentgenol *201(2)*: 448-455, 2013. PMID: 23883228. DOI: 10.2214/AJR.12.9186

36 Vlajcic Z, Zic R, Stanec S, Lambasa S, Petrovecki M and Stanec Z: Nipple-areola complex preservation: predictive factors of neoplastic nipple-areola complex invasion. Ann Plast Surg *55(3)*: 240-244, 2005. PMID: 16106159. DOI: 10.1097/01.sap.0000171680.49971.85

37 Brachtel EF, Rusby JE, Michaelson JS, Chen LL, Muzikansky A, Smith BL and Koerner FC: Occult nipple involvement in breast cancer: clinicopathologic findings in 316 consecutive mastectomy specimens. J Clin Oncol *27(30)*: 4948-4954, 2009. PMID: 19720921. DOI: 10.1200/JCO.2008.20.8785

38 Dent BL, Miller JA, Eden DJ, Swistel A and Talmor M: Tumor-to-Nipple Distance as a Predictor of Nipple Involvement: Expanding the Inclusion Criteria for Nipple-Sparing Mastectomy. Plast Reconstr Surg *140(1)*: 1e-8e, 2017. PMID: 28654583. DOI: 10.1097/PRS.0000000000003414

39 Salzberg CA: Focus on technique: one-stage implant-based breast reconstruction. Plast Reconstr Surg *130(5 Suppl 2)*: 95S-103S, 2012. PMID: 23096993. DOI: 10.1097/PRS.0b013e318262e1a1

40 Whelan T, Levine M, Willan A, Gafni A, Sanders K, Mirsky D, Chambers S, O'Brien MA, Reid S and Dubois S: Effect of a decision aid on knowledge and treatment decision making for breast cancer surgery: a randomized trial. JAMA *292(4)*: 435-441, 2004. PMID: 15280341. DOI: 10.1001/jama.292.4.435

41 Heil J, Kümmel S, Schaefgen B, Paepke S, Thomssen C, Rauch G, Ataseven B, Große R, Dreesmann V, Kühn T, Loibl S, Blohmer JU and von Minckwitz G: Diagnosis of pathological complete response to neoadjuvant chemotherapy in breast cancer by minimal invasive biopsy techniques. Br J Cancer *113(11)*: 1565-1570, 2015. PMID: 26554654. DOI: 10.1038/bjc.2015.381

42 Kuerer HM, Rauch GM, Krishnamurthy S, Adrada BE, Caudle AS, DeSnyder SM, Black DM, Santiago L, Hobbs BP, Lucci A Jr, Gilcrease M, Hwang RF, Candelaria RP, Chavez-MacGregor M, Smith BD, Arribas E, Moseley T, Teshome M, Miggins MV, Valero V, Hunt KK and Yang WT: A Clinical Feasibility Trial for Identification of Exceptional Responders in Whom Breast Cancer Surgery Can Be Eliminated Following Neoadjuvant Systemic Therapy. Ann Surg *267(5)*: 946-951, 2018. PMID: 28549010. DOI: 10.1097/SLA.0000000000002313

43 Lambert PA, Kolm P and Perry RR: Parameters that predict nipple involvement in breast cancer. J Am Coll Surg *191(4)*: 354-359, 2000. PMID: 11030239. DOI: 10.1016/s1072-7515(00)00689-x

44 Laronga C, Kemp B, Johnston D, Robb GL and Singletary SE: The incidence of occult nipple-areola complex involvement in breast cancer patients receiving a skin-sparing mastectomy. Ann Surg Oncol *6(6)*: 609-613, 1999. PMID: 10493632. DOI: 10.1007/s10434-999-0609-z

45 Zhang H, Li Y, Moran MS, Haffty BG and Yang Q: Predictive factors of nipple involvement in breast cancer: a systematic review and meta-analysis. Breast Cancer Res Treat *151(2)*: 239-249, 2015. PMID: 25893590. DOI: 10.1007/s10549-015-3385-4

Received November 3, 2021
Revised December 17, 2021
Accepted December 20, 2021