

Expression and Prognostic Significance of CDK8 and β -Catenin in Hepatocellular Carcinoma

SONG IY HAN¹ and SUNG-CHUL LIM²

¹*Division of Premedical Science College of Medicine, Chosun University, Gwangju, Republic of Korea*

²*Department of Pathology, College of Medicine, Chosun University, Gwangju, Republic of Korea*

Abstract. *Background/Aim:* Cyclin-dependent kinase 8 (CDK8) is known to play an important role in the early development and progression of various cancers, and the Wnt/ β -catenin pathway is also involved in cancer progression. Nevertheless, relatively little is known about the regulatory mechanisms of the β -catenin pathway in hepatocellular carcinoma (HCC). *Materials and Methods:* The complete clinicopathological features of 122 pairs of HCC and adjacent non-tumor tissues were analyzed and immunohistochemistry was used to detect the aberrant expression of CDK8 and β -catenin. Overall survival rates (OSRs) were evaluated using the Kaplan-Meier method and Cox multivariate analysis was used to assess the prognostic values. *Results:* Aberrant expression of nuclear β -catenin and CDK8 are independent prognostic variables that negatively affect the OSR. The aberrant expression of CDK8 was associated with the dysregulated expression of β -catenin and correlated with a poor prognosis. *Conclusion:* Inhibition of CDK8 and/or nuclear β -catenin expression pattern could serve as a promising therapeutic strategy for the treatment of HCC.

Cyclin-dependent kinase 8 (CDK8), a member of CDK family of proteins, is a ubiquitously expressed transcription regulating serine/threonine kinase. CDK8 is located on chromosome 13 and has been implicated in transcriptional regulation of various cancers such as melanoma, colorectal, breast, prostate, and pancreatic cancer (1-5). The activation of CDK8 is essential for β -catenin-dependent transcription and oncogenesis (6, 7). Philip *et al.* (4) reported an important

role for CDK8 in gene-specific transcription either through its association with the mediator complex or by phosphorylation of transcription factors. These properties laid the foundation for the discovery of CDK8 inhibitors and for attempts to develop strategies for CDK8-targeted cancer therapies. The Wnt/ β -catenin, estrogen receptor-responsive genes, and drosophila mothers against decapentaplegic are CDK8-modulated transcriptional signaling pathways that have been implicated in the regulation of oncogenesis in various cancers (1, 4, 5, 8, 9).

β -catenin was originally reported as a membrane adhesion protein of the cadherin-mediated cell-cell adhesion system. It is the pivotal nuclear effector in the Wnt signal cascade (10). In the absence of Wnt signaling, β -catenin localizes to the cell membrane and functions in E-cadherin-mediated cell-cell adhesion. Aberrant degradation of β -catenin results in an increase of cytoplasmic β -catenin and leads to its nuclear translocation. Nuclear β -catenin is significantly associated with the invasion and metastasis of various human cancers such as carcinomas of the esophagus, stomach, colon, and melanomas (11, 12).

The suppression of CDK8 with a small-interfering RNA (siRNA) or short-hairpin RNA (shRNA) was shown to inhibit the proliferation of cancer cells of the colon, prostate, and breast based on preclinical data (1, 3, 5). Moreover, CDK8-mediated phosphorylation inhibits the cytotoxic activity of natural killer (NK) cells, however, CDK8 deletion in NK cells promotes their antitumor cytotoxicity (13, 14). These data suggest that the specific modulation of CDK8 could control its tumorigenic activity.

Primary hepatocellular carcinoma (HCC) is an aggressive tumor frequently associated with chronic viral hepatitis and subsequent liver cirrhosis. According to Globocan 2018 (International Agency for Research on Cancer, IARC), HCC is the most common primary cancer of the liver and the second leading cause of cancer-related death (14.6%) in the world (15). Treatment of HCC has improved considerably, but the overall survival (OS) remains unsatisfactory. The number of HCC and HCC-associated deaths has increased, especially in the developing countries over the past few

This article is freely accessible online.

Correspondence to: Sung-Chul Lim, MD, Ph.D. Department of Pathology Chosun University Hospital 365, Pilmoon-daero, Dong-gu, Gwangju, Republic of Korea. Tel: +82 622306343, Fax: +82 622265860, Mob: +82 1092676343, e-mail: sclim@chosun.ac.kr

Key words: Liver, hepatocellular carcinoma, CDK8, β -catenin, biomarkers.

Table I. Relationship between the expression of CDK8 or β -catenin and the clinicopathological parameters of hepatocellular carcinoma.

Clinicopathologic parameters	CDK8		<i>p</i> -Value	β-catenin N		<i>p</i> -Value	β-catenin M		<i>p</i> -Value	CDK8 & β-catenin N		<i>p</i> -Value	CDK8 & β-catenin M		<i>p</i> -Value
	–	+		–	+		NL	AB		OTH	AB		OTH	AB	
Tissue type															
HCC	62	60	<0.001	60	62	<0.001	55	67	<0.05	102	20	<0.005	88	34	<0.005
Adjacent liver	122	0		122	0		111	11		122	0		122	0	
Gender															
Male	52	48		50	50		45	55		84	16		72	28	
Female	10	12		10	12		9	13		18	4		16	6	
Tumor size (cm)															
≤5	58	26	<0.005	58	26	<0.001	48	36	<0.05	75	9	<0.05	66	18	<0.05
>5	4	34		2	36		7	31		27	11		22	16	
TNM stage															
I-II	51	19	<0.01	43	27	<0.05	45	25	<0.01	62	8	<0.05	55	15	<0.05
III-IV	11	41		17	35		10	42		40	12		33	19	
Differentiation [†]															
I-II	44	41		43	42		38	47		72	13		62	23	
III-IV	18	19		17	20		17	20		30	7		26	11	

NL: Normal expression, AB: aberrant expression, OTH: others, β -catenin N: nuclear β -catenin, β -catenin M: membranous β -catenin, HCC: hepatocellular carcinoma. Only significant *p*-values are shown. [†]Major differentiation by Edmondson grading system.

decades. An estimated 30,610 new liver cancer cases and 30,200 liver cancer deaths were reported in the United States in 2018 (16). Early-stage invasion is the main obstacle in improving patient survival. Early diagnosis and interventional treatments such as surgical resection, radiofrequency ablation (RFA), chemotherapy, radiotherapy, or transplantation are essential for the treatment of HCC (17). However, many patients do not have the opportunity to undergo early diagnosis and treatment.

Despite the remarkable developments in genomics and technology, the molecular mechanisms underlying the pathogenesis of HCC remain unclear. The diagnosis of HCC is often delayed due to poor prognostic factors, including drug resistance, metastasis, and tumor recurrence and these contribute to poor prognosis. Therefore, the discovery of promising biomarkers is warranted to improve prognosis and provide better personalized therapy.

Although the functions of CDK8 and β -catenin have been correlated with poor prognosis in a variety of cancers, the correlation between CDK8 and β -catenin expression, and the relevance of their co-expression to clinical parameters in HCC remain unclear. Thus, studies on CDK8 and β -catenin expression in human HCC tissues would provide an inspiration to tailor therapeutic modalities.

In the present study, we evaluated the expression of CDK8 and β -catenin immunohistochemically and analyzed the relevance to the clinicopathological parameters in 122 HCC tissues. Furthermore, the prognostic values of CDK8 and β -catenin in HCC were analyzed using the Kaplan-Meier and Cox regression analyses.

Materials and Methods

Case selection and tissue sampling. From the patients that underwent HCC operation at the Chosun University Hospital (Gwangju, Republic of Korea) between January 2003 and February 2019, 122 non-consecutive patients with complete medical records, and good clinical follow-up status were selected. A total of 122 pairs of HCC and adjacent non-tumor liver tissue blocks were selected for immunohistochemical staining. The cases were selected from the archives of the Pathology at the Chosun University Hospital. The final diagnosis of all HCC cases was histopathologically confirmed.

All of the clinicopathological parameters of the patients used in the present study were confirmed from the patient charts and pathology reports. The patients were followed-up by telephone calls and or medical insurance inquiry. The total follow-up was 5-122 months (median: 38.5 months). The endpoint was OS, defined as the time lapsing from the initial surgery until death or last follow-up. By July 2019, 91 patients had reached the end events. Patients that underwent preoperative therapy (chemotherapy, radiotherapy, transarterial embolization, or RFA) and emergency surgery were excluded from the study. The study was conducted in accordance with the Declaration of Helsinki.

Histopathological analysis

Microscopic examination. Every case was re-assessed by a retrospective analysis of the medical records and the pathology slide file. The gender, age, tumor size, TNM stage, and tumor differentiation (Edmondson-Steiner grade) (18) were assessed. The tumor stage was defined according to the TNM staging system of the American Joint Committee on Cancer (19).

The tissues were fixed with 10% neutral formalin, and the paraffin-embedded tissues were sectioned and stained with hematoxylin and eosin. The tissue slides were evaluated under a

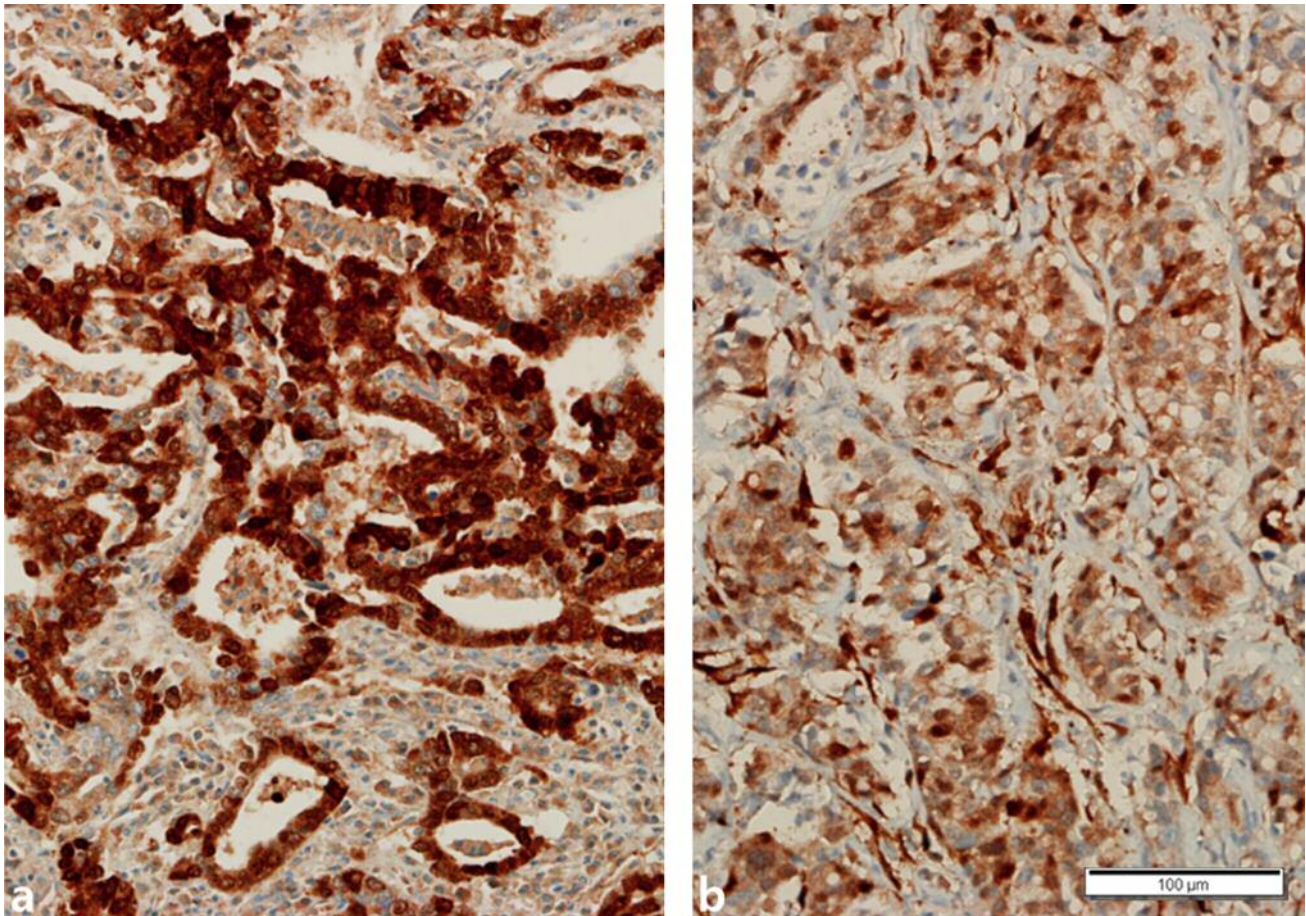


Figure 1. (A) Immunohistochemical staining of HCC for CDK8. Tumor cells showed diffuse strong positive nuclear staining. (B) Immunohistochemical staining of HCC for β -catenin. Tumor cells showed positive nuclear staining and some cytoplasmic staining.

light microscope, and representative areas suitable for the study purpose were selected. The slides were then prepared for immunohistochemical analysis.

Immunohistochemical staining. In brief, the 4- μ m thick tissue sections were prepared and immunohistochemical staining was performed using a BenchMark XT autostainer (Ventana Medical Systems, Tucson, AZ, USA). The primary antibodies used included mouse monoclonal CDK8 (Santa Cruz Biotechnology, Santa Cruz, CA, USA, 1:50 dilution) and mouse monoclonal β -catenin (1:200 dilution, Santa Cruz Biotechnology). Counterstaining was performed with Mayer's hematoxylin. Tris-buffered saline was used as the negative control, instead of the primary antibody.

Analysis and interpretation of staining. Brown nuclear staining for CDK8 was considered as positive expression. The intensity for positive staining was scored as 0 (no staining), 1 (weak staining), 2 (moderate staining), and 3 (strong staining). The percentage of positive staining was decided on a scale of 0 to 5 as follows: 0 (<10%); 1 (10% to 25%); 2 (26% to 50%); 3 (51% to 75%); and 4

(>75%). The final score was the sum of the intensity and the percentage scores. Final score ≥ 5 was considered as aberrant (positive) expression for statistical reasons.

β -catenin showed both nuclear and membranous staining patterns. Hence, the nuclear and membranous β -catenin staining patterns were evaluated independently. Nuclear staining of more than 5% was considered as aberrant nuclear expression. A staining pattern that was stronger than the membranous staining of the normal hepatocytes and/or diffuse cytoplasmic staining were considered as aberrant membranous expression. The percentage of positive staining was calculated from an average of 100 tumor cells counted in more than five high-power fields ($\times 400$).

Statistical analysis. The SPSS software (SPSS version 24.0 SPSS, Inc., Chicago, IL, USA) was used for the statistical analysis. We used the χ^2 test, *t*-test, and Spearman's rank test to determine the correlation between the clinicopathological parameters and expression patterns of CDK8 and β -catenin. The log-rank test was used for the Kaplan-Meier survival analysis. The 95% confidence interval (CI) was evaluated for each variable using the Cox multivariate model. Statistical significance was determined at $p < 0.05$.

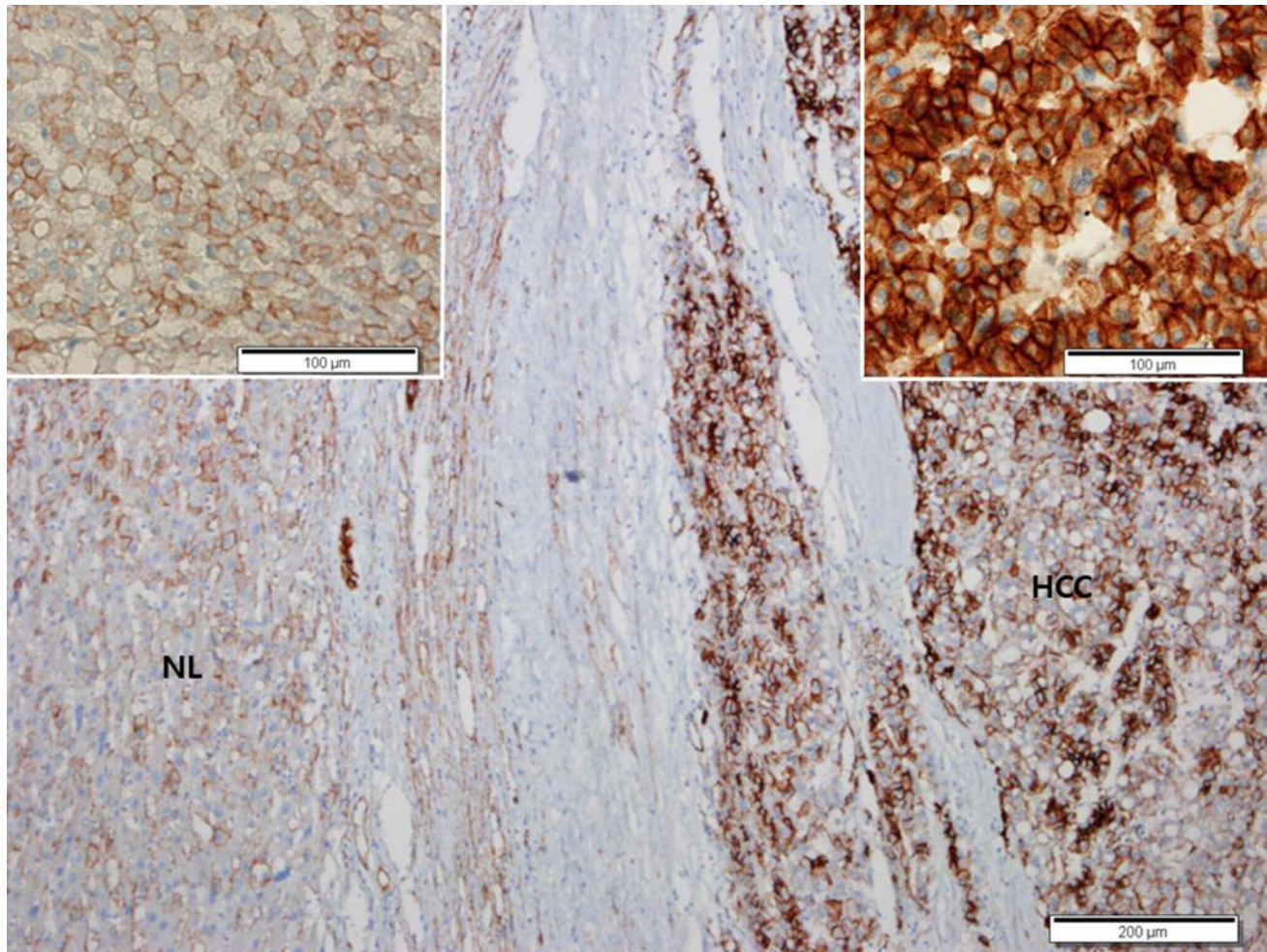


Figure 2. (A) Immunohistochemical staining of HCC for β -catenin. Tumor cells showed strong positive membranous staining and diffuse cytoplasmic staining, but the adjacent normal liver (NL) showed weak membranous staining. Insets showed the higher magnification of the normal liver (left) and HCC (right).

Results

Clinicopathological findings. The patients comprised of 100 males and 22 females, all in the age range of 31-83 years (males: 31-83 years, mean: 61.0 years; females: 33-75 years, mean: 58.6 years).

Clinicopathological significance of CDK8 and β -catenin (Table I). Immunoreactivity of CDK8 and β -catenin in HCCs and adjacent liver tissues. Sixty cases (49%) of HCC showed positive CDK8 expression in the nucleus (Figure 1a). However, we failed to observe any CDK8 expression in the adjacent liver tissues ($p < 0.001$). A significant number of HCC cases (51%) showed nuclear β -catenin staining (Figure 1b), while CDK8 and nuclear β -catenin staining was undetected in the adjacent liver tissues ($p < 0.001$). Aberrant membranous

expression of β -catenin was detected in 55% of HCCs (Figure 2) and some adjacent liver tissues (9%, $p < 0.05$).

The positive expression of CDK8 directly correlated with the aberrant nuclear β -catenin ($p < 0.005$) and membranous β -catenin ($p < 0.05$) expression in HCCs (Table II). We failed to observe any difference between genders with respect to the aberrant expression of CDK8 and β -catenin.

Interrelation between CDK8 and tumor size. The aberrant expression of CDK8 ($p < 0.005$), nuclear β -catenin ($p < 0.001$), and membranous β -catenin ($p < 0.05$) was significantly higher in tumors larger than 5 cm in diameter than in the smaller tumors.

Interrelation between CDK8 and TNM stage. The aberrant expression of CDK8 ($p < 0.01$), nuclear β -catenin ($p < 0.05$), and membranous β -catenin ($p < 0.05$) increased significantly

in the late stages (stages III-IV) compared to early stages (stages I-II).

Interrelation between CDK8 expression and tumor differentiation. The aberrant expression of CDK8, nuclear β -catenin, and membranous β -catenin showed no statistically significant difference between high- (grades III-IV) and low-grade tumors (grades I-II).

Overall survival analysis with CDK8 and β -catenin expression. We analyzed the HCC cases with Kaplan-Meier curves (Figure 3) and found that the aberrant expression of nuclear β -catenin, membranous β -catenin, and CDK8/membranous β -catenin significantly affected the overall survival rate (OSR) of patients with HCC ($p < 0.05$ for all). However, the aberrant expression of CDK8 and CDK8/nuclear β -catenin had no significant effect on the OSR ($p > 0.05$ for all). Further, patients with aberrant expression of both CDK8 and β -catenin (nuclear and membranous) exhibited the worst OSR. On the contrary, those with normal CDK8 and β -catenin expression demonstrated the best OSR ($p < 0.05$ for all). Multivariate analysis revealed aberrant expression of nuclear β -catenin [95% confidence interval (CI)=1.029-4.496, $p=0.042$] and CDK8 (95% CI=1.111-2.720, $p=0.015$) as independent negative prognostic variables affecting the OSR.

Discussion

Aberrant expression of both CDK8 and β -catenin is known to correlate with tumor invasion, metastasis, and poor prognosis in humans (11, 12, 20, 21). However, little is known about the regulatory mechanism of CDK8 expression by β -catenin and the interrelation of their expression to the clinicopathological parameters in HCC.

In the present study, we examined the expression of CDK8 and β -catenin in 122 HCC specimens using immunohistochemical staining, and compared the levels to that in the adjacent non-neoplastic liver tissues. HCC tissues showed aberrant expression of CDK8 (49%), nuclear β -catenin (51%), and membranous β -catenin (55%). On the contrary, the adjacent non-cancerous liver tissues had no aberrant expression of CDK8 or nuclear β -catenin. Although aberrant expression of membranous β -catenin was detected in some adjacent liver tissues (9%). We found that the aberrant expression of CDK8 was significant in HCC, suggestive of its valuable role in the diagnosis of HCC. High CDK8 expression may be associated with the occurrence, development, and prognosis of HCC, and play a significant clinical role in HCC pathogenesis. Evaluation of the relationship between CDK8 and the clinicopathological parameters showed that aberrant expression of CDK8 was related to HCC tumor stage. Tumors larger than 5 cm in diameter showed a significant increase in the aberrant

Table II. Relationship between the expression of CDK8 and β -catenin in hepatocellular carcinoma.

CDK8	β -catenin N		β -catenin M	
	–	+	NL	AB
Negative	20	42	29	33
Positive	40	20	26	34
<i>p</i> -Value	<0.005		<0.05	

NL: Normal expression, AB: aberrant expression, β -catenin N: nuclear β -catenin, β -catenin M: membranous β -catenin.

expression of CDK8, nuclear β -catenin, and membranous β -catenin compared to the smaller tumors. The aberrant expression of CDK8, nuclear β -catenin, and membranous β -catenin increased significantly in late-stage tumors (stages III-IV) as compared to early-stage tumors (stages I-II).

The results of the survival analysis revealed the absence of any correlation between aberrant expression of CDK8 and OSR of patients with HCC. Thus, the aberrant expression of CDK8 may play an important role in the oncogenesis and early progression of HCC. Aberrant expression of CDK8 directly correlated with the dysregulated expression of nuclear and membranous β -catenin in HCC, consistent with the results of previous studies (22-24).

Around 40-70% HCCs showed aberrant expression of nuclear β -catenin, thereby accentuating Wnt/ β -catenin signaling activity (25-28). Key mutations are involved in this process (29-31). In the early stages, β -catenin is primarily located at the cell membrane, in the form of a complex with cadherin, whereby it induces tumor cell survival by augmenting the growth factor receptor signaling molecules, such as epidermal growth factor receptor (EGFR). However, aberrant nuclear β -catenin was recently reported to be limited to late-stage HCC (32).

In addition, increased β -catenin immunohistochemical expression in HCC patients treated with transcatheter arterial chemoembolization (TACE) has been reported to have a poor prognosis with a lower survival rate (33).

In the present study, we revealed an unexpected function of β -catenin in the early stages of HCC and suggest some role for β -catenin during HCC progression. Furthermore, the aberrant expression of nuclear β -catenin and CDK8 served as independent negative prognostic variables influencing OSR. The Kaplan-Meier survival analysis revealed worse OSR for patients with aberrant expression of CDK8 or β -catenin (nuclear or membranous) than for those with normal CDK8 or β -catenin expression. Moreover, those with aberrant expression of both CDK8 and β -catenin (nuclear and membranous) exhibited the worst OSR. On the contrary, patients with normal CDK8 and β -catenin levels showed the

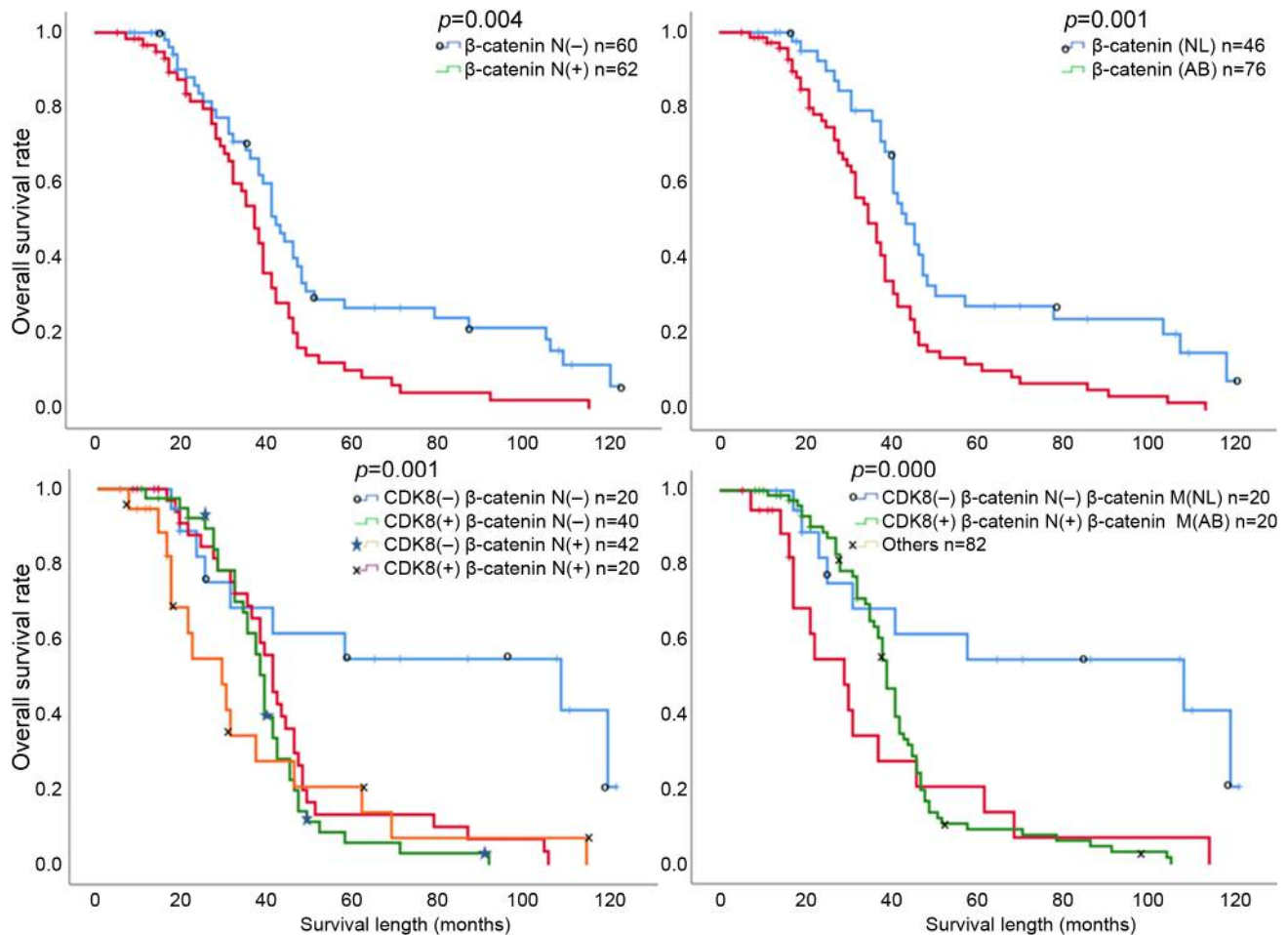


Figure 3. Kaplan-Meier analysis of overall survival rates in 122 HCC patients. β -catenin N, Nuclear expression of β -catenin; NL, normal expression; AB, aberrant expression; OTH, others.

best survival. These results indicate that the combination of CDK8 and β -catenin could predict worse survival and may use as the important molecular prognostic indicators of survival in patients with HCC.

Thus, the aberrant expression of CDK8 and β -catenin, especially nuclear β -catenin, correlated with tumorigenesis, tumor progression, and poor prognosis. These findings suggest that CDK8 may play an important role by suppressing the degradation of β -catenin and promoting its entry into the nucleus. The aberrant expression of CDK8 or β -catenin in tumor cells facilitates tumor cell migration and metastasis. The present study suggests the role of CDK8 and β -catenin as promising diagnostic biomarkers and prognostic indicators of survival in patients with HCC.

The results described herein improve our understanding of the biological functions of CDK8 and β -catenin in HCC. The regulatory role of CDK8 on β -catenin expression highlights

a new molecular mechanism underlying CDK8-mediated initiation and progression of HCC, and suggests a novel therapeutic strategy to inhibit HCC metastasis through the targeting of CDK8 and β -catenin.

Conflicts of Interest

The Authors declare no conflicts of interest.

Author's Contributions

S. C. Lim designed research and wrote the paper; S. I. Han performed research and analyzed data; S. C. Lim contributed funding acquisition.

Acknowledgements

This work was supported by research fund from Chosun University Hospital Clinical Medicine Research Institute, 2016.

References

- McDermott MS, Chumanevich AA, Lim CU, Liang J, Chen M, Altília S, Oliver D, Rae JM, Shtutman M, Kiaris H, Györfy B, Roninson IB and Broude EV: Inhibition of CDK8 mediator kinase suppresses estrogen dependent transcription and the growth of estrogen receptor positive breast cancer. *Oncotarget* 21(8): 12558-12575, 2017. PMID: 28147342. DOI: 10.18632/oncotarget.14894
- Kapoor A, Goldberg MS, Cumberland LK, Ratnakumar K, Segura MF, Emanuel PO, Menendez S, Vardabasso C, Leroy G, Vidal CI, Polsky D, Osman I, Garcia BA, Hernando E and Bernstein E: The histone variant macroH2A suppresses melanoma progression through regulation of CDK8. *Nature* 23(468): 1105-1109, 2010. PMID: 21179167. DOI: 10.1038/nature09590
- Brägelmann J, Klümper N, Offermann A, von Mässenhausen A, Böhm D, Deng M, Queisser A, Sanders C, Syring I, Merseburger AS, Vogel W, Sievers E, Vlasic I, Carlsson J, Andrén O, Brossart P, Duensing S, Svensson MA, Shaikhibrahim Z, Kirfel J and Perner S: Pan-cancer analysis of the mediator complex transcriptome identifies CDK19 and CDK8 as therapeutic targets in advanced prostate cancer. *Clin Cancer Res* 1(23): 1829-1840, 2017. PMID: 27678455. DOI: 10.1158/1078-0432.CCR-16-0094
- Philip S, Kumarasiri M, Teo T, Yu M and Wang S: Cyclin-dependent kinase 8: a new hope in targeted cancer therapy? *J Med Chem* 61(12): 5073-5092, 2018. PMID: 29266937. DOI: 10.1021/acs.jmedchem.7b00901
- Firestein R, Bass AJ, Kim SY, Dunn IF, Silver SJ, Guney I, Freed E, Ligon AH, Vena N, Ogino S, Chheda MG, Tamayo P, Finn S, Shrestha Y, Boehm JS, Jain S, Bojarski E, Mermel C, Barretina J, Chan JA, Baselga J, Tabernero J, Root DE, Fuchs CS, Loda M, Shivdasani RA, Meyerson M and Hahn WC: CDK8 is a colorectal cancer oncogene that regulates beta-catenin activity. *Nature* 455(7212): 547-451, 2008. PMID: 18794900. DOI: 10.1038/nature07179
- Kim S, Xu X, Hecht A and Boyer TG: Mediator is a transducer of Wnt/beta-catenin signaling. *J Biol Chem* 281(20): 14066-14075, 2006. PMID: 16565090. DOI: 10.1074/jbc.M602696200
- Morris EJ, Ji JY, Yang F, Di Stefano L, Herr A, Moon NS, Kwon EJ, Haigis KM, Naar AM and Dyson NJ: E2F1 represses beta-catenin transcription and is antagonized by both pRB and CDK8. *Nature* 455(7212): 552-556, 2008. PMID: 18794899. DOI: 10.1038/nature07310
- Alarcón C, Zaromytidou AI, Xi Q, Gao S, Yu J, Fujisawa S, Barlas A, Miller AN, Manova-Todorova K, Macias MJ, Sapkota G, Pan D and Massagué J: Nuclear CDKs drive Smad transcriptional activation and turnover in BMP and TGF-beta pathways. *Cell* 139(4): 757-769, 2009. PMID: 19914168. DOI: 10.1016/j.cell.2009.09.035
- Xu W, Wang Z, Zhang W, Qian K, Li H, Kong D, Li Y and Tang Y: Mutated K-ras activates CDK8 to stimulate the epithelial-to-mesenchymal transition in pancreatic cancer in part via the Wnt/ β -catenin signaling pathway. *Cancer Lett* 356(2): 613-27, 2015. PMID: 25305448. DOI: 10.1016/j.canlet.2014.10.008
- McCrea PD and Gumbiner BM: Purification of a 92-kDa cytoplasmic protein tightly associated with the cell-cell adhesion molecule E-cadherin (uvomorulin). Characterization and extractability of the protein complex from the cell cytostructure. *J Biol Chem* 266(7): 4514-4520, 1991. PMID: 1999432.
- Osterheld MC, Bian YS, Bosman FT, Benhattar J and Fontollet C: Beta-catenin expression and its association with prognostic factors in adenocarcinoma developed in Barrett esophagus. *Am J Clin Pathol* 117(3): 451-456, 2002. PMID: 11888085. DOI: 10.1309/1db6-gfvh-ra6w-q07y
- Kim HS, Hong EK, Park SY, Kim WH and Lee HS: Expression of beta-catenin and E-cadherin in the adenoma-carcinoma sequence of the stomach. *Anticancer Res* 23(3C): 2863-2868, 2003. PMID: 12926124.
- Putz EM, Gotthardt D, Hoermann G, Csiszar A, Wirth S, Berger A, Straka E, Rigler D, Wallner B, Jamieson AM, Pickl WF, Zebelin-Brandl EM, Müller M, Decker T and Sexl V: CDK8-mediated STAT1-S727 phosphorylation restrains NK cell cytotoxicity and tumor surveillance. *Cell Rep* 4(3): 437-444, 2013. PMID: 23933255. DOI: 10.1016/j.celrep.2013.07.012
- Witalisz-Siepracka A, Gotthardt D, Prchal-Murphy M, Didara Z, Menzl I, Prinz D, Edlinger L, Putz EM and Sexl V: NK Cell-Specific CDK8 Deletion enhances antitumor responses. *Cancer Immunol Res* 6(4): 458-466, 2018. PMID: 29386186. DOI: 10.1158/2326-6066.CIR-17-0183
- The Union for International Cancer Control (UICC). 2018 GLOBOCAN annual report. Available at: www.uicc.org/2018-annual-report
- Siegel RL, Miller KD and Jemal A: Cancer statistics, 2017. *CA Cancer J Clin* 67(1): 7-30, 2017. PMID: 28055103. DOI: 10.3322/caac.21387
- Shields A and Reddy KR: Hepatocellular carcinoma: current treatment strategies. *Curr Treat Options Gastroenterol* 8(6): 457-466, 2005. PMID: 16313863. DOI: 10.1007/s11938-005-0032-x
- Edmondson HA and Steiner PE: Primary carcinoma of the liver: a study of 100 cases among 48,900 necropsies. *Cancer* 7(3): 462-503, 1954. PMID: 13160935. DOI: 10.1002/1097-0142(195405)7:3<462::aid-cnrcr2820070308>3.0.co;2-e
- Amin MB: AJCC cancer staging manual, 8th ed. New York: Springer, 2016.
- Rubinfeld B, Robbins P, El-Gamil M, Albert I, Porfiri E and Polakis P: Stabilization of beta-catenin by genetic defects in melanoma cell lines. *Science* 275(5307): 1790-1792, 1997. PMID: 9065403. DOI: 10.1126/science.275.5307.1790
- Wang L, Shi S, Guo Z, Zhang X, Han S, Yang A, Wen W and Zhu Q: Overexpression of YAP and TAZ is an independent predictor of prognosis in colorectal cancer and related to the proliferation and metastasis of colon cancer cells. *PLoS One* 8(6): e65539, 2013. PMID: 23762387. DOI: 10.1371/journal.pone.0065539
- Imajo M, Miyatake K, Iimura A, Miyamoto A and Nishida E: A molecular mechanism that links Hippo signalling to the inhibition of Wnt/ β -catenin signalling. *EMBO J* 31(5): 1109-1122, 2012. PMID: 22234184. DOI: 10.1038/emboj.2011.487
- Azzolin L, Zanconato F, Bresolin S, Forcato M, Basso G, Bicciato S, Cordenonsi M and Piccolo S: Role of TAZ as mediator of Wnt signaling. *Cell* 151(7): 1443-1456, 2012. PMID: 23245942. DOI: 10.1016/j.cell.2012.11.027
- Tsai BP, Hoverter NP and Waterman ML: Blending hippo and WNT: sharing messengers and regulation. *Cell* 151: 1401-1403, 2012. PMID: 23245942. DOI: 10.1016/j.cell.2012.11.027
- Lachenmayer A, Alsinet C, Savic R, Cabellos L, Toffanin S, Hoshida Y, Villanueva A, Minguez B, Newell P, Tsai HW, Barretina J, Thung S, Ward SC, Bruix J, Mazzaferro V, Schwartz M, Friedman SL and Llovet JM: Wnt-pathway activation in two molecular classes of hepatocellular carcinoma and experimental

- modulation by sorafenib. *Clin Cancer Res* 18(18): 4997-5007, 2012. PMID: 22811581. DOI: 10.1158/1078-0432.CCR-11-2322
- 26 Nhieu JT, Renard CA, Wei Y, Cherqui D, Zafrani ES and Buendia MA: Nuclear accumulation of mutated beta-catenin in hepatocellular carcinoma is associated with increased cell proliferation. *Am J Pathol* 155(3): 703-710, 1999. PMID: 10487827. DOI: 10.1016/s0002-9440(10)65168-1
- 27 Lin YT and Chao CC: Identification of the beta-catenin/JNK/prothymosin-alpha axis as a novel target of sorafenib in hepatocellular carcinoma cells. *Oncotarget* 6(36): 38999-39017, 2015. PMID: 26517516. DOI: 10.18632/oncotarget.5738
- 28 Wong CM, Fan ST and Ng IO: beta-Catenin mutation and overexpression in hepatocellular carcinoma: Clinicopathologic and prognostic significance. *Cancer* 92(1): 136-145, 2001. PMID: 11443619. DOI: 10.1002/1097-0142(20010701)92:1<136::aid-cnrcr1301>3.0.co;2-r
- 29 Monga SP: beta-Catenin signaling and roles in liver homeostasis, injury, and tumorigenesis. *Gastroenterology* 148(7): 1294-1310, 2015. PMID: 25747274. DOI: 10.1053/j.gastro.2015.02.056
- 30 Laurent-Puig P and Zucman-Rossi J: Genetics of hepatocellular tumors. *Oncogene* 25(27): 3778-3786, 2006. PMID: 16799619. DOI: 10.1038/sj.onc.1209547
- 31 Fujimoto A, Totoki Y, Abe T, Boroevich KA, Hosoda F, Nguyen HH, Aoki M, Hosono N, Kubo M, Miya F, Miya F, Arai Y, Takahashi H, Shirakihara T, Nagasaki M, Shibuya T, Nakano K, Watanabe-Makino K, Tanaka H, Nakamura H, Kusuda J, Ojima H, Shimada K, Okusaka T, Ueno M, Shigekawa Y, Kawakami Y, Arihiro K, Ohdan H, Gotoh K, Ishikawa O, Ariizumi S, Yamamoto M, Yamada T, Chayama K, Kosuge T, Yamaue H, Kamatani N, Miyano S, Nakagama H, Nakamura Y, Tsunoda T, Shibata T and Nakagawa H: Whole-genome sequencing of liver cancers identifies etiological influences on mutation patterns and recurrent mutations in chromatin regulators. *Nat Genet* 44(7): 760-764, 2012. PMID: 22634756. DOI: 10.1038/ng.2291 DOI: 10.1038/ng.2291
- 32 Kim E, Lisby A, Ma C, Lo N, Ehmer U, Hayer KE, Furth EE and Viator P: Promotion of growth factor signaling as a critical function of beta-catenin during HCC progression. *Nat Commun* 10(1): 1909, 2019. PMID: 31015417. DOI: 10.1038/s41467-019-09780-z
- 33 Xu X, Gao D, Yuan X, Liu LI, Zhang X, Liang X, Chen S, Ai M, Chen BO, Shi D, Yang Z, Hoffman RM and Xu J: β -Catenin expression correlates with prognosis in hepatocellular carcinoma patients treated with transcatheter arterial chemoembolization. *Anticancer Res* 39(3): 1129-1134, 2019. PMID: 30842141. DOI: 10.21873/anticancer.13221

Received February 28, 2020

Revised March 12, 2020

Accepted March 16, 2020