

Primary Gastric EBV-positive Diffuse Large B Cell Lymphoma (DLBCL) of the Elderly with Plasmablastic Differentiation

MING HU¹, JOSE TREVINO², LIJUN YANG¹, DENG FENG CAO³, XIULI LIU¹ and JINPING LAI¹

¹Department of Pathology, Immunology, and Laboratory Medicine,
University of Florida College of Medicine, Gainesville, FL, U.S.A.;

²Department of Surgery, University of Florida College of Medicine, Gainesville, FL, U.S.A.;

³Department of Pathology, Immunology, and Laboratory Medicine,
Washington University in Saint Louis, St. Louis, MO, U.S.A.

Abstract. Epstein–Barr virus (EBV)-positive diffuse large B cell lymphoma (DLBCL) of the elderly is a rare subtype of B-cell neoplasms. Primary gastric EBV-positive DLBCL of the elderly with partial plasmablastic phenotype is extremely rare. Differentiation of EBV-positive DLBCL of the elderly with partial plasmablastic phenotype from true plasmablastic lymphoma (PBL) is difficult and very important from the therapeutic and prognostic point of view. Here we report a case of a 59-year-old man with upper gastrointestinal bleeding. The esophagogastroduodenoscopy revealed a 2-cm malignant-appearing non-bleeding gastric ulcer in the gastric cardia. Biopsy showed ulcerated tissue with atypical lymphoid cell infiltrate, morphologically consistent with immunoblasts. The atypical large cells were positive for CD20, PAX5, MUM-1, and a subset of large cells was positive for CD30, BCL6 and CD138. Ki-67 proliferation index exceeded 90% of the tumor cells. *In situ* hybridization (ISH) for EBV-encoded RNAs (EBERs) was extensively positive. Kappa/Lambda ISH showed lambda restriction. The final diagnosis was primary gastric EBV-positive DLBCL of the elderly with plasmablastic phenotype. The patient finished 5 cycles of R-DA-EPOCH with significant clinical improvement. To the best of our knowledge, this is an

extremely rare case of primary gastric EBV-positive DLBCL of the elderly with plasmablastic phenotype.

Epstein-Barr virus (EBV)-positive diffuse large B-cell lymphoma (DLBCL) of the elderly was first recognized as a new provisional entity by the 2008 World Health Organization (WHO) classification of tumors of hematopoietic and lymphoid tissues (1). It's now changed to EBV+ DLBCL, NOS in the WHO classification 2016 (2). This tumor is defined as an EBV-positive monoclonal large B-cell lymphoproliferative disorder arising in immunocompetent patients older than age 50 years, in whom there is no known immunodeficiency or history of lymphoma.

EBV-positive DLBCL of the elderly is characterized by higher age distribution and an aggressive clinical course with a median survival of 2 years in Asian patients. The sites of primary extranodal involvement include the skin, soft tissue, bones, nasal cavity, pharynx/hypopharynx, tonsils, tongue, lung, pleura, stomach, liver, spleen, peritoneum, cecum, and bone marrow. The neoplastic cells are of B-cell lineage, they express the pan B-cell antigens CD20 and PAX5. Plasmacytoid (or plasmablastic) cases can be CD20 weakly positive or negative, usually has an activated B-cell (ABC) immunophenotype being MUM1 positive and CD10 negative and usually BCL-6 negative. BCL-2 and CD30 are usually positive, while CD15 is negative. Ki-67 generally shows a high proliferation index. Immunoglobulin light chain restriction may be difficult to demonstrate by conventional flow cytometric analysis due to lack of surface expression of immunoglobulin light chains, except in cases with immunoblastic or plasmablastic features in which cytoplasmic immunoglobulin light chain mRNA and protein can be assessed by cytoplasmic flow cytometry or by kappa/Lambda *in situ* hybridization (ISH). We report a unique primary gastric EBV-positive DLBCL of the elderly with CD138 and MUM1 positive and strong immunoglobulin lambda light chain

This article is freely accessible online.

Correspondence to: Dr. Jinping Lai, Department of Pathology, Immunology, and Laboratory Medicine, University of Florida College of Medicine, Gainesville, FL 32610, U.S.A. Tel: +1 3526279240, Fax: +1 3526279242, e-mail: jinpinglai@ufl.edu; Dr. Jose Trevino, Department of Surgery, University of Florida College of Medicine Gainesville, FL 32610, U.S.A. Tel: +1 3525949572, e-mail: jose.trevino@surgery.ufl.edu

Key Words: Stomach, diffuse large B cell Lymphoma, plasmablastic lymphoma, immunohistochemistry, *in situ* hybridization.

mRNA signal, consistent with plasmacytic differentiation. To the best of our knowledge, this is an extremely rare case of primary gastric EBV-positive DLBCL of the elderly with partial plasmablastic phenotype.

Case Presentation

We received consultation service request from an outside patient's doctor. A 59-year-old male patient with upper gastrointestinal bleeding was found to have a 2cm ulcer at the gastric cardia on esophagogastroduodenoscopy (EGD). Follow-up EGD one month later showed a 2 cm malignant-appearing non-bleeding gastric ulcer in the gastric cardia with no stigmata of bleeding (Figure 1 left). Biopsy was performed at the periphery and base of the ulcer.

Histologically, the H&E sections of the gastric biopsies showed several fragments of gastric epithelium and ulcerated tissue with atypical lymphocytic infiltrates and necrosis. The atypical infiltrating cells were medium to large in size, with open chromatin, single prominent nucleolus, and abundant cytoplasm, morphologically consistent with immunoblasts. Scattered abnormal mitoses were also present. Admixed with these large atypical cells were scattered small lymphocytes, neutrophils and histiocytes (Figure 1 mid and right).

Immunohistochemical studies showed that the atypical large cells were positive for CD20, PAX5, MUM-1, and a subset of large cells positive for CD30, BCL6 and CD138 (Figure 2). The Ki-67 proliferation index was >90%. ISH for EBER revealed extensive positivity in neoplastic cells. Kappa/Lambda ISH showed neoplastic cells being lambda restricted with a strong lambda mRNA signal, consistent with plasmacytic differentiation (Figure 2). The tumor cells were negative for CD15, CD3, CD10, S-100, Cyclin D-1, CD5, CD43, CD4, CD8, Alk-1, and AE1/AE3. Helicobacter Pylori immunostaining was negative. A marked increase in the CD4/CD8 ratio was noted by CD4/CD8 immunohistochemistry (IHC). Based on the immunoblastic morphology, findings of IHC and ISH, high proliferation index, and extranodal site (stomach), we established the diagnosis of EBV positive DLBCL of the elderly with plasmablastic phenotype.

After the diagnosis, the patient was admitted in our hospital and a CT scan showed extensive bulky bilateral axillary, mediastinal and hilar adenopathy along with enlarged retroperitoneal lymph nodes. A left renal mass was noted on ultrasound during his first evaluation of gastrointestinal bleeding. Magnetic Resonance Imaging (MRI) showed that the renal mass was atypical for lymphoma and appeared more consistent with renal cell carcinoma, thereby, the medical team including the patient's urologist agreed to treat lymphoma first, since the patient was not a good candidate for surgery at that time.

The patient received R-EPOCH (etoposide + prednisone + Vincristine + cyclophosphamide + doxorubicin + Rituximab)

chemotherapy. His cycle 1 regimen was complicated by right-sided pleural effusion, drained by the interventional radiologist with 1,850 ml of clear yellow fluid removed. Cytology of pleural fluid showed no overt evidence of involvement by lymphoma but a small population of clonal B cells was detected. The patient was also with mucositis following cycle 1 and cycle 2, Vincristine was reduced by 20% because of that. Chest x-ray was repeated after cycle 2 chemotherapy and it showed stable effusion. CT scan after 4 cycles showed good treatment response indicated by significant improvement in supraclavicular, mediastinal, and bilateral hilar lymphadenopathy, as well as interval reduction in size of the renal mass and disappearance for the mass at site of previous FDG uptake at gastric cardia. Patient tolerated cycle 5/6 R-EPOCH well without severe side effects.

Discussion

First described by Oyama *et al.*, in elderly Japanese patients, this entity is included as a provisional category in the WHO classification 2008 as EBV-positive diffuse large B-cell lymphoma of the elderly. It is defined as an EBV+ clonal B-cell lymphoproliferation that occurs in patients who are generally over the age of 50 without any known immunodeficiency or history of lymphoma. The lesion is thought to be related to immunosenescence, the natural decay of the immune system as a consequence of aging. Recent research also showed that EBV-positive DLBCL can be seen in younger, immunocompetent patients. The clinical course is usually aggressive, with frequent extranodal involvement and overall a poor prognosis. Phenotypically, the lymphoma cells express B-cell markers (CD20, PAX5, and CD79a), most cases have an activated B-cell phenotype characterized by a neoplastic cell transformed from a late-stage of B-cell differentiation towards immunoblast/plasmablast with an increased accumulation of cytoplasmic mRNA of Ig K/L with increasing plasma cell transcription factor MUM1, and activation antigen CD30. Therefore, all cases in this category are strongly positive for MUM and approximately 40% positive for CD30, whereas CD10 and CD15 are negative.

Based on the immunoblastic/plasmablastic morphology, positive markers like CD138, MUM1, BCL6, CD30, EBER and high Ki-67 index, plasmablastic lymphoma (PBL) can be another diagnosis. PBL is a rare neoplasm with morphologic and immunophenotypic characteristics that overlap with aggressive large B-cell lymphomas. Although previously classified as a subtype of DLBCL, PBL is currently recognized as a distinct entity infrequently occurring outside the oral cavity and in the absence of HIV infection (3). Differentiating between DLBCL with plasmablastic differentiation and true cases of PBL is very challenging. The recent evidence of a poorer outcome in PBL compared to DLBCL makes it imperative to differentiate DLBCL with plasmablastic differentiation from true PBL.

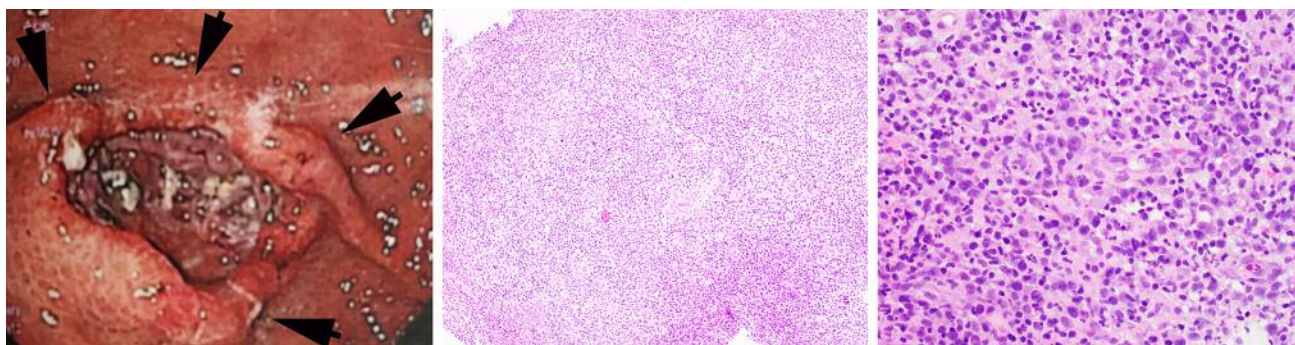


Figure 1. Upper GI endoscopic appearance showing a 2-cm ulcerated lesion (left); Histologically, the ulcerated tissue showing center atypical lymphoid cells infiltrate (mid, HE stain, 100 \times) and the neoplastic cells are medium to large in size showing features of immunoblasts (right, HE stain, 400 \times).

In PBL, the plasma cell markers (CD138, VS38c, CD38, and MUM1) seem to be almost universally expressed, expression of pan-B-cell markers including CD20 and PAX5 is usually absent. Pax5 is a B cell-specific activator protein whose expression is largely limited to cells with B lymphoid lineage commitment. It is regarded as a reliable B cell differentiation antigen before the B-cells acquire plasmacytic features. CD138 is accepted as a universal marker of normal and malignant plasma cells, seems to be more consistently associated with an advanced plasmablast or plasma cell phenotype, and was expressed significantly more common in the B cell marker-negative group. The co-expression of these two cell markers (CD138 and PAX5) is very rare. Our case is unique due to the fact that the tumor cells are positive for both CD138 and Pax5.

Most PBLs are positive for EBV (78%) with a predominance of type I latency pattern in contrast with type II and type III in EBV+ DLBCL of the elderly (4). Other plasma cell markers, such as XBP1s (5), PRDM1/BLIMP1 (6) and *c-MYC*-gene aberrations (7) can also help us differentiate true PBL from DLBCL with plasmablastic differentiation. A novel diagnostic scoring system which includes the immunohistochemical expression of CD10 and Pax5 is proposed to differentiate between DLBCL with plasmablastic differentiation and true cases of PBL (8).

In contrast to treatment for most cases of DLBCL, chemotherapy with cyclophosphamide, doxorubicin, vincristine, and prednisone is generally considered to be inadequate therapy for PBL (9). Instead, more intensive regimens such as hyperfractionated cyclophosphamide, vincristine, doxorubicin, and dexamethasone alternating with methotrexate and cytarabine are typically used. In the very rare case that PBL expresses CD20, rituximab has been added to the chemotherapy regimen with an excellent response (10).

Several groups have shown that patients with EBV-positive DLBCL have a worse prognosis when compared with patients with EBV-negative DLBCL, making EBV per se an independent adverse prognostic indicator (11). OK *et al.* reported that expression of CD30 is not only increased but also associated with a worse overall survival rate in patients with EBV-positive DLBCL (12). In that study, EBV+/CD30+ DLBCL patients had worse outcome than that in EBV+/CD30- DLBCL patients. Montes-Moreno *et al.* demonstrated that the acquisition of a partial plasmablastic phenotype in DLBCL is associated with aggressive clinical behavior (13). Several groups showed that addition of the anti-CD20 monoclonal antibody, rituximab, to anthracycline-based chemotherapy has clearly improved survival outcomes in patients with DLBCL in different clinical settings (14).

In conclusion, we report a rare case of primary gastric EBV-positive DLBCL of the elderly with partial plasmablastic phenotype, which is very difficult to differentiate with true PBL. EBV latency pattern, *c-MYC*-gene aberrations status, and other plasma cell markers such as XBP1s and PRDM1/BLIMP1 may help us achieve a more accurate diagnosis. EBV positivity, CD30 positivity and plasmablastic phenotype in DLBCL of the elderly is associated with aggressive clinical behavior, while adding anti-CD20 monoclonal antibody rituximab in the regimen may get a better response.

References

- 1 Nakamura S, Jaffe ES and Swerdlow SH: EBV positive diffuse large B-cell lymphoma of the elderly. *In*: WHO classification of tumours of haematopoietic and lymphoid tissues. Swerdlow SH, Campo E, Harris NL, *et al.* (eds.). Lyon, France, IARC Press, pp. 243-244, 2008.

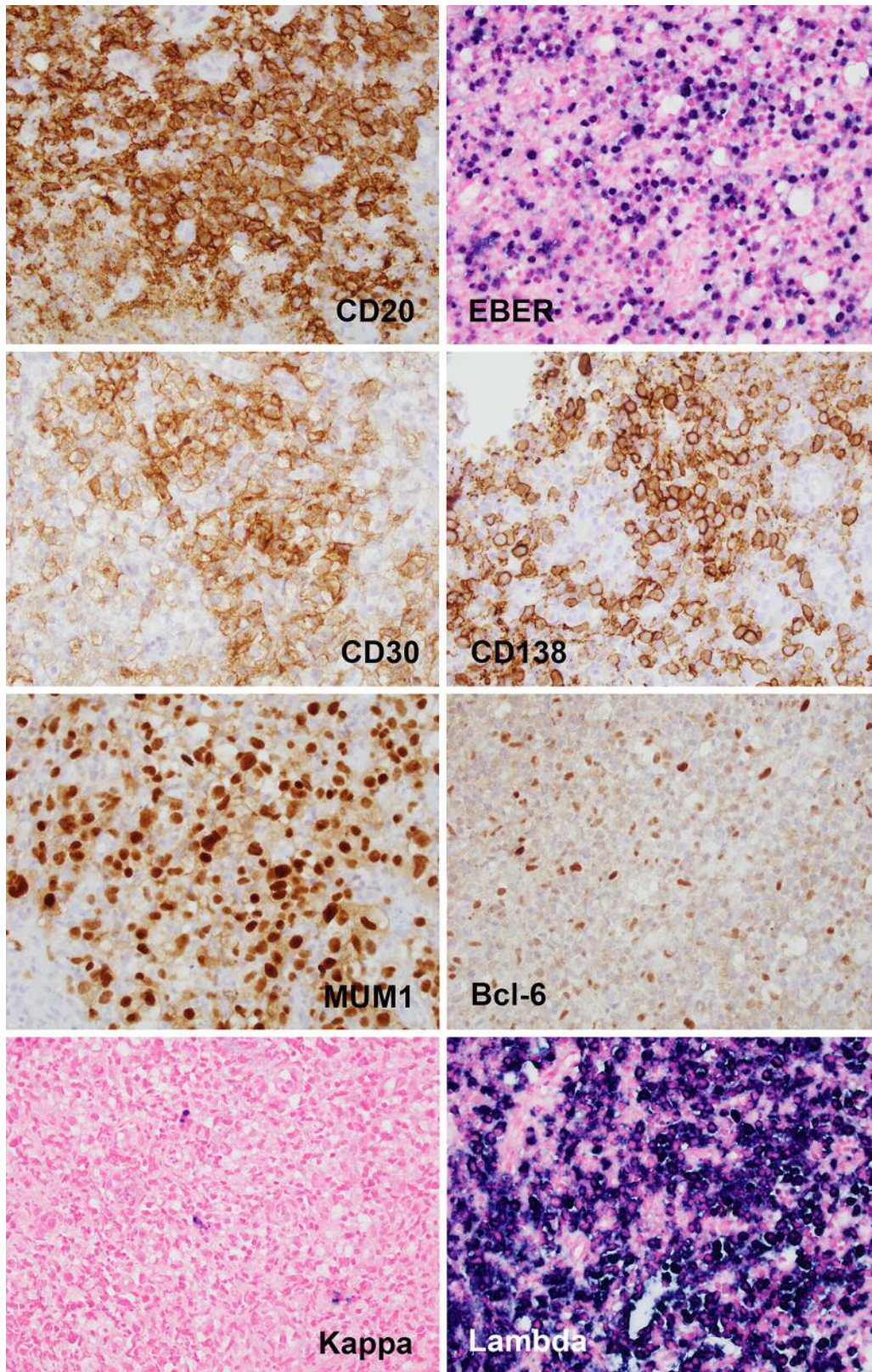


Figure 2. Immunohistochemistry and in situ hybridization of the gastric ulcerated lymphoid tumor. The tumor cells are positive for CD20, EBER, CD30, CD138, MUM1 and Lambda, focally positive for Bcl-6. They are negative for Kappa (all, magnification 400 \times).

- 2 Swerdlow SH, Campo E, Pileri SA, Harris NL, Stein H, Siebert R, Advani R, Ghielmini M, Salles GA, Zelenetz AD and Jaffe ES: The 2016 revision of the World Health Organization (WHO) classification of lymphoid neoplasms. *Blood* 127: 2375-2390, 2016.
- 3 Stein H, Harris NL and Campo E: Plasmablastic lymphoma. *In*: WHO Classification of tumours of haematopoietic and lymphoid tissues. Swerdlow SH, Campo E, Harris NL, *et al.* (eds.). Lyon, France, IARC Press, pp. 256-257, 2008.
- 4 Castillo JJ, Beltran BE, Miranda RN, Young KH, Chavez JC and Sotomayor EM: EBV-positive diffuse large B-cell lymphoma of the elderly: 2016 update on diagnosis, risk-stratification, and management. *Am J Hematol* 91: 529-537, 2016.
- 5 Maestre L, Tooze R, Canamero M, Montes-Moreno S, Ramos R, Doody G, Boll M, Barrans S, Baena S, Piris MA and Roncador G: Expression pattern of XBP1 (S) in human B cell lymphomas. *Haematologica* 94: 419-422, 2009.
- 6 Garcia JF, Roncador G, Sanz AI, Maestre L, Lucas E, Montes-Moreno S, Fernandez Victoria R, Martinez-Torrecuadrara JL, Marafioti T, Mason DY and Piris MA: PRDM1/BLIMP-1 expression in multiple B and T-cell lymphoma. *Haematologica* 91: 467-474, 2006.
- 7 Valera A, Balagué O, Colomo L, Martínez A, Delabie J, Taddesse-Heath L, Jaffe ES and Campo E: IG/MYC rearrangements are the main cytogenetic alteration in plasmablastic lymphomas. *Am J Surg Pathol* 34: 1686-1694, 2010.
- 8 Boy S, Van Heerden M, Pool R, Willem P and Slavik T: Plasmablastic lymphoma versus diffuse large B cell lymphoma with plasmablastic differentiation: proposal for a novel diagnostic scoring system. *J Hematopathol* 8: 3-11, 2015.
- 9 Castillo JJ, Chavez JC, Hernandez-Ilizaliturri FJ and Montes-Moreno S: CD20-negative diffuse large B-cell lymphomas: biology and emerging therapeutic options. *Expert Rev Hematol* 8: 343-354, 2015.
- 10 Yan M, Dong Z, Zhao F, Chauncey T, Deauna-Limayo D, Wang-Rodriguez J, Liu D, Wang HY and Pilz R: CD20-positive plasmablastic lymphoma with excellent response to bortezomib combined with rituximab. *Eur J Haematol* 93: 77-80, 2014.
- 11 Lu TX, Liang JH, Miao Y, Fan L, Wang L, Qu XY, Cao L, Gong QX, Wang Z, Zhang ZH, Xu W and Li JY: Epstein-Barr virus positive diffuse large B-cell lymphoma predict poor outcome, regardless of the age. *Sci Rep* 5: 12168, 2015.
- 12 Ok CY, Li L, Xu-Monette ZY, Visco C, Tzankov A, Manyam GC, Montes-Moreno S, Dybkaer K, Chiu A, Orazi A, Zu Y, Bhagat G, Chen J, Richards KL, Hsi ED, Choi WW, van Krieken JH, Huh J, Ai W, Ponzoni M, Ferreri AJ, Farnen JP, Møller MB, Bueso-Ramos CE, Miranda RN, Winter JN, Piris MA, Medeiros LJ and Young KH: Prevalence and clinical implications of Epstein-Barr virus infection in de novo diffuse large B-cell lymphoma in Western countries. *Clin Cancer Res* 20: 2338-2349, 2014.
- 13 Montes-Moreno S, Gonzalez-Medina AR, Rodriguez-Pinilla SM, Maestre L, Sanchez-Verde L, Roncador G, Mollejo M, García JF, Menarguez J, Montalbán C, Ruiz-Marcellan MC, Conde E and Piris MA: Aggressive large B-cell lymphoma with plasma cell differentiation: immunohistochemical characterization of plasmablastic lymphoma and diffuse large B-cell lymphoma with partial plasmablastic phenotype. *Haematologica* 95: 1342-1349, 2010.
- 14 Pfreundschuh M, Kuhnt E, Trumper L, Osterborg A, Trneny M, Shepherd L, Gill DS, Walewski J, Pettengell R, Jaeger U, Zinzani PL, Shpilberg O, Kvaloy S, de Nully Brown P, Stahel R, Milpied N, López-Guillermo A, Poeschel V, Grass S, Loeffler M and Murawski N; MabThera International Trial (MInT) Group: CHOP-like chemotherapy with or without rituximab in young patients with good-prognosis diffuse large-B-cell lymphoma: 6-year results of an open-label randomised study of the MabThera International Trial (MInT) Group. *Lancet Oncol* 12: 1013-1022, 2011.

Received December 9, 2017

Revised January 3, 2018

Accepted January 4, 2018