

Risk Factors for Transumbilical Wound Complications in Laparoscopic Gastric and Colorectal Surgery

KODAI TOMIOKA, MASAHIKO MURAKAMI, AKIRA FUJIMORI, MAKOTO WATANABE,
TOMOTAKE KOIZUMI, SATORU GOTO, KOJI OTSUKA and TAKESHI AOKI

*Department of Surgery, Division of Gastroenterological and General Surgery,
Showa University, Tokyo, Japan*

Abstract. *Aim: To investigate the risk factors of transumbilical incision for organ removal in laparoscopic surgery. Patients and Methods: We enrolled 643 consecutive patients undergoing laparoscopic surgery from 2010 to 2013. Superficial surgical site infection (SSI) and transumbilical port site hernia were recorded. Results: The participants underwent gastric (n=253) and colorectal (n=390) resections. SSI was observed in 17 cases (colorectal in 15; gastric in two) (2.64%) with colorectal resection having a high rate of SSI [odds ratio (OR)=5.020; $p=0.022$]. Hernia occurred in 23 cases (colorectal in 22; gastric in one) (3.53%), with a significantly higher rate for colorectal resection (OR=13.052; $p<0.001$). Female (OR=5.410; $p=0.021$) and history of diabetes mellitus (OR=4.437; $p=0.009$) contributed to the risk for developing a hernia. Conclusion: Especially in relation to hernia, being female and having diabetes mellitus were considered independent risk factors.*

Laparoscopic surgery has become a standard gastrointestinal procedure that is currently the first choice. Despite this, there are some ongoing debates, some of which concern the surgical incision. Although adding an incision in the umbilicus has been avoided for fear of increased rates of surgical site infection (SSI) and postoperative adhesion, it was not associated with complications (1). There are a number of advantages, including esthetic ones; therefore, we have performed transumbilical incisions for organ removal since shortly after the introduction of laparoscopic surgery in the 1990s. For anatomical reasons, transumbilical

incisions can easily be craniocaudally extended to adjust for the size of the excised organs, while maintaining the incision length at a minimum. Therefore, in our Department, after inserting 12-mm ports in the umbilicus, we extend the umbilical wound by approximately 3-5 cm in a craniocaudal direction to remove organs or anastomose them outside the body. In this study, we evaluated the complication rates and risk factors associated with transumbilical incisions and compared the incidence of its complications between colorectal and gastric resections in a cohort study of 643 consecutive laparoscopy performed at our Department in 4 years to examine the usefulness of this incision for laparoscopic abdominal surgery.

Patients and Methods

Study design. This was a cohort study of 643 consecutive patients who underwent laparoscopic procedures at the Department of Surgery, Division of Gastroenterological and General Surgery, Showa University, Japan, between January 2010 and December 2013. We excluded the following cases (n=447): those with follow-up at other hospitals from the early postoperative period within 3 months from surgery (n=221), those without organ removal from the transumbilical wound (n=115), those converted to laparotomy (n=65), and those undergoing multiple simultaneous procedures (n=46). Finally, 643 cases were included. The study protocol was approved by the Showa University Institutional Review Board (Approval number: 1917).

Data collection and outcomes. Data were collected from our hospital database on patient sex, age, height, weight, body mass index (BMI), past history of diabetes mellitus (DM), type of surgery, surgical duration, amount of blood loss, maximum tumor diameter, intraoperative accident, SSI, umbilical wound port site hernia, and length of postoperative hospital stay. SSI was defined according to the criteria of the American College of Surgeons National Surgical Quality Improvement Program (2). Wound hernia was defined according to the definition by Tonouchi *et al.* (3). In order to evaluate early- and late-onset umbilical wound complications for laparoscopic procedures, we followed-up the patients every 3 months in the first postoperative year, and yearly thereafter for 3 years. We evaluated SSI as a short-term complication, and umbilical port site

This article is freely accessible online.

Correspondence to: Kodai Tomioka, Department of Surgery, Division of Gastroenterological and General Surgery, Showa University, 1-5-8 Hatanodai, Shinagawa, Tokyo 142-8666, Japan. E-mail: tomioka@med.showa-u.ac.jp

Key Words: Transumbilical, complication, wound.

hernia as a long-term complication and risk factors for them. SSIs were monitored by the Infection Control Team of our hospital, and umbilical port site hernias were routinely assessed by follow-up computed tomography (CT).

Procedure. In all cases, a second-generation cephalosporin was given intravenously 30 minutes before surgery, and wound closure followed a standardized protocol.

Umbilical incision: We did not clean the navel before operation. If gross contamination was observed in the periumbilical area, cleaning was carried out by swab containing olive oil and the removal of as much foreign material as possible with Kocher forceps after the induction of anesthesia. We then cut the skin in a craniocaudal direction from the center of the navel and inserted the first port as closed method (Figure 1a and b). For cosmetic reasons, the extent of the skin incision was minimized, but the length of incision to the fascia was longer than that to the skin.

Specimen extraction and anastomosis: The umbilical wound was extended in the appropriate craniocaudal direction to fit the size of the organ (Figure 1c). The sarcolemma was cut as extensively as possible, while the skin incision was minimized by employing care and skin extension. A wound protector was attached to the umbilical wound, the specimen was then extracted from the umbilical wound (Figure 1d).

Wound closure: The anterior and posterior laminae of the rectal sheath on the wound were continuous-sutured with monofilament absorbable sutures (Figure 1e). All wounds were washed with 50 ml saline, and buried, interrupted dermal sutures were performed using 4-0 absorbable monofilament sutures. The center of the navel was placed as close to the preoperative natural depression as possible when suturing the dermis and the fascia of the center of the navel. In order to prevent superficial SSI, we used silver and hydrocolloid dressings, and the wound was managed as sealed coating for 48 hours postoperatively (Figure 1f).

Statistical analysis. Risk factors were investigated by univariate analyses, including the chi-square test, Fisher's exact test, Wilcoxon rank sum test, Wilcoxon signed-rank test, and univariate logistic regression. Significant variables were then analyzed by multivariate logistic regression. All analyses were performed using JMP 11 (SAS Institute Inc., Cary, NC, USA). Statistical assessments were two-sided and used a significance level of 0.05. Data are presented as means±standard deviation, unless otherwise specified.

Results

A total of 1,090 consecutive patients underwent laparoscopic procedures during the study period, of which we excluded 447 cases. Of the remaining 643 cases, 394 were male (61.3%) and 249 were female (38.7%), with a mean±SD age of 69.42±11.52 years (median=71 years, range=22-91 years). Patients underwent gastrectomy (n=253) or colectomy (n=390). The patient characteristics are shown in Table I.

Short-term complication: Umbilical wound SSI. SSI was observed in 17 cases (2.64%), with 15 (3.85%) and two cases (0.79%) following colorectal and stomach resection, respectively. In the univariate analysis comparing the groups

with and without SSI, significant differences were observed for the procedure, the analysis revealed that SSI occurred more in patients undergoing colorectal resection than in those undergoing gastric resection (OR=5.020; 95% CI=1.138 to 22.141; $p=0.022$) (Table II).

Long-term complication: Umbilical wound hernia. Hernia was observed in 23 cases (3.58%), with 22 (5.64%) and one case (0.40%) following colorectal and stomach resection, respectively. The median time to the development of hernia was 12 months (range=3-24 months). When comparing the groups with and without umbilical wound hernias, there were significant differences in sex ($p=0.030$), weight ($p=0.011$), BMI ($p<0.001$), DM ($p=0.003$), and procedure ($p<0.001$). Following multivariate analysis of the three variables that showed a significant difference, being female (OR=5.410; 95% CI=1.284 to 25.700; $p=0.021$), DM (OR=4.437; 95% CI=1.485 to 12.459; $p=0.009$), and colorectal resection (OR=13.052; 95% CI=2.639 to 236.520; $p<0.001$) remained significantly associated with risk of hernia (Table III).

Discussion

Midline abdominal incision is a basic laparotomy procedure in gastrointestinal surgery, and it is usually recommended to avoid the navel because the area is considered dirty, and because it connects to the *ligamentum teres* (4). Nevertheless, umbilical incisions are sometimes used (5). Even in patients with much subcutaneous fat, the umbilical fossa allows for easier access to the peritoneum because of its comparatively thin adipose tissue layer. Moreover, wound extension is fairly easy in the craniocaudal direction. Thus, umbilical incisions can be considered reasonable and useful for laparoscopic surgery.

Regarding umbilical port site SSI, there have been a number of reports and a systematic review indicating that SSI occurs at rates of 1.06-25.9% (6-10).

In 1963, Jesus *et al.* reported that out of 44 patients who underwent laparotomy by midline abdominal incision through the navel, only two developed wound infection; consequently, they concluded that transumbilical incision was a safe surgical technique (11). Later, in 1987, Peas *et al.* retrospectively compared transumbilical incision with a method of avoiding the navel in an arc shape, but found no significant differences in rates of infection and hernia (1).

We investigated the usefulness of transumbilical incision for organ removal over a 4-year period. The following were considered the main advantages of this approach: (i) better cosmetic outcomes and ease of extension, (ii) ability to minimize the skin incision, and (iii) ability to reach the abdominal cavity safely and securely *via* the shortest anatomical distance. Concerning wound extension, if fasciotomy is carried out in full, then even without

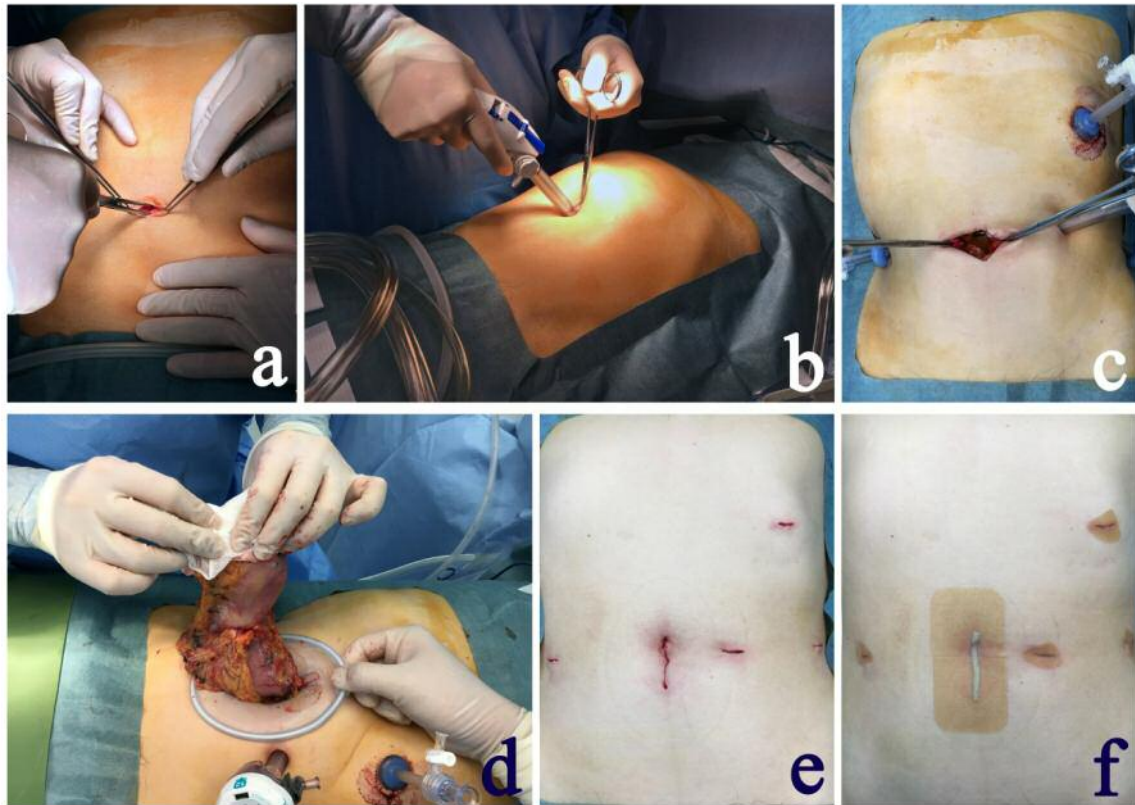


Figure 1. a: Transumbilical wound. Cutting the center of the umbilicus in the vertical direction in the head-to-tail side. b: Inserting the 12-mm port. c: Cutting and extending the wound to enable removal of the organ. d: Resected specimens were removed with wound protector. e: The wound just after being closed. f: The wound was covered with silver ions and hydrocolloid dressing.

significant incision, skin extension, or wound enlargement beyond the navel, it is possible to extract or remove large specimens by utilizing the extensibility of the skin in the umbilicus.

We also examined the risk factors for complications. There have been many reports on port-related complications in laparoscopic surgery, with Targarona *et al.* reporting that laparoscopic procedures had reduced the incidence of port site infections and other wound-related complications (12). Weiss *et al.* reported that increased BMI and long incisions could be risk factors for umbilical wound complications (8). According to Horiuchi *et al.* (13) and Reid *et al.* (14), and as routinely used in our Department, wound retractors can prevent infection after laparoscopic colorectal procedures, indicating that methods and instruments used are important.

Concerning the surgical procedure, SSIs were observed significantly more in those undergoing colorectal resections ($n=15$; 3.85%) than gastric resections ($n=2$; 0.79%) ($p=0.022$) (Table II). This result might be related to the anastomosis method. Intra-abdominal anastomosis is generally performed in gastrectomy and rectal resection.

However, extra-abdominal anastomosis is frequently performed in colectomy. Although no literature to date has investigated the cause of SSI in colorectal resection, the most likely cause is transfer of *Escherichia coli* from the resected organ margins.

Although the risk factors for SSI limited to laparoscopic colon resection have been reported to include increased BMI and a history of DM (15-17), in the present study no variable showed significant differences. At our Department, the patients with DM were allowed to attend diabetic assessments preoperatively, and were operated on only after achieving glycemic control.

Several studies have reported the incidence of port site hernia, with rates of 0-5.2% (7), 0.4% (6), 1.06% (9), 1.4% (8), and 25.9% (10). The reports by Morita *et al.* (9) and Comajuncosas *et al.* (10) were limited to colorectal resection and cholecystectomy, respectively. In the present study, umbilical port site hernia was observed in 23 out of 643 cases (3.58%). In terms of surgical procedures, the majority of cases ($n=22$; 5.64%) occurred after colorectal resection ($p<0.001$) (Table III).

Table I. Demographic data of patients undergoing colorectal and gastric resection.

Variable	Gastric (n=253)	Colorectal (n=390)	p-Value
Age, years	69.68±11.55	69.31±11.56	0.730
Sex: male:female, n	169:84	225:165	0.025
Height, cm	160.35±9.19	159.10±9.50	0.105
Weight, kg	57.27±11.07	57.22±11.50	0.957
Body mass index, kg/m ²	22.20±3.41	22.47±3.58	0.331
Diabetes mellitus, n (%)	20 (7.91%)	38 (9.74%)	0.482
Operation time, min	221.17±69.08	177.39±71.90	<0.001
Blood loss, g	123.21±181.34	49.66±139.95	<0.001
Tumor major axis, mm	40.75±26.23	40.30±23.20	0.646
Intraoperative accident, n (%)	0 (0.0%)	2 (0.51%)	0.522

Continuous data are expressed as the mean±SD.

Table II. Demographic data of patients with and without transumbilical wound surgical site infection (SSI).

Variable	No SSI (n=626)	SSI (n=17)	p-Value	OR	95% CI
Age, years	69.42±11.56	69.35±10.67	0.980		
Sex: male:female, n	383:243	11:6	>0.999		
Height, cm	159.61±9.43	159.51±7.95	0.963		
Weight, kg	57.26±11.33	56.44±11.19	0.768		
Body mass index, kg/m ²	22.37±3.52	22.09±3.49	0.744		
Diabetes mellitus, n (%)	56 (8.95%)	2 (11.76%)	0.660		
Operative time, min	195.11±74.32	177.35±56.02	0.218		
Blood loss, g	78.70±162.56	75.06±117.00	0.902		
Tumor major axis, mm	40.36±24.36	45.06±27.45	0.495		
Intraoperative accident, n (%)	2 (0.32%)	0 (0%)	>0.999		
Procedure, n (%)			0.022	5.020	1.138-22.141
Gastric resection	251 (40.11%)	2 (11.76%)			
Colorectal resection	375 (59.90%)	15 (88.24%)			

CI: Confidence interval; OR: odds ratio. Continuous data are expressed as the mean±SD.

Table III. Demographic data of patients with and without transumbilical wound hernia.

Variable	No hernia (n=620)	Hernia (n=23)	p-Value	OR	95% CI	p-Value
Age, years	69.74±12.28	69.56±11.48	0.293			
Gender: male:female, n	385:235	9:14	0.030	0.185	0.039-0.779	0.021
Height, cm	159.67±9.38	157.92±9.78	0.407			
Weight, kg	57.00±11.27	63.48±11.11	0.011	1.052	0.963-1.149	0.256
Body mass index, kg/m ²	22.24±3.47	25.39±3.34	<0.001	1.076	0.853-1.361	0.534
Diabetes mellitus, n (%)	51 (8.23%)	7 (30.43%)	0.003	4.437	1.485-12.459	0.009
Surgical site infection, n (%)	16 (2.58%)	1 (4.35%)	0.466			
Operative time, min	194.92±74.35	187.17±62.03	0.565			
Blood loss, g	79.08±163.30	65.56±101.12	0.546			
Tumor major axis, mm	40.41±24.57	42.52±20.98	0.642			
Intraoperative accident, n (%)	2 (0.32%)	0 (0%)	>0.999			
Procedure, n (%)			<0.001	13.052	2.639-236.520	<0.001
Gastric resection	252 (40.65%)	1 (4.35%)				
Colorectal resection	368 (59.35%)	22 (95.65%)				

There have been numerous reports about the risk factors for umbilical port site hernia. Nassar *et al.* observed that extension of the umbilical wound was the most significant risk factor for sarcolemmal deficit after organ removal (18). In addition, despite their research being limited to cholecystectomies, Comajuncosas *et al.* pointed out that DM, SSI, wound size, and increased BMI were risk factors for hernia (10).

In our study, univariate analysis for port site hernia indicated a greater risk associated with being female ($p=0.006$), increasing weight ($p=0.011$), increasing BMI ($p<0.001$), a history of DM ($p=0.003$) and colorectal resection ($p<0.001$). Finally, the multivariate analysis revealed that being female (OR=5.410), having DM (OR=4.437) and undergoing colorectal resection (OR=13.052) contributed to the risk for developing a hernia (Table III). In terms of differences between the two procedures, the outcome may depend on the umbilical wound extension for extracorporeal manipulation of the remaining intestinal tract at the time of dissection and anastomosis. Colorectal resection sometimes needs longer incision extension than does gastric resection. Moreover, due to the richness in subcutaneous fat in women, suturing a transumbilical wound might be difficult. Thus, technical factors were also conceivably involved; it was necessary to pay particular attention in the case of female patients.

The median time to occurrence of transumbilical hernia was 12 months (range=3-24 months). One report has suggested that all hernias occur within 6 months of surgery following an average postoperative follow-up of 22 months (8). In addition, SSI was excluded as a risk factor of transumbilical wound hernia.

There were three major differences between this and other reports. Firstly, we examined major abdominal surgery for malignant diseases. In addition, the surgeons had at least 5 years' postgraduate experience, with the possibility of minimal selection bias by the surgeon. Due to the strict postoperative follow-up, there was minimal loss of data from follow-up. Secondly, all specimens were removed through the transumbilical wounds and we extended the wound craniocaudally as necessary. Thus, we evaluated the usefulness of transumbilical incisions, showing that they can be extended to accommodate any laparoscopic surgery. Thirdly, all procedures from transumbilical incision to wound coating were standardized, thereby minimizing variation and bias.

This study has several limitations. Firstly, this was a retrospective study, and some variables were unknown, including the wound length. Secondly, the low incidence and small number of adverse events means that we cannot exclude the possibility of a type-2 error. Thirdly, our Institution shifted to laparoscopic surgery in 2010; therefore, we were unable to perform a comparison with open surgery.

The incidence of transumbilical wound SSI and hernia was 2.32% and 3.58%, respectively. These low occurrence rates might be influenced by the standardization of wound closure and covering method. SSI and hernia occurred at a significantly higher rate in colorectal resection than gastric resection. Especially in relation to hernia, being female and having DM were considered as independent risk factors. We conclude that in modern laparoscopic surgery, our transumbilical incision for organ removal, including wound closure and covering method, can be considered a good surgical approach.

Acknowledgements

The Authors thank the patients for allowing us to publish this study. None of the Authors has any conflict of interest to declare in regard to this study.

References

- 1 Paes TRF, Stroker DL, Ng T and Morecroft J: Circumbilical versus transumbilical abdominal incision. *Br J Surg* 74: 822-823, 1987.
- 2 Horan TC, Gaynes RP, Martone WJ, Jarvis WR and Emori TG: CDC definitions of nosocomial surgical site infections, 1992: a modification of CDC definitions of surgical wound infections. *Am J Infect Control* 20: 271-274, 1992.
- 3 Tonouchi H, Ohmori Y, Kobayashi M and Kusunoki M: Trocar site hernia. *Arch Surg* 139: 1248-1256, 2004.
- 4 Glyn GJ: The Anatomy of General Surgical Operations. Third Edition. Philadelphia: Churchill Livingstone, pp. 6-7, 2006.
- 5 Lee JS: Surgical Anatomy and Technique. Second Edition. New York: Springer, pp. 157-160, 2000.
- 6 Lal P, Vindal A, Sharma R, Chander J and Ramteke VK: Safety of open technique for trocar first placement in laparoscopic surgery: a series of 6,000 patients. *Surg Endosc* 26: 182-188, 2012.
- 7 Swank HA, Mulder IM, la Chapelle CF, Reitsma JB, Lange JF and Bemelman WA: Systematic review of trocar site hernia. *Br J Surg* 99: 315-323, 2012.
- 8 Weiss HG, Brunner W, Biehl MO, Schirnhöfer J, Pimpl K, Mittermair C, Obrist C, Brunner E and Hell T: Wound complications in 1145 consecutive transumbilical single-incision laparoscopic procedures. *Ann Surg* 259: 89-95, 2014.
- 9 Morita Y, Yamaguchi S, Ishii T, Tashiro J, Kondo H, Suzuki A, Hara K and Koyama I: Does transumbilical incision increase incisional hernia at the extraction site of laparoscopic anterior resection? *Am J Surg* 209: 1048-1052, 2015.
- 10 Comajuncosas J, Hermoso J, Gris P, Jimeno J, Orbeal R, Vallverdú H, López Negre JL, Urgellés J, Estalella L and Parés D: Risk factors for umbilical trocar site incisional hernia in laparoscopic cholecystectomy: a prospective 3-year follow-up study. *Am J Surg* 207: 1-6, 2014.
- 11 Jesus G: Midline abdominal transumbilical incision. *Phillipp J Surg Spec* 18: 188-193, 1963.
- 12 Targarona EM, Balague C, Knook MM and Trías M: Laparoscopic surgery and surgical infection. *Br J Surg* 87: 536-544, 2000.

- 13 Horiuchi T, Tanishima H, Tamagawa K, Sakaguchi S, Shono Y, Tsubakihara H, Tabuse K and Kinoshita Y: A wound protector shields incision sites from bacterial invasion. *Surg Infect* 11: 501-503, 2010.
- 14 Reid K, Pockney P, Draganic B and Smith SR: Barrier wound protection decreases surgical site infection in open elective colorectal surgery: A randomized clinical trial. *Dis Colon Rectum* 53: 1374-1380, 2010.
- 15 Aimaq R, Akopian G and Kaufman HS: Surgical site infection rates in laparoscopic *versus* open colorectal surgery. *Am Surg* 77: 1290-1204, 2011.
- 16 Anannamcharoen S, Vachirasrisirikul S and Boonya-Assadorn C: Incisional surgical site infection in colorectal surgery patients. *J Med Assoc Thai* 95: 42-47, 2012.
- 17 Kiran RP, El-Gazzaz GH and Vogel JD and Remzi FH: Laparoscopic approach significantly reduces surgical site infections after colorectal surgery: data from national surgical quality improvement program. *J Am Coll Surg* 211: 232-238, 2010.
- 18 Nassar AH, Ashkar KA, Rashed AA and Abdumoneum MG: Laparoscopic cholecystectomy and the umbilicus. *Br J Surg* 84: 630-633, 1997.

Received May 25, 2017

Revised June 14, 2017

Accepted July 19, 2017