

Correlation Between Infection Status of Epstein-Barr Virus and ^{18}F -Fluorodeoxyglucose Uptake in Patients with Advanced Gastric Cancer

SAE JUNG NA¹, HYE LIM PARK², JOO HYUN O², SUNG YONG LEE¹,
KYO YOUNG SONG³ and SUNG HOON KIM²

¹Department of Radiology, Uijeongbu St. Mary's Hospital, College of Medicine, The Catholic University of Korea, Seoul, Republic of Korea;

²Department of Radiology, Seoul St. Mary's Hospital, College of Medicine, The Catholic University of Korea, Seoul, Republic of Korea;

³Department of Surgery, Seoul St. Mary's Hospital, College of Medicine, The Catholic University of Korea, Seoul, Republic of Korea

Abstract. *Background:* Epstein-Barr virus-associated gastric cancer (EBVaGC) is one of the four molecular subtypes of gastric cancer, as defined by the classification recently proposed by The Cancer Genome Atlas. We evaluated the correlation between EBV positivity and ^{18}F -fluorodeoxyglucose (^{18}F -FDG) uptake by positron emission tomography/computed tomography (PET/CT) in patients with gastric cancer. *Materials and Methods:* We retrospectively enrolled patients with gastric cancer who underwent pretreatment ^{18}F -FDG PET/CT and subsequent surgical resection, and then were diagnosed with advanced gastric cancer (pathologic stage $\geq T2$ with any N stage). Maximum standardized uptake values (SUV_{max}) of gastric cancer were measured by pretreatment ^{18}F -FDG PET/CT. EBV sequences were detected by in situ hybridization (ISH) techniques. We analyzed the correlation between EBV positivity, clinicopathologic features and metabolic activity of the primary tumor. *Results:* A total of 205 patients were included and 15 (7.3%) patients were identified as having EBV-positive gastric cancer. Age, gender, tumor location, and histological type showed no significant differences between EBV-positive and negative groups. EBV-positive

cancer is significantly more frequent in the higher-metabolic-tumor group than in the lower one ($p=0.032$). The mean SUV_{max} of gastric cancers showed significant differences between EBV-positive and negative groups (9.9 ± 4.2 vs. 7.0 ± 4.8 , $p=0.026$). *Conclusion:* The infection status of EBV was significantly related to the ^{18}F -FDG uptake of primary tumors in patients with advanced gastric cancer.

Epstein-Barr virus-associated gastric cancer (EBVaGC) is defined as the monoclonal proliferation of carcinoma cells with latent EBV infection, which can be verified by in situ hybridization targeted at EBV-encoded small RNA (EBER) (1). The Cancer Genome Atlas (TCGA) research network recently proposed the following molecular classification of gastric cancer; i) Epstein-Barr virus (EBV)-positive tumors, ii) microsatellite-unstable tumors, iii) genomically-stable tumors, and iv) tumors with chromosomal instability (2). Two to 20% of gastric cancers are EBV positive (3-5). In a meta-analysis of 70 studies including 15,952 cases, EBVaGCs occurred more frequently in males and non-antral regions (6). A recent large multicenter study of 4,599 gastric carcinoma cases demonstrated that EBVaGC is inversely associated with stage and EBV-positive tumor was correlated with favorable prognosis after adjusting for stage and other confounds (7).

^{18}F -fluorodeoxyglucose (FDG) has been used in the detection of various cancers since advances in the positron emission tomography/computed tomography (PET/CT) hybrid imaging system. Gastric cancer glucose metabolic activity by ^{18}F -FDG PET/CT is highly variable. Previous studies have shown that the metabolic activity of gastric cancer lesions is associated with depth of invasion, tumor size, lymph node metastasis, lymphovascular invasion, Lauren's classification and histologic type (8). Furthermore,

This article is freely accessible online.

Correspondence to: Sung Hoon Kim, MD, Ph.D., Department of Radiology, Seoul St. Mary's Hospital, The Catholic University of Korea, 222 Banpo-daero, Seocho-gu, Seoul, 06591, Republic of Korea. Tel.: 82-2-2258-1553, e-mail: sghn@catholic.ac.kr

Key Words: Positron emission tomography, gastric cancer, Epstein-Barr virus, tumor metabolism.

several reports have studied the correlation of ^{18}F -FDG PET/CT metabolic parameters and patient prognosis. These have demonstrated that high metabolic gastric cancers are related to poor prognosis (9-11).

To date, there has been no study investigating the relationship between metabolic activity and EBVaGC. Therefore, we evaluated the metabolic status of tumors using ^{18}F -FDG PET/CT according to EBV positivity in patients with advanced gastric cancer.

Materials and Methods

Patients. We retrospectively enrolled patients who had confirmed gastric cancer and underwent ^{18}F -FDG PET/CT prior to therapy followed by curative surgical resection from August 2014 to July 2016 at Seoul St. Mary's hospital. Clinicopathologic data were retrospectively reviewed. All enrolled patients underwent total or subtotal gastrectomy with D1 or D2 lymph node dissection. Tumor staging was done based on the TNM classification proposed by the Union International Cancer Control 7th edition [Leslie H. Sobin (Editor) MKGE, Christian Wittekind (Editor) (2009) TNM Classification of Malignant Tumours, 7th Edition]. Patients who had pathologic T stage 1 (pT1) were excluded from this study. This study was approved by the Institutional Review Board of Seoul St. Mary's Hospital (KC17RASI0052) and the requirement to obtain informed consent was waived.

PET/CT imaging. All patients fasted for at least 6 h before the ^{18}F -FDG PET/CT study. ^{18}F -FDG (3.7-4.4 MBq/kg) was injected intravenously and scanning began 60 min later. No intravenous contrast agent was used. Studies were acquired on one of the following PET/CT in-line systems: Biograph Duo, Biograph TruePoint, Biograph mCT (Siemens Medical Solutions, Knoxville, TN, USA) or Discovery 710 (GE Healthcare, Milwaukee, WI, USA). There were 6-8 bed positions, and the acquisition time was 2 min per bed position. CT began at the orbitomeatal line and progressed to the upper thigh using standard protocol: 130 kVp, 80 mAs and 5-mm slice thickness (Biograph Duo); 120 kVp, 50 mAs and 5-mm slice thickness (Biograph TruePoint); 100-120 kVp, variable mAs adjusted by topographic image and 3-mm slice thickness (Biograph mCT); and 120 kVp, variable mAs adjusted by topographic image and 2.5-mm slice thickness (Discovery 710). PET followed immediately over the same body region. The CT data were used for attenuation correction, and images were reconstructed using a standard ordered-subset expectation maximization algorithm. Point spread function correction (Biograph TruePoint, Biograph mCT, Discovery 710) and time-of-flight information (Biograph mCT, Discovery 710) were incorporated into the reconstruction algorithm.

Image analysis. All PET scans were reviewed by two experienced nuclear medicine physicians who were blinded to the histopathologic findings. PET/CT was evaluated visually and quantitatively. In the visual analysis, the PET scan was considered positive when perceptible FDG uptake that could be distinguished from physiologic gastric activity was noted at the site of the primary gastric tumor lesion as seen in the staging work-up endoscopy or enhanced CT. If the interpretations were different between the readers, the results were discussed until a consensus was reached. For quantitative

analysis, SUV_{max} was measured from all patients by drawing a volume of interest (VOI) at the primary tumor lesion. One nuclear medicine physician (SJN) measured the metabolic parameter of the primary tumor, according to the tumor defined by consensus while blinded to the pathologic result. If no perceptible FDG uptake was noted at the tumor site, a fixed VOI was dropped at the site corresponding to the known gastric cancer, and the SUV_{max} was measured. All FDG PET parameters were measured using the commercial software XD3 (Mirada Medical, Oxford, UK) (12-14).

Clinicopathological factors. We assessed the relationships between the following histopathological variables: depth of tumor invasion (pT stage), location of tumor, nodal metastasis (pN stage), and histologic type. pT and pN stages were based on the TNM 7th edition. Tumor location was categorized into antral or non-antral regions. The histopathologic type at the primary tumor site was categorized as papillary adenocarcinoma, tubular adenocarcinoma (well or moderately differentiated), poorly differentiated adenocarcinoma, signet-ring cell carcinoma or mucinous adenocarcinoma according to the World Health Organization classification with Japanese modification (15, 16). To detect EBV, the Epstein-Barr virus-encoded small RNA-1 (EBER1)-in situ hybridization method was used.

Statistical analysis. Continuous variables are expressed as means (\pm standard deviation) or medians (range) and were compared using independent *t*-tests or ANOVA. To evaluate the relationship between two categorical variables, we used crosstab. The statistical analysis was performed using SPSS software version 18.0 (IBM, Armonk, NY, USA). All *p*-values were two-sided, and a *p*<0.05 was considered statistically significant.

Results

Patient characteristics. A total of 463 consecutive patients underwent ^{18}F -FDG PET/CT followed by surgery for gastric cancer. Among them, 256 patients who were diagnosed as pathologic T1 were excluded from the study. After two patients were excluded due to lack of EBV ISH, a total 205 patients (146 males, 59 females) were enrolled. The patient group mean age was 63.1 ± 13.6 years. The patient characteristics are summarized in Table I.

Relationship between SUV_{max} and clinicopathologic characteristics. The mean of SUV_{max} was 7.2 ± 4.8 (median=5.5; range=1.7-26.0). Patients younger than 65 years showed significantly lower metabolic activity than those 65 years and older (*p*=0.005, Table II). Large tumors (≥ 6 cm) demonstrated significantly higher SUV_{max} than small tumors (<6 cm) (*p*<0.001). Tumor SUV_{max} was significantly increased according to depth of invasion (*p*=0.005). Papillary/tubular adenocarcinoma and poorly differentiated adenocarcinoma showed significantly higher metabolic activity than signet ring cell carcinoma or mucinous adenocarcinoma (*p*<0.001). There were no statistically significant differences in SUV_{max} according to gender, lymph node metastasis and tumor location.

Table I. Patients characteristics.

Characteristics	N (%)
No. of patients	205
Age (mean±SD)	63.1±13.6 years range, 22-90
Gender	
Male	146 (71.2%)
Female	59 (28.8%)
Depth of invasion	
pT2	40 (19.5%)
pT3	63 (30.7%)
pT4	102 (48.8%)
Lymph node metastasis	
pN0	55 (26.8%)
pN1	45 (22.0%)
pN2	40 (19.5%)
pN3	65 (31.7%)
Location	
Non-antral region	98 (47.8%)
Antral region	107 (52.2%)
Histology	
Papillary/tubular adenocarcinoma	66 (32.2%)
Poorly diff. adenocarcinoma	59 (28.8%)
Signet ring cell carcinoma	70 (34.1%)
Mucinous adenocarcinoma	8 (3.9%)

Table II. Relationship between SUV_{max} and clinicopathologic characteristics.

Variables	N	SUV _{max} (mean±SD)	p-Value
Age (years)			
<64	102	6.3±4.0	0.005
≥64	103	8.2±5.4	
Size			
<6 cm	106	5.8±3.4	0.000
≥6 cm	99	8.7±5.7	
Gender			
Male	146	7.3±4.7	0.618
Female	59	7.0±5.2	
Depth of invasion			
pT2/3	103	6.3±4.4	0.005
pT4	102	8.2±5.1	
Lymph node metastasis			
pN0/1	100	6.8±5.4	0.270
pN2/3	105	7.6±4.3	
Location			
Non-antral region	98	6.6±5.2	0.100
Antral region	107	7.7±4.4	
Histology			
Papillary/tubular adenocarcinoma	66	8.8±5.8	0.000
Poorly diff. adenocarcinoma	59	7.3±4.2	
SRC/MAC	78	5.6±3.7	

Relationship between EBV positivity and clinicopathologic characteristics. Fifteen out of 205 patients showed EBV positivity (7.3%). Gastric cancers with EBV positivity were more frequent in the higher metabolic group (SUV_{max} ≥5.5) than lower metabolic group (SUV_{max} <5.5) (13/103 vs. 2/102, *p*=0.006, Table III). EBV-positive gastric cancers showed significantly higher SUV_{max} than EBV-negative cancers (mean±SD, 9.9±4.2 vs. 7.0±4.8, *p*=0.026, Figure 1 and Table II). EBV positivity showed no significant correlation with age, gender, tumor size, depth of invasion, lymph node metastasis, or tumor location.

Discussion

EBV-associated gastric cancer type differs from other gastric cancers, exhibiting male predominance, non-antral anatomic subsites and better survival (6, 7, 17, 18). Our results showed that EBVaGC was significantly more frequent in the higher metabolic tumor group than the lower metabolic group. To our knowledge, this is the first study to analyze the association between EBV positivity and ¹⁸F-FDG uptake in patients with gastric cancer.

In our cohort, 13 of 146 (8.9%) males showed EBV positivity and 3.4% (2/59) of females were positive. The EBV positivity according to the location was 11.2% (11/87) in non-antral regions and 3.9% (4/103) in antral regions.

Table III. Relationship between EBV positivity and clinicopathologic characteristics.

Variables	N	EBV- (n=190)	EBV+ (n=15)	p-Value
Age (years)				
<64	102	97	5	0.283
≥64	103	93	10	
Size				
<6 cm	106	101	5	0.139
≥6 cm	99	89	10	
Gender				
Male	146	133	13	0.240
Female	59	57	2	
Depth of invasion				
pT2/3	103	96	7	0.773
pT4	102	94	8	
Lymph node metastasis				
pN0/1	100	94	6	0.480
pN2/3	105	96	9	
Location				
Non-antral region	98	87	11	0.058
Antral region	107	103	4	
SUV _{max}				
Low (<5.5)	102	100	2	0.006*
High (≥5.5)	103	90	13	
SUV _{max} (continu.)		7.0±4.8	9.9±4.2	0.026 [‡]

*Fisher's Exact Test; [‡]Independent samples T-test.

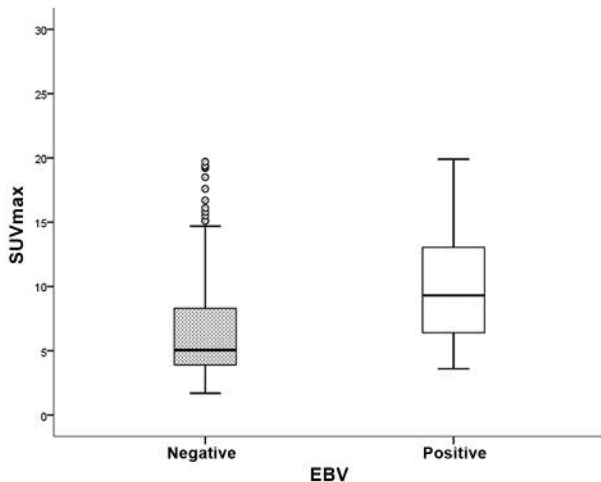


Figure 1. Box plots of the SUV_{max} from gastric cancers according to the EBV infection status.

These predominances are well-established from previous studies. However, there were no statistically significant differences in the current study, possibly because of the small number of EBV-positive patients.

The frequency of EBV positivity was statistically different in the two groups for SUV_{max} divided by median. EBVaGCs were more frequently observed in the higher metabolic group. The reason why EBVaGC was correlated with ^{18}F -FDG uptake is unknown. However, one possible explanation could be dysregulation of one or more metabolic signaling pathways. Previous studies have shown that *PIK3CA*, the gene encoding the catalytic subunit p110 of PI3K, is mutated in EBV-positive gastric cancer (2, 19). This genetic aberration results in dysregulation of the phosphatidylinositol-3 kinases (PI3K)/Akt/mammalian target of rapamycin (mTOR) signaling pathway (20). A study in lung cancer showed that FDG uptake was associated with the molecules relevant to this signaling pathway (21). Recently Zhang et al. provided evidence that EBV latent membrane protein 1 (LMP1) upregulated Glut-1 transcription to control aerobic glycolysis and tumorigenic growth of nasopharyngeal cancer cells through mTORC1/NF- κ B signaling (22).

Prominent inflammatory infiltration within the tumor is one of the distinct features of EBVaGC (23). These tumor-infiltrating cells are primarily lymphocytic, particularly CD8-positive or CD4-positive T cells accompanied by CD68-positive histiocytes (24-26). This feature reflects the immunogenicity of EBV, and this immune response by the host could be one reason for a better prognosis (18). The fact that increased ^{18}F -FDG uptake has been observed in metabolically-active inflammatory cells (27) could be one explanation for the relationship of ^{18}F -FDG uptake in

EBVaGC. A recent study presented the association between metabolic parameters on ^{18}F -FDG-PET and intra-tumor expression of immune-related markers in patients with non-small cell lung cancer (28).

Several previous studies have examined the correlation between ^{18}F -FDG uptake and histopathological features in patients with gastric cancer. Our results showed tumor size, depth of invasion and histologic types were related to tumor ^{18}F -FDG uptake, consistent with results from previous studies.

There existed several limitations in the current study. First, this study included a small number of patients. EBVaGC is a relatively rare type of gastric cancer and only 15 of 205 (7%) was EBV positive in our cohort. Further study with larger number of patients is needed to validate our findings. However, to our knowledge, this is the first study to evaluate the relationship between metabolic activity using ^{18}F -FDG PET/CT and EBV positivity. Second, we enrolled patients with T2 and more severe T stage after surgical resection. Therefore, it will be hard to generalize these findings to all stages of gastric cancer.

Previous studies showing the possibility of ^{18}F -FDG PET/CT as an imaging biomarker in stomach cancer patients have reported that patients with high FDG uptake generally have a poor prognosis (29). Our study showed that EBVaGC, which is known to have good prognosis, is associated with higher metabolic activity. To explain this finding, further studies are required to further analyze the information on tumor-infiltrating immune cells or gene mutations. Based on this association, molecular classification of gastric cancer would be considered when studying the role of PET as an imaging biomarker.

In conclusion, our preliminary findings showed that EBV positivity related to ^{18}F -FDG uptake and high ^{18}F -FDG activity was more frequent in patients with advanced gastric cancer. Further studies are needed to validate these findings in a larger patient study and clarify the relationship between EBV positivity and FDG uptake.

References

- Lerner MR, Andrews NC, Miller G and Steitz JA: Two small RNAs encoded by Epstein-Barr virus and complexed with protein are precipitated by antibodies from patients with systemic lupus erythematosus. *Proc Natl Acad Sci USA* 78: 805-809, 1981.
- Cancer Genome Atlas Research Network: Comprehensive molecular characterization of gastric adenocarcinoma. *Nature* 513: 202-209, 2014.
- Akiba S, Koriyama C, Herrera-Goepfert R and Eizuru Y: Epstein-Barr virus associated gastric carcinoma: epidemiological and clinicopathological features. *Cancer Sci* 99: 195-201, 2008.
- Wu MS, Shun CT, Wu CC, Hsu TY, Lin MT, Chang MC, Wang HP and Lin JT: Epstein-Barr virus-associated gastric carcinomas: relation to *H. pylori* infection and genetic alterations. *Gastroenterology* 118: 1031-1038, 2000.

- 5 Kang GH, Lee S, Kim WH, Lee HW, Kim JC, Rhyu MG and Ro JY: Epstein-barr virus-positive gastric carcinoma demonstrates frequent aberrant methylation of multiple genes and constitutes CpG island methylator phenotype-positive gastric carcinoma. *Am J Pathol* 160: 787-794, 2002.
- 6 Murphy G, Pfeiffer R, Camargo MC and Rabkin CS: Meta-analysis shows that prevalence of Epstein-Barr virus-positive gastric cancer differs based on sex and anatomic location. *Gastroenterology* 137: 824-833, 2009.
- 7 Camargo MC, Kim WH, Chiaravalli AM, Kim KM, Corvalan AH, Matsuo K, Yu J, Sung JJ, Herrera-Goepfert R, Meneses-Gonzalez F, Kijima Y, Natsugoe S, Liao LM, Lissowska J, Kim S, Hu N, Gonzalez CA, Yatabe Y, Koriyama C, Hewitt SM, Akiba S, Gulley ML, Taylor PR and Rabkin CS: Improved survival of gastric cancer with tumour Epstein-Barr virus positivity: an international pooled analysis. *Gut* 63: 236-243, 2014.
- 8 Mukai K, Ishida Y, Okajima K, Isozaki H, Morimoto T and Nishiyama S: Usefulness of preoperative FDG-PET for detection of gastric cancer. *Gastric Cancer* 9: 192-196, 2006.
- 9 Na SJ, o JH, Park JM, Lee HH, Lee SH, Song KY, Choi MG and Park CH: Prognostic value of metabolic parameters on preoperative ¹⁸F-fluorodeoxyglucose positron emission tomography/computed tomography in patients with stage III gastric cancer. *Oncotarget* 7: 63968-63980, 2016.
- 10 Kim J, Lim ST, Na CJ, Han YH, Kim CY, Jeong HJ and Sohn MH: Pretreatment F-18 FDG PET/CT Parameters to Evaluate Progression-Free Survival in Gastric Cancer. *Nucl Med Mol Imaging* 48: 33-40, 2014.
- 11 Lee JW, Lee SM, Lee MS and Shin HC: Role of (1)(8)F-FDG PET/CT in the prediction of gastric cancer recurrence after curative surgical resection. *Eur J Nucl Med Mol Imaging* 39: 1425-1434, 2012.
- 12 Alluri KC, Tahari AK, Wahl RL, Koch W, Chung CH and Subramaniam RM: Prognostic value of FDG PET metabolic tumor volume in human papillomavirus-positive stage III and IV oropharyngeal squamous cell carcinoma. *AJR Am J Roentgenol* 203: 897-903, 2014.
- 13 Choi MK, Choi JY, Lee J, Heo JS, Choi SH, Choi DW, Lee KT, Lee JK, Lee KH, Park JO, Park YS and Lim HY: Prognostic and predictive value of metabolic tumor volume on (18)F-FDG PET/CT in advanced biliary tract cancer treated with gemcitabine/oxaliplatin with or without erlotinib. *Med Oncol* 31: 23, 2014.
- 14 Lee JW, Kang CM, Choi HJ, Lee WJ, Song SY, Lee JH and Lee JD: Prognostic Value of Metabolic Tumor Volume and Total Lesion Glycolysis on Preoperative (1)(8)F-FDG PET/CT in Patients with Pancreatic Cancer. *J Nucl Med* 55: 898-904, 2014.
- 15 Sugano H, Nakamura K and Kato Y: Pathological studies of human gastric cancer. *Acta Pathol Jpn* 32(Suppl 2): 329-347, 1982.
- 16 Japanese classification of gastric carcinoma: 3rd English edition. *Gastric Cancer* 14: 101-112, 2011.
- 17 Camargo MC, Murphy G, Koriyama C, Pfeiffer RM, Kim WH, Herrera-Goepfert R, Corvalan AH, Carrascal E, Abdirad A, Anwar M, Hao Z, Kattoor J, Yoshiwara-Wakabayashi E, Eizuru Y, Rabkin CS and Akiba S: Determinants of Epstein-Barr virus-positive gastric cancer: an international pooled analysis. *Br J Cancer* 105: 38-43, 2011.
- 18 Liu X, Liu J, Qiu H, Kong P, Chen S, Li W, Zhan Y, Li Y, Chen Y, Zhou Z, Xu D and Sun X: Prognostic significance of Epstein-Barr virus infection in gastric cancer: a meta-analysis. *BMC Cancer* 15: 782, 2015.
- 19 Sukawa Y, Yamamoto H, Noshio K, Kunimoto H, Suzuki H, Adachi Y, Nakazawa M, Nobuoka T, Kawayama M, Mikami M, Matsuno T, Hasegawa T, Hirata K, Imai K and Shinomura Y: Alterations in the human epidermal growth factor receptor 2-phosphatidylinositol 3-kinase-v-Akt pathway in gastric cancer. *World J Gastroenterol* 18: 6577-6586, 2012.
- 20 Samuels Y, Wang Z, Bardelli A, Silliman N, Ptak J, Szabo S, Yan H, Gazdar A, Powell SM, Riggins GJ, Willson JK, Markowitz S, Kinzler KW, Vogelstein B and Velculescu VE: High frequency of mutations of the PIK3CA gene in human cancers. *Science* 304: 554, 2004.
- 21 Kaira K, Serizawa M, Koh Y, Takahashi T, Yamaguchi A, Hanaoka H, Oriuchi N, Endo M, Ohde Y, Nakajima T and Yamamoto N: Biological significance of ¹⁸F-FDG uptake on PET in patients with non-small-cell lung cancer. *Lung Cancer* 83: 197-204, 2014.
- 22 Zhang J, Jia L, Lin W, Yip YL, Lo KW, Lau VM, Zhu D, Tsang CM, Zhou Y, Deng W, Lung HL, Lung ML, Cheung LM and Tsao SW: Epstein-Barr Virus encoded Latent Membrane Protein-1 upregulates glucose transporter-1 transcription via the mTORC1/NF-kappaB signaling pathways. *J Virol* 91(6): pii: e02168-16, 2017.
- 23 Kawazoe A, Kuwata T, Kuboki Y, Shitara K, Nagatsuma AK, Aizawa M, Yoshino T, Doi T, Ohtsu A and Ochiai A: Clinicopathological features of programmed death ligand 1 expression with tumor-infiltrating lymphocyte, mismatch repair, and Epstein-Barr virus status in a large cohort of gastric cancer patients. *Gastric Cancer* 20: 407-415, 2017.
- 24 Fukayama M and Ushiku T: Epstein-Barr virus-associated gastric carcinoma. *Pathol Res Pract* 207: 529-537, 2011.
- 25 van Beek J, zur Hausen A, Snel SN, Berkhof J, Kranenbarg EK, van de Velde CJ, van den Brule AJ, Middeldorp JM, Meijer CJ and Bloemena E: Morphological evidence of an activated cytotoxic T-cell infiltrate in EBV-positive gastric carcinoma preventing lymph node metastases. *Am J Surg Pathol* 30: 59-65, 2006.
- 26 Kuzushima K, Nakamura S, Nakamura T, Yamamura Y, Yokoyama N, Fujita M, Kiyono T and Tsurumi T: Increased frequency of antigen-specific CD8(+) cytotoxic T lymphocytes infiltrating an Epstein-Barr virus-associated gastric carcinoma. *J Clin Invest* 104: 163-171, 1999.
- 27 Palsson-McDermott EM and O'Neill LA: The Warburg effect then and now: from cancer to inflammatory diseases. *Bioessays* 35: 965-973, 2013.
- 28 Lopci E, Toschi L, Grizzi F, Rahal D, Olivari L, Castino GF, Marchetti S, Cortese N, Qehajaj D, Pistillo D, Alloisio M, Roncalli M, Allavena P, Santoro A, Marchesi F and Chiti A: Correlation of metabolic information on FDG-PET with tissue expression of immune markers in patients with non-small cell lung cancer (NSCLC) who are candidates for upfront surgery. *Eur J Nucl Med Mol Imaging* 43: 1954-1961, 2016.
- 29 Wu Z, Zhao J, Gao P, Song Y, Sun J, Chen X, Ma B and Wang Z: Prognostic value of pretreatment standardized uptake value of F-18-fluorodeoxyglucose PET in patients with gastric cancer: a meta-analysis. *BMC Cancer* 17: 275, 2017.

Received March 22, 2017

Revised May 18, 2017

Accepted May 27, 2017