

# Tailoring the ‘Perfect Fit’ for Renal Transplant Recipients with End-stage Polycystic Kidney Disease: Indications and Timing of Native Nephrectomy

CHRYSOULA ARGYROU<sup>1</sup>, DEMETRIOS MORIS<sup>2</sup> and SPYRIDON VERNADAKIS<sup>1</sup>

<sup>1</sup>Transplantation Unit, Laikon General Hospital, Athens, Greece;

<sup>2</sup>Department of Surgery, The Ohio State University Comprehensive Cancer Center, The Ohio State University, Columbus, OH, U.S.A.

**Abstract.** *Background:* The ideal timing of native nephrectomy in relation to kidney transplantation in patients with autosomal-dominant polycystic kidney disease (ADPKD) can be a very puzzling decision for transplant surgeons and remains a matter of debate. This review article aims to present current literature regarding this highly controversial issue. *Materials and Methods:* The MEDLINE/PubMed database was searched using “polycystic kidney disease”, “renal/kidney transplantation” and “native nephrectomy” as key words. Our search was focused on the optimal timing of and indications for native nephrectomy in renal transplant recipients with ADPKD. *Results:* In symptomatic cases, pre-transplant unilateral or bilateral native nephrectomy seems appropriate, in order to alleviate symptoms. In cases that are provided with the option of living-donor transplantation, the performance of the simultaneous procedure could be of benefit. When the principal indication of native nephrectomy is the creation of space for the renal allograft, various studies highlight the safety of the simultaneous approach of either unilateral or bilateral nephrectomy. *Conclusion:* No consensus exists on the appropriate timing for native nephrectomy in patients with ADPKD. Several issues to be addressed in the decision-making process are the importance of residual diuresis, the longer

operative time along with the associated prolonged ischemia time and higher complication rate of the combined procedure.

Autosomal-dominant polycystic kidney disease (ADPKD) is the most common inherited kidney disease and a relatively common cause of end-stage renal disease (ESRD), representing around 10-15% of patients on dialysis (1, 2) and 9-10% of renal transplant recipients (3, 4). The multisystemic nature of the disease and the high rate of renal-related complications cause significant morbidity and substantially interfere with the quality of life of affected individuals (4, 5). It has been estimated that approximately 50% of patients with ADPKD present ESRD by 60 years of age (2).

Management of ADPKD is mostly directed towards the alleviation of symptoms rather than changing the course of disease or slowing cyst formation (6). Conservative treatment for patients with ADPKD involves treatment of hypertension, chronic pain and cyst infection (6, 7). Newer treatments, however, target the underlying pathophysiological mechanisms of the disease, which involve key signaling pathways such as those regulating intracellular Ca<sup>2+</sup> and cAMP levels (8). Somatostatin analogs, mammalian target of rapamycin inhibitors and vasopressin-2 receptor antagonists represent drugs that target these mechanisms. However, surgical intervention is frequently required in order to deal with renal-related complications. Native nephrectomy (NN) is considered when patients suffer from recurrent urinary tract infections, hematuria, chronic pain refractory to conservative treatment, and when there is a need for gaining space for future or upcoming renal transplantation.

The ideal timing of NN in relation to kidney transplantation can be a very puzzling decision for transplant surgeons and remains a matter of debate. This review article aims to present and critically analyze current literature regarding this highly controversial issue.

This article is freely accessible online.

Correspondence to: Demetrios Moris, MD, MSc, PhD, MACS, Department of Surgery, The Ohio State University Comprehensive Cancer Center, The Ohio State University, Columbus, OH 43210, U.S.A. Tel: +1 2164442574, Fax: +12164454658, e-mail: dimmoris@yahoo.com

**Key Words:** End-stage polycystic kidney, renal transplantation, nephrectomy, review.

## Materials and Methods

The MEDLINE/PubMed database was searched using “polycystic kidney disease”, “renal/kidney transplantation” and “native nephrectomy” as key words. Three independent reviewers (C.A, D.M and S.V) performed the literature search, the study selection and the data extraction. All the references from the identified articles were searched for relevant information. The end date of the literature search was set to September 1st 2016. Our search was focused on the latest published information regarding the optimal timing and indications of NN in renal transplant recipients with ADPKD.

## Results

Fuller *et al.* performed a retrospective study that compared the outcomes of pre-transplant (group 1), simultaneous (group 2) and post-transplant (group 3) NN in patients with ADPKD (9). All three groups showed similar results in terms of the safety and success of the procedure. The estimated blood loss and the duration of hospitalization were not statistically significant among the three groups, despite the fact that operative time was longer in group 2. The authors emphasized the need to preserve residual renal diuresis thus avoiding bilateral nephrectomy before renal transplantation. The decision for concomitant nephrectomy was mostly made upon the need of space for the renal allograft.

Rozanski *et al.* reviewed 73 deceased donor renal transplantations in patients with ADPKD that underwent unilateral NN (group 1) or renal transplantation alone (group 2) (10). Although the analysis of their results showed no significant difference between the two groups, the authors suggest that unilateral nephrectomy should be individualized rather than considered as a standard procedure.

Nunes *et al.* performed a retrospective analysis of 159 living and deceased donor renal transplantations in individuals with ADPKD (11). They compared the results of renal transplant recipients that underwent unilateral NN due to enlarged kidneys (group 1, n=143) and those in whom this procedure was not necessary (group 2, n=16). Although the operative time was longer and the need for blood transfusion was greater in the first group, there were no significant differences regarding the overall complication rate and graft function after 5 years (mean follow-up was 8.53 years for group 1 and 6.36 years for group 2). Their results enabled them to draw the conclusion that when performed for the creation of space for a renal allograft, simultaneous nephrectomy can be safely performed in both living and deceased donor procedures and there is no need for nephrectomy to be performed before renal transplantation.

Wagner *et al.* reviewed the records of 39 living-donor renal transplantations performed at their institution in patients with ADPKD (12). Bilateral nephrectomy, either prior or concurrent with renal transplantation, was required

in 32 patients (concurrent in 17 and staged in 15 patients). By analyzing their outcomes, the authors were able to develop an algorithm regarding the management of patients with ADPKD. According to this algorithm, bilateral nephrectomy should be performed in symptomatic cases, either before renal transplantation (if there is not a living donor) or simultaneously (if there is living donor).

Cohen *et al.*, after examining the data of 41 NNs in patients with ADPKD, 88% of which were performed during the pre-transplant period, suggested that NN should be performed mainly when there is a space problem and not systematically (13).

A retrospective study by Kramer *et al.* evaluated the outcomes of 20 live-donor renal transplant procedures with simultaneous bilateral removal of recipients' polycystic kidneys (14). Complications, although rare, included wound dehiscence, adrenal insufficiency and liver laceration. They concluded that this combined procedure is safe and successful, with minimal morbidity, and graft and patient survival of 100% during their 5-year follow-up. They also compared their results with those of Glassman *et al.* in a study that was performed by their center 7 years earlier (15). This comparison showed that there was a marked decrease in the need for blood transfusion in the combined procedure. Of note, the study of Glassman *et al.* also highlights that patient satisfaction with the combined procedure was high (70%) and that patients for the no-nephrectomy and staged procedure group strongly desired to have been provided with that option (15).

Sulikowski *et al.*, after observing 50 ADPKD renal transplant recipients divided into three groups as described in Table I, concluded that unilateral nephrectomy is an appropriate preliminary treatment that can be performed safely in order to prepare patients for renal transplantation (16). Their observation that 42.9% of cases without pre-transplant NN developed complications that led to post-transplant nephrectomy also support the notion that bilateral nephrectomy might also be wise.

Furthermore, Patel *et al.* retrospectively examined 157 kidney transplants, regarding both living and deceased donors, performed between 1988 and 2008 in patients with ADPKD at a single center (17). Interestingly, only 31 patients had to undergo NN (20% of their series), the majority of which were bilateral and post-transplant. According to their analysis, they suggest that NN should not be routinely indicated in renal transplant recipients with ADPKD, but rather it should be reserved for those suffering recurrent UTIs and pain.

Another, although smaller, retrospective study was performed by Kirkman *et al.* (18). Patients with ADPKD were divided into many groups and both unilateral and bilateral NNs were performed in the pre-transplant and post-transplant period. They also used the 'sandwich' technique, meaning that the first nephrectomy (of the most affected kidney) was performed before renal transplantation and the

Table I. Summary of selected studies performed on renal transplant recipients with autosomal-dominant polycystic kidney disease regarding native nephrectomy.

Study	Native nephrectomy						Major complications
	Group (N)	Bilateral	Unilateral	Pre-transplant	Simultaneous	Post-transplant	
Glassman <i>et al.</i> (15)	1 (10) 2 (9) 3 (4)	+		None	+		
Fuller <i>et al.</i> (9)	1 (7) 2 (16) 3 (9)	+	Either	+	+		Wound dehiscence Abdominal bleeding
Rozanski <i>et al.</i> (10)	1 (30) 2 (43)		+	+			Death (septicemia)
Nunes <i>et al.</i> (11)	1 (143) 2 (16)		+	None	+		Ureteral stenosis
Wagner (12)	1 (15) 2 (17)	+		+	+		Splenectomy
Cohen <i>et al.</i> (13)	1 (36) 2 (3)		+	+		+	
Kramer <i>et al.</i> (14)	20	+			+		Wound dehiscence Liver laceration Adrenal insufficiency
Sulikowski <i>et al.</i> (16)	1 (25) 2 (4) 3 (21)	+(n=3)	+(n=22)	+			Hemorrhage, wound infection, splenectomy Wound infection Cyst infection
Patel <i>et al.</i> (17)	157 (total)	+(n=28)	+(n=3)	+(n=10)	+(n=1)	+(n=20)	Hemorrhage Hemorrhage
Kirkman <i>et al.</i> (18)	1 (20) 2 (12) 3 (3)	+(n=10)	+(n=10)	+		+	Transient renal graft dysfunction -
Neeff <i>et al.</i> (3)	100		+	'Sandwich' technique	+		Wound dehiscence, hemorrhage, lymphocele Blood transfusion
Chebib <i>et al.</i> (19)	1 (35) 2 (79)	+		+		+	Ileus
Ahmad <i>et al.</i> (20)	1 (66) 2 (52)	+	+(n=1)		+		Splenectomy, liver laceration, hemorrhage
				No nephrectomy			

second in the post-transplant period. However, this group sample was small (n=3) and no safe conclusions can be drawn, despite the lack of adverse effects. Overall, the authors conclude that the wiser intervention appears to be post-transplant unilateral nephrectomy.

On the other hand, Neeff *et al.* were the first to report a case series of 100 patients with ADPKD undergoing renal transplantation with ipsilateral nephrectomy as a standard procedure (3). Right-sided nephrectomy and renal allograft placement was performed unless there was a symptomatic left kidney. Operative time was found to be extended by less than 1 h, in contrast to bilateral nephrectomy performed by transperitoneal incision, which added about 160-190 min according to other studies (9, 14). According to the authors' experience this approach can be safely performed without endangering patient or graft survival.

In a study undertaken by Chebib *et al.*, among the 470 renal transplant recipients with ADPKD, 24.3% underwent nephrectomy (19), a percentage similar to that of Patel *et al.* (17). The general approach of these investigators was to avoid concomitant or bilateral nephrectomy, due to concerns regarding morbidity and graft survival. They chose to remove symptomatic kidneys, either before or after kidney transplantation. They noted that post-transplant nephrectomy, which was more common in their series (n=79 post-transplant vs. n=35 pre-transplant), is a safe procedure that can be done without jeopardizing the graft and with a lower complication rate than pre-transplant nephrectomy. The authors also focused on the surgical technique, and suggested that the laparoscopic approach should be used when the size of the polycystic kidney allows this.

Table II. Indications of native nephrectomy Autosomal dominant polycystic kidney disease in various studies.

Study	Indication for native nephrectomy					
	Lack of space	Pain	UTI	Hematuria	Renal mass	Digestive symptoms
Fuller <i>et al.</i> (9)	+	+	+	+	+	+
Nunes <i>et al.</i> (11)	+					
Wagner <i>et al.</i> (12)	+	+	+	+		+
Cohen <i>et al.</i> (13)	+		+		+	
Kramer <i>et al.</i> (14)		+	+			+
Sulikowski <i>et al.</i> (16)	+	+	+	+		
Patel <i>et al.</i> (17)	+	+	+	+	+	
Kirkman <i>et al.</i> (18)	+	+	+	+		+
Chebib <i>et al.</i> (19)	+	+	+	+	+	+
Ahmad <i>et al.</i> (20)	+	+	+	+		+

UTI: Urinary tract disease.

Finally, Ahmad *et al.* compared the combined procedure of NN and renal transplantation to renal transplantation alone, and found that in symptomatic patients with ADPKD, the combined procedure is advantageous (20). Moreover, patient satisfaction was also evaluated and found to be superior for individuals who underwent the combined procedure, despite the increased incidence of intraoperative complications.

## Discussion

An effort was made to present the great majority of studies about NNs performed in transplant recipients with ADPKD. The retrospective nature of the existing data and the fact that the design of each study is rather variable makes drawing definitive conclusions rather challenging. Each study was created based on the authors' experience and the parameters that they chose to investigate. Table I presents the various studies performed and the procedures they followed, as well as the major complications observed and Table II summarizes the main indications for NN in these studies.

According to current literature, in symptomatic cases, pre-transplant unilateral or bilateral NN seems appropriate in order to alleviate symptoms that interfere with patients' daily lives (10, 16, 21, 22). Nonetheless, since it has been established that renal transplantation is the treatment of choice for ESRD and that longer dialysis time negatively impacts survival of both patients and graft, it is important to perform renal transplantation as early as possible (23, 24). In cases that are provided with the option of living-donor transplantation, the performance of the simultaneous procedure could be of benefit (3, 9, 11-13, 25).

Moreover, when the principal indication for NN is the creation of space for the renal allograft, various studies highlight the safety of the simultaneous approach of either unilateral or bilateral nephrectomy (3, 9, 11-13, 25). This

Table III. Authors' conclusions in various studies regarding the optimum timing of native nephrectomy in renal transplant recipients with autosomal dominant polycystic kidney disease.

Study	Timing of native nephrectomy		
	Pre-transplant	Simultaneous	Post-transplant
Brazda <i>et al.</i> (21)	+		
Fuller <i>et al.</i> (9)		+	
Rozanski <i>et al.</i> (10)	+		
Nunes <i>et al.</i> (11)		+	
Wagner <i>et al.</i> (12)		+	
Sulikowski <i>et al.</i> (16)	+		
Patel <i>et al.</i> (17)			+
Kirkman <i>et al.</i> (18)			+
Neeff <i>et al.</i> (3)		+	
Chebib <i>et al.</i> (19)			+
Ahmad <i>et al.</i> (20)		+	

approach is also advantageous as it does not impair graft or patient survival and spares the need for separate pre-transplant removal of the native kidney, with all the dangers and post-operative complications that any procedure carries. Furthermore, it enables transplantation to be pre-emptive, especially in the context of a well-planned living-donor transplantation (3, 9, 11, 13). Another parameter that should be taken into account is the degree of patient satisfaction. In studies that evaluated patient satisfaction, it seems that this combined approach is more desirable and that individuals who underwent renal transplantation alone would like to have been provided with the option of the combined approach, despite the fact that the complication rate is higher (14, 20).

On the other hand, there are many authors who hold that it is wise to avoid any pre-transplant or simultaneous procedures (17, 18). According to the retrospective analysis of these studies' outcomes, the estimated percentage of the patients with

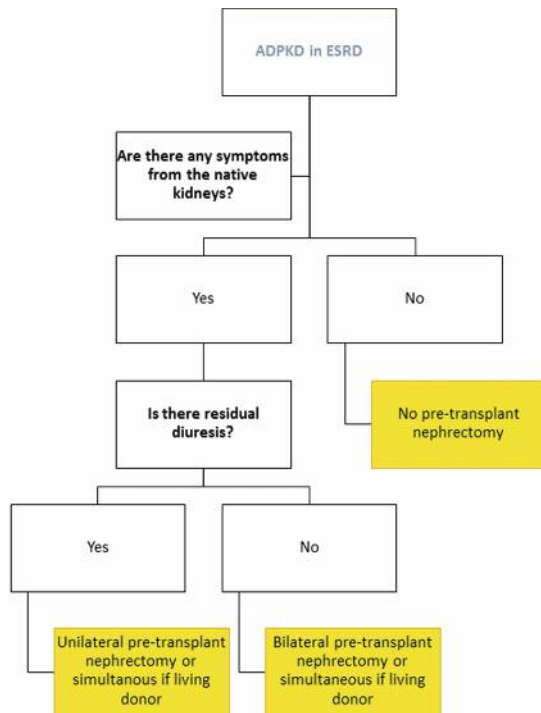


Figure 1. Algorithm of management of native nephrectomy in renal transplant recipients with autosomal-dominant polycystic kidney disease (ADPKD). ESRD: End-stage renal disease.

ADPKD that needed NN was relatively low (around 20%) and the majority of complications that led to NN occurred during the post-transplant period (11, 15-17). This evidence indicates that there may be no need to burden patients with an extra procedure either prior to or concomitant with renal transplantation, except in symptomatic cases (10, 21).

The selection of appropriate surgical technique is also a matter of controversy, with the laparoscopic and hand-assisted approach gradually gaining more ground. Although technically challenging, a great number of studies, including a recent meta-analysis, indicated that laparoscopic nephrectomy, especially hand-assisted bilateral nephrectomy, is both safe and efficacious even for massively enlarged kidneys (19, 25-34).

Finally, as it is illustrated in Table III, no consensus exists about the appropriate timing for NN in patients with ADPKD. Therefore, a proposed algorithm is presented in Figure 1 that could be of assistance during decision making. Several issues that need to be addressed in the decision-making process are the importance of residual diuresis, the longer operative time with the associated prolonged ischemia time, and higher complication rate of the combined procedure, as well as the potential complications of the remaining kidney in cases when the unilateral approach is used.

## Conclusion

Overall, we meticulously analyzed the majority of the studies regarding NN in renal recipients with ADPKD. However, this literature review has inherent limitations, as the design of the existing studies is variable and there is great difficulty in the comparison of the associated outcomes. The lack of randomized controlled trials and studies that evaluate comparable parameters make the extraction of solid conclusions rather challenging and the decision of the appropriate timing and procedure should be individualized.

## Conflicts of Interest

The Authors declare that they have no conflict of interest in regard to this study.

## Ethical Approval

This article does not refer to any studies with human participants or animals performed by any of the Authors.

## References

- 1 Badani KK, Hemal AK and Menon M: Autosomal dominant polycystic kidney disease and pain – a review of the disease from aetiology, evaluation, past surgical treatment options to current practice. *J Postgrad Med* 50(3): 222-226, 2004.
- 2 Torres VE, Harris PC and Pirson Y: Autosomal dominant polycystic kidney disease. *Lancet* 369(9569): 1287-1301, 2007.
- 3 Neeff HP, Pisarski P, Tittelbach-Helmrich D, Karajanev K, Neumann HP, Hopt UT and Drognitz O: One hundred consecutive kidney transplantations with simultaneous ipsilateral nephrectomy in patients with autosomal dominant polycystic kidney disease. *Nephrol Dial Transplant* 28(2): 466-471, 2013.
- 4 Jacquet A, Pallet N, Kessler M, Hourmant M, Garrigue V, Rostaing L, Kreis H, Legendre C and Mamzer-Bruneel MF: Outcomes of renal transplantation in patients with autosomal dominant polycystic kidney disease: A nationwide longitudinal study. *Transpl Int* 24(6): 582-587, 2011.
- 5 Hadimeri H, Norden G, Friman S and Nyberg G: Autosomal dominant polycystic kidney disease in a kidney transplant population. *Nephrol Dial Transplant* 12(7): 1431-1436, 1997.
- 6 Akoh JA: Current management of autosomal dominant polycystic kidney disease. *World J Nephrol* 4(4): 468-479, 2015.
- 7 Casteleijn NF, Visser FW, Drenth JP, Gevers TJ, Groen GJ, Hogan MC and Gansevoort RT: A stepwise approach for effective management of chronic pain in autosomal-dominant polycystic kidney disease. *Nephrol Dial Transplant* 29(Suppl 4): iv142-153, 2014.
- 8 Chang MY and Ong AC: Mechanism-based therapeutics for autosomal dominant polycystic kidney disease: Recent progress and future prospects. *Nephron Clin Pract* 120(1): c25-34, 2012.
- 9 Fuller TF, Brennan TV, Feng S, Kang SM, Stock PG and Freise CE: End-stage polycystic kidney disease: Indications and timing of native nephrectomy relative to kidney transplantation. *J Urol* 174(6): 2284-2288, 2005.

- 10 Rozanski J, Kozłowska I, Myslak M, Domanski L, Sienko J, Ciechanowski K and Ostrowski M: Pretransplant nephrectomy in patients with autosomal dominant polycystic kidney disease. *Transplant Proc* 37(2): 666-668, 2005.
- 11 Nunes P, Mota A, Alves R, Figueiredo A, Parada B, Macario F and Rolo F: Simultaneous renal transplantation and native nephrectomy in patients with autosomal-dominant polycystic kidney disease. *Transplant Proc* 39(8): 2483-2485, 2007.
- 12 Wagner MD, Prather JC and Barry JM: Selective, concurrent bilateral nephrectomies at renal transplantation for autosomal dominant polycystic kidney disease. *J Urol* 177(6): 2250-2254, 2007.
- 13 Cohen D, Timsit MO, Chretien Y, Thiounn N, Vassiliu V, Mamzer MF, Legendre C and Mejean A: Place of nephrectomy in patients with autosomal dominant polycystic kidney disease waiting for renal transplantation. *Prog Urol* 18(10): 642-649, 2008.
- 14 Kramer A, Sausville J, Haririan A, Bartlett S, Cooper M and Phelan M: Simultaneous bilateral native nephrectomy and living donor renal transplantation are successful for polycystic kidney disease: The University of Maryland experience. *J Urol* 181(2): 724-728, 2009.
- 15 Glassman DT, Nipkow L, Bartlett ST and Jacobs SC: Bilateral nephrectomy with concomitant renal graft transplantation for autosomal dominant polycystic kidney disease. *J Urol* 164(3 Pt 1): 661-664, 2000.
- 16 Sulikowski T, Tejchman K, Zietek Z, Rozanski J, Domanski L, Kaminski M, Sienko J, Romanowski M, Nowacki M, Pabisiak K, Kaczmarczyk M, Ciechanowski K, Ciechanowicz A and Ostrowski M: Experience with autosomal dominant polycystic kidney disease in patients before and after renal transplantation: A 7-year observation. *Transplant Proc* 41(1): 177-180, 2009.
- 17 Patel P, Horsfield C, Compton F, Taylor J, Koffman G and Olsburgh J: Native nephrectomy in transplant patients with autosomal dominant polycystic kidney disease. *Ann R Coll Surg Engl* 93(5): 391-395, 2011.
- 18 Kirkman MA, van Dellen D, Mehra S, Campbell BA, Tavakoli A, Pararajasingam R, Parrott NR, Riad HN, McWilliam L and Augustine T: Native nephrectomy for autosomal dominant polycystic kidney disease: Before or after kidney transplantation? *BJU Int* 108(4): 590-594, 2011.
- 19 Chebib FT, Prieto M, Jung Y, Irazabal MV, Kremers WK, Dean PG, Rea DJ, Cosio FG, Torres VE and El-Zoghby ZM: Native nephrectomy in renal transplant recipients with autosomal dominant polycystic kidney disease. *Transplant Direct* 1(10): e43, 2015.
- 20 Ahmad SB, Inouye B, Phelan MS, Kramer AC, Sulek J, Weir MR, Barth RN, LaMattina JC, Schweitzer EJ, Leiser DB, Niederhaus SV, Bartlett ST and Bromberg JS: Live-donor renal transplant with simultaneous bilateral nephrectomy for autosomal dominant polycystic kidney disease is feasible and satisfactory at long-term follow-up. *Transplantation* 100(2): 407-415, 2016.
- 21 Brazda E, Ofner D, Riedmann B, Spechtenhauser B and Margreiter R: The effect of nephrectomy on the outcome of renal transplantation in patients with polycystic kidney disease. *Ann Transplant* 1(2): 15-18, 1996.
- 22 Schillinger F, Montagnac R, Jourdan AL, Massia D, Brandt B, Toupance O and Chanard J: Bilateral nephrectomy before renal transplantation in autosomal dominant polycystic renal disease. *Nephrologie* 18(5): 181-186, 1997.
- 23 Meier-Kriesche HU and Kaplan B: Waiting time on dialysis as the strongest modifiable risk factor for renal transplant outcomes: A paired donor kidney analysis. *Transplantation* 74(10): 1377-1381, 2002.
- 24 Abecassis M, Bartlett ST, Collins AJ, Davis CL, Delmonico FL, Friedewald JJ, Hays R, Howard A, Jones E, Leichtman AB, Merion RM, Metzger RA, Pradel F, Schweitzer EJ, Velez RL and Gaston RS: Kidney transplantation as primary therapy for end-stage renal disease: A National Kidney Foundation/Kidney Disease Outcomes Quality Initiative (NKF/KDOQIM) conference. *Clin J Am Soc Nephrol* 3(2): 471-480, 2008.
- 25 Lucas SM, Mofunanya TC, Goggins WC and Sundaram CP: Staged nephrectomy versus bilateral laparoscopic nephrectomy in patients with autosomal dominant polycystic kidney disease. *J Urol* 184(5): 2054-2059, 2010.
- 26 Whitten MG, Van der Werf W and Belnap L: A novel approach to bilateral hand-assisted laparoscopic nephrectomy for autosomal dominant polycystic kidney disease. *Surg Endosc* 20(4): 679-684, 2006.
- 27 Eng M, Jones CM, Cannon RM and Marvin MR: Hand-assisted laparoscopic nephrectomy for polycystic kidney disease. *J Urol* 177(2): 279-284, 2013.
- 28 Lipke MC, Bargman V, Milgrom M and Sundaram CP: Limitations of laparoscopy for bilateral nephrectomy for autosomal dominant polycystic kidney disease. *J Urol* 177(2): 627-631, 2007.
- 29 Lee DI and Clayman RV: Hand-assisted laparoscopic nephrectomy in autosomal dominant polycystic kidney disease. *J Endourol* 18(4): 379-382, 2004.
- 30 Rehman J, Landman J, Andreoni C, McDougall EM and Clayman RV: Laparoscopic bilateral hand assisted nephrectomy for autosomal dominant polycystic kidney disease: Initial experience. *J Urol* 166(1): 42-47, 2001.
- 31 Guo P, Xu W, Li H, Ren T, Ni S and Ren M: Laparoscopic nephrectomy versus open nephrectomy for patients with autosomal dominant polycystic kidney disease: A systematic review and meta-analysis. *PLoS One* 10(6): e0129317, 2015.
- 32 Dengu F, Azhar B, Patel S and Hakim N: Bilateral nephrectomy for autosomal dominant polycystic kidney disease and timing of kidney transplant: A review of the technical advances in surgical management of autosomal dominant polycystic disease. *Exp Clin Transplant* 13(3): 209-213, 2015.
- 33 Mak DKC, Ilie CP, Abedin A, Gommersall L, Luscombe C and Golash A: Bilateral hand-assisted laparoscopic nephrectomy in adult polycystic kidney disease patients: A uk centre experience. *J Med Life* 5(2): 226-231, 2012.
- 34 Ismail HR, Flechner SM, Kaouk JH, Derweesh IH, Gill IS, Modlin C, Goldfarb D and Novick AC: Simultaneous vs. sequential laparoscopic bilateral native nephrectomy and renal transplantation. *Transplantation* 80(8): 1124-1127, 2005.

*Received February 15, 2017*  
*Revised March 20, 2017*  
*Accepted March 22, 2017*