

Development of Critical-size Abdominal Defects in a Rabbit Model to Mimic Mature Ventral Hernias

GEORGIOS HILAS, MICHAEL SCOTT TAYLOR and JOEL CORBETT

Poly-Med, Inc., Anderson, SC, U.S.A.

Abstract. *Background/Aim: Mesh hernioplasty is one of the most frequently performed procedures in the United States. Abdominal rigidity and chronic inflammation, among other factors, contribute to long-term complications including chronic pain, abdominal wall stiffness and fibrosis. Acute models do not replicate the chronic environment associated with most hernias, limiting the ability to improve products. The present study details development of a critical-size defect in rabbit abdominal wall for maturation into a chronic hernia to enable analysis of hernia repair devices in a realistic environment. Materials and Methods: New Zealand White Rabbits were used to assess defect creation and mature hernia development through a period of 21-35 days. Results and Conclusion: Through this study, a critical-size defect was developed based on 3-cm full-thickness incision through musculature and peritoneum followed by simple skin closure and wound maturation, which was identified as a reliable procedure for creating defects presenting typical aspects of mature hernias including hernia ring and adhesions.*

Investigation of new biomaterials and devices often requires testing in animals to show the potential safety and efficacy of the device in a living model. The applicability of the animal model used is of utmost importance as it must, as closely as possible, mimic the human condition. This allows researchers to discover potential adverse reactions to the device prior to testing in a human clinical setting as well as verify that design criteria used in development are appropriate for the intended application, which can also be considered "Design Validation" in subsequent FDA submission documents. As hernia repair is one of the most common surgical procedures performed (1), development

and use of a hernia model that accurately replicates the wound pathology associated with mature hernias in humans is very important in studying new device design, as this has the potential of affecting a large number of patients.

An acute hernia defect creation animal model is typically employed in the study of new hernia mesh products as this procedure is well documented in the literature (2-17), and minimizes, as much as possible, the amount of variability seen from animal to animal, and is economical as hernia creation and repair procedures are all performed in a single surgery. Typical species used for this evaluation include goat, pig, rabbit, and rat, with lessening correlation to human repair with smaller species but a greater ability to populate larger studies. In a typical procedure of this type, a small section of the abdominal wall is resected (including muscle and peritoneal layers) in order to create a hernia defect. This way, the created hernias from animal to animal are nearly identical as they are completely generated in the surgical procedure typically using some sort of template to aid in repeatability. Immediately following hernia defect creation, the surgical mesh of interest is used to repair the hernia by either using an on-lay approach, where the mesh is simply sutured over the defect site, or by suturing the mesh directly to the facial edges of the created wound. At pre-determined time points the animal is euthanized and mesh is explanted for analysis of mesh performance.

A model with potentially higher clinical relevance involves creating a defect in the abdominal wall through a primary hernia creation surgery. The created defect is allowed to mature resulting in the formation of a distinct hernia ring and sack with many of the complications and challenges seen in the clinical setting. This type of hernia maturation is typically seen in humans wherein the hernia develops over a period of weeks to months before successful identification and repair. A number of mature ventral hernia models have been reported in the literature including rat (18-20), rabbit (21, 22), and porcine (23) models with various procedures for creating the mature defect in the abdominal wall. In the procedure first reported by DuBay and colleagues, a 5-cm full-thickness incision is created in the abdominal wall of Sprague-Dawley rats (18). The created defect is temporarily repaired using a

Correspondence to: M. Scott Taylor, 51 Technology Drive, Anderson, SC, 29625, U.S.A. Tel: +1 8643280008, e-mail: scott.taylor@poly-med.com

Key Words: Hernia, animal model, critical size defect.

rapidly absorbing suture (5-0 Plain Catgut). Since the suture fails prior to the development of adequate tensile strength to prevent wound dehiscence, a ventral hernia forms within 1 to 2 weeks. In another approach, the peritoneum is left completely intact and a small portion of the abdominal wall musculature is either compromised or excised in the location desired for hernia creation. Two such procedures have been successfully performed and described in a porcine (23) and rabbit (22) animal model. In the reported porcine model, a simple 5 cm incision is made through the muscle layers taking special care not to disrupt the peritoneal layer. With the muscle layers compromised, the skin is sutured closed over top and the defect is allowed to mature into a ventral hernia over a period of 3 weeks. Through this procedure, the abdominal wall musculature is completely preserved and simply cutting through the muscle layers was shown to result in hernia development. Alternatively, in the reported rabbit model an area of the muscle must be completely resected in order to result in hernia development (22). In this procedure, a 3×1 cm metal frame was used as a guide to remove a 3-cm² section of the abdominal wall musculature, while preserving the peritoneum, located longitudinally along the *linea alba* on the umbilicus scar. The skin was closed over the created defect and allowed to mature over a period of 21 days. With this procedure the authors reported formation of a stable ventral hernia in all animals with the presence of a hernia ring, sac, and visceral and/or omental adhesions. It was also noted that attempts at removing smaller areas of the abdominal wall muscle (2 cm² area) did not promote reliable hernia formation while removal of larger areas of the abdominal wall musculature (≥4 cm² area) was associated with high rates of complication (skin dehiscence and posterior wound infection). A third and possibly more reliable procedure is reported by Minossi that involves simply making a 4-cm full-thickness incision (through the muscle and peritoneal layers) approximately 10 to 12 cm below the xiphoid process (21). Unlike the previous procedure reported by DuBay where the created incision is temporarily repaired using catgut suture, the incision through the abdominal wall was left open as the skin was closed. The created defect was allowed to mature for a period of 30 days resulting in an incisional hernia.

In the present study, various approaches in creating a chronic ventral hernia model in New Zealand White (NZW) rabbits were examined. The goal of this work was to develop a critical size defect initially based on previously reported methodology (22) which develops into the wound pathology associated with mature hernias in humans for further application in hernia repair studies.

Materials and Methods

Study compliance. The Institutional Animal Care and Use Committee (IACUC) of Godley-Snell Research Center at Clemson

University (Clemson, SC, USA), where the study was conducted, approved the experimental protocol prior to the start of the study, and standard operating procedures were followed at all times. Godley-Snell Research Center is an AAALAC-accredited facility, and animals were maintained in accordance with all animal welfare regulations and federal guidelines to ensure humane care.

Animal description. A total of 30 female New Zealand White rabbits of at least 5 to 6 months of age at the time of initial surgery were used to develop the critical defect model. This age range was selected to ensure that the animals are sufficiently aged to minimize growth post-surgery, which would have led to mesh complications and confound results.

General surgical procedures. Prior to surgery each animal received 1.1 mg/kg acepromazine, 33 mg/kg ketamine HCL, 0.02–0.05 mg/kg atropine, and 0.05 mg/kg buprenorphine as pre-anesthetics. During each surgery 1-4% isoflurane in oxygen was used to maintain anesthesia.

Defects were created near the abdominal midline, using the xiphoid process and *linea alba* to identify defect position, with site locations detailed in Figure 1. Initial incisions of approximately 4 cm were created through the skin and subcutaneous fat, followed by blunt dissection to isolate a workable subcutaneous surgical space. Defects were created as detailed below, followed by surgical closure using 3-0 PDS™ suture (Ethicon, Inc., Somerville, NJ, USA) and a light application of Tissumend™ II (Veterinary Product Laboratories, Phoenix, AZ, USA) absorbable tissue adhesive to aid in wound closure and provide a physical barrier for potential contamination.

Hernia creation procedure A (HCP-A)–pilot animal no. 1. Starting 2 cm below the xiphoid process a midline incision measuring approximately 4 cm was created through the skin and subcutaneous fat. Blunt dissection was performed around the incision to create a workable subcutaneous surgical space. Approximately 3 cm below the xiphoid process and centered along the *linea alba* a 3 × 1 cm section of the abdominal wall musculature was excised while taking special care to leave the peritoneum intact. The abdominal wall defect was allowed to mature for 36 days, at which point the animal was euthanized and examined for the development of a mature ventral hernia.

HCP-B–pilot animal no. 2. Approximately 13 cm below the xiphoid process and 2 cm away from the *linea alba* (lower left side of abdomen) a 4 cm incision was created through the skin and subcutaneous fat. Blunt dissection was performed to create a workable subcutaneous surgical space. A 3×1 cm section of the abdominal wall musculature was excised, leaving the peritoneum intact. A 2-cm incision was then created through the peritoneum while being careful not to damage any of the inter-abdominal contents. Two knots of Vicryl™ 2-0 (polygalactin 910, Ethicon, Inc. Somerville, NJ, USA) suture were placed 0.5 cm in on each side of the incision going into the peritoneum in order to prevent viscera from pushing directly into the subcutaneous space. The created abdominal wall defect was allowed to mature for 35 days, at which point the animal was euthanized and examined for hernia creation.

HCP-C–pilot animal no. 3. Approximately 13 cm below the xiphoid process and 2 cm away from the *linea alba* (lower left side of

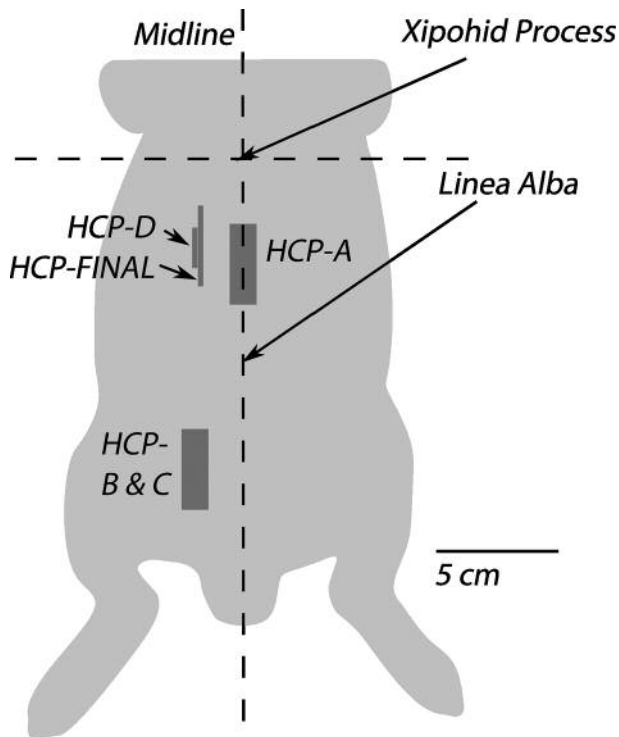


Figure 1. Site location of defects created during the development of a critical size abdominal wall defect.

abdomen) a 3×1 cm section of the abdominal wall musculature was excised and a 3 cm incision through the peritoneum was created. Skin closure over the created defect was accomplished as previously described. Animal was euthanized 10 days following creation surgery as humane endpoints were reached prior to the planned conclusion date. This included lack of appetite, weight loss of greater than 10%, and a lack of urination which indicated a possible entrapment of the bladder in the created hernia.

HCP-D—pilot animal no. 4. Approximately 3 cm below the xiphoid process and 2 cm away from the *linea alba* or abdominal mid-line (upper left side of abdomen) a 1.5 cm full-thickness incision was created through the abdominal wall muscle layers and peritoneum taking special care not to damage the underlying viscera. Skin closure of the created defect was accomplished as previously described. The abdominal wall defect was allowed to mature for a period of 23 days, at which point an exploration surgery was conducted to determine the outcome.

HCP-final—pilot animal no. 5. The final hernia creation procedure employed for animals 5-30 was conducted as described for Hernia Creation Procedure D except that the full-thickness incision into the abdominal cavity was increased from 1.5 cm to 3.0 cm in length. Figure 1 shows the final positioning and size of the created defect model. In addition, the defect was allowed to mature 21 to 35 days prior to mesh hernioplasty to repair the resulting ventral hernia.

Recovery. At the conclusion of each surgery a Fentanyl patch (Duragesic 25 ug/hr) was placed either on the sternum or directly on the back of the animal as a multimodal analgesia. After recovery from anesthesia, animals were returned to housing with no specific restrictions and monitored for well-being and presence of complications.

Hernia assessment. After 21 to 35 days of maturation the mesh hernioplasty surgery was scheduled and the created defect was examined prior to repair using the following procedure. The animal was placed under general anesthesia as previously described and shaved/prepped for surgery. Prior to moving into the surgical suit the developed hernia was palpated in order to obtain a general idea of its severity and size as this was used to determine the most appropriate location for re-entry into the subcutaneous space. If the created hernia exhibited a distinct bulge that was at least 3 cm in diameter, an incision into the skin was made approximately 1 cm towards the midline of the animal away from the hernia edge. This was done to reduce the risk of damaging underlying viscera which often were resting just below the skin. Similarly, if the developed hernia was less than 3 cm, the previous incision point was used to obtain access into the subcutaneous space. Once the skin was compromised, careful blunt dissection was performed around the periphery of the hernia sac in order to create a workable subcutaneous space. The hernia sac was carefully dissected in order to remove any visceral adhesions, if present, and the hernia contents were re-approximated back into the abdominal cavity. The hernia ring was examined and, if deemed necessary, surgically modified to reduce the abdominal wall thickness at its edges as often these were covered in scar tissue developed during the hernia maturation process prior to additional mesh repair activities, which are not discussed within this article.

Results

A summary of the hernia creation development phase can be seen in Table I. Examination of the first pilot animal 36 days following Hernia Creation Procedure (HCP-) A indicated no visual signs of a mature ventral hernia. Palpation of the defect site indicated no protrusion or weak points in the abdominal wall. These findings were confirmed following euthanasia and surgical exploration of the abdominal wall which indicated that the created defect healed nicely with no visceral adhesions. Similar results were noted for HCP-B with no signs of hernia creation and healing of the defect site with a collagenous plug. In contrast, HCP-C resulted in the creation of a large ventral hernia with various animal complications. These included significant weight loss, lack of appetite, and presence of blood in the urine. As such, the animal was euthanized 10 days into the study as humane endpoints were reached. Upon surgical examination, it was discovered that the herniated area was very large (5 cm in diameter) and included portions of the bladder, large intestine, and uterine horn.

During HCP-D, the hernia defect size was reduced and moved away from the lower abdomen to avoid strangulation of critical organs. Exploration surgery performed 23 days post-op revealed the creation of a small ventral hernia in the abdominal

Table I. *Ventral hernia development results.*

Hernia creation procedure	Defect creation location	Defect size	Surgical notes	Surgical result
HCP-A (Animal 1)	3 cm below Xiphoid Process Centered on Linea Alba	3 cm × 1 cm longitudinal section of abdominal wall removed	Peritoneum spared and not disrupted 36 days maturation period	No hernia maturation, defect healed over with collagenous plug.
HCP-B (Animal 2)	13 cm below Xiphoid Process 2 cm left of Linea Alba	3 cm × 1 cm longitudinal section of abdominal wall removed	2-cm longitudinal incision through peritoneum Two sutures (Vicryl® 2-0) used to bridge peritoneum to prevent viscera from entering subcutaneous space 35 days maturation period	Peritoneum spared No hernia maturation, defect healed over with collagenous plug.
HCP-C (Animal 3)	13 cm below Xiphoid Process 2 cm left of Linea Alba	3 cm × 1 cm longitudinal section of abdominal wall removed 3 cm longitudinal incision through peritoneum	Peritoneum spared 10 days humane endpoint reached	Large ventral hernia with strangulation of critical internal organs. Animal euthanized 10-days post op as humane end points reached.
HCP-D (Animal 4)	3 cm below Xiphoid Process 2 cm left of Linea Alba	1.5 cm full thickness longitudinal incision	Wall and peritoneum spared 23 days maturation period	Small mature ventral hernia 1×0.5 cm in size.
HCP-FINAL (Animals 5-30)	3 cm below Xiphoid Process 2 cm left of Linea Alba	3 cm full thickness longitudinal incision	Wall and peritoneum spared 28 days maturation period	Mature ventral hernia measuring 1.5×1.0 cm.

wall that measured 1 cm (longitudinally) × 0.5 cm with a distinct hernia ring. In the final surgical pilot (HCP- FINAL) the full thickness laparotomy was increased to 3 cm in order to facilitate the creation of a larger ventral hernia for mesh repair. See Figure 2 for images of the resulting mature ventral hernia. The technique used in HCP-FINAL was used to create mature defects in a total of 26 animals, with results identified in Table II. Hernias were all circular in nature and often presented as a weakened area in the abdominal wall.

Discussion

In order to examine the effect of mesh biomechanics on the wound healing process as it relates to ventral hernia repair, the use of an animal model which effectively replicates the wound pathology associated with mature hernia development in humans was required. Therefore, a primary segment of research was focused on creating such a model using New Zealand White rabbits. A review of the literature identified two potential procedures for attaining this model type in the chosen animal species. The first described by Silva and colleagues (22) utilizes a potentially less aggressive approach where a small area of the abdominal wall muscle layer is removed while preserving the peritoneum. This approach was attempted in Hernia Creation Procedure A (HCP-A) where a

3×1 cm section of the abdominal wall musculature was removed while preserving the peritoneum. The defect was allowed to mature over a course of 35 days culminating in the formation of a collagenous plug at the defect site. Therefore, this procedure did not result in the formation of a mature ventral hernia as previously described. As a limited number of pilot animals were available for this segment, slightly more aggressive approaches were taken with each successive hernia creation procedure until the desired result was reached. In HCP-B the peritoneum was compromised in addition to removing a 3×1 cm are of the abdominal wall musculature. Prior to closing, two throws of a fast absorbing suture were placed at the edges of the created wound to provide temporary support and prevent immediate herniation. The center most portion of the created defect was left open in order to increase the probability of ventral hernia creation. As with HCP-A, this also resulted in a “healed” situation where a collagenous plug filled in the weakened area over a 35 day study period. In the subsequent hernia creation procedure, HCP-C, the defect site was moved to the lower left abdominal wall quadrant as this area is inherently weaker in the NZW rabbit. In addition to removing a 3×1 cm section of the abdominal wall muscle layer, a 3-cm lateral incision through the peritoneum was created and left open. This resulted in a large ventral hernia with strangulation of various critical organs, therefore for

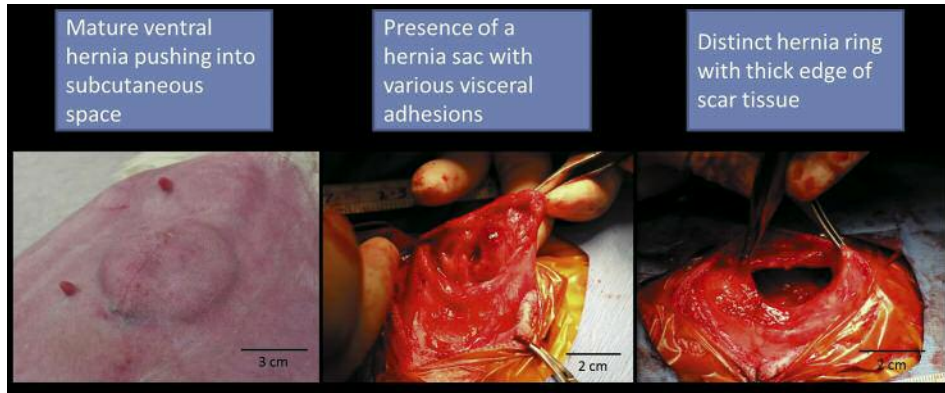


Figure 2. Final mature ventral hernia model which replicates wound pathology associated with hernias as they present clinically in humans.

HCP-D the defect site was moved back to the upper left quadrant and reduced in size. A successful mature ventral hernia was created with HCP-D although the size of the resulting hernia ring was smaller than desired for proper mesh assessment and made the hernia repair difficult due to the limited surgical space. In order to create a larger and possibly more reliable ventral hernia, the incision into the muscle and peritoneal layers was increased to 3 cm.

Examination of the final hernia creation procedure over the course of this study (26 total animals) reveals some level of variability in the size or area of the resulting hernia, as indicated in Table II, even though the initial abdominal wall defect created in each animal were similar in length and location. This variability may be a reflection of differences in animal activity as more movement following defect creation would likely increase the severity of the resulting hernia. However, it is important to note that this level of variability is likely similar to what is seen in the human situation as hernias often present in various shapes and sizes. In each animal, the hernia ring was found as a ring of fibrous tissue that was significantly stiffer than the virgin muscle and peritoneal layers. Smaller-sized hernias within the study group did not present with a high degree of hernia sac formation and visceral adhesions, likely due to the reduced contact of visceral organs with subcutaneous tissues. Further increases in the initial defect size may potentially increase the likelihood of hernia sac formation, but may also increase the risk of strangulation of critical organs as pre-mature loss of animal life must be assessed in the design of any animal study.

The creation of a critical-size abdominal wall defect, as reported in this study, was considered successful, providing a mechanism to study the effects on hernia repair products and procedures on a physiologically relevant mature hernia. This approach does provide some difficulty with further study planning and design, however, and the benefits of

Table II. Hernia results for matured defects created using technique established in HCP- FINAL (n=26 animals).

Surgical Technique	Outcome
Three-cm full-thickness incision in the upper left quadrant that traveled through the muscle and peritoneal layers	Mature ventral hernia measuring approximately 1.5x1.0 cm
Presence of hernia defect	26 of 26 (100%)
Average hernia area (cm ²)	2.22±1.16
Maximum hernia area (cm ²)	5.06
Minimum hernia area (cm ²)	0.61
Incidence of hernia sac with visceral adhesions	11 of 26 (42%)
Presence of thickened hernia ring tissue	26 of 26 (100%)

using this model should be weighed against specific study constraints. Specifically, the surgical approach is relatively difficult for the mature hernia and introduces animal risk due to the 2nd survival surgery. Location and isolation of hernia edges is also more complex than a simple *en bloc* resection of the abdominal wall. Complications associated with naturally occurring hernias are present as well, and within this study the incorporation of adipose adhesions, hernia edge thickening and protrusion of underlying organs into the hernia space was noted, the latter complication seen only in HCP-A. The initial hernia creation procedure along with time for maturation adds study cost and time, as well as potentially introduces a level of variability into the study design. As previously discussed, researchers often opt for a simple acute hernia creation and repair model as this limits the amount of variability seen from animal to animal making comparisons between different mesh designs easier. While this seems like the best decision from a study control

standard, it potentially hides real world variables that physicians face day to day and may be the reason some mesh designs perform well during animal trials but exhibit poor translational results when used in a clinical setting. By applying a mature hernia model, the researcher may identify not only the direct effect of the product or technique on healthy tissues but more accurately uncover the contribution of materials and surgical intervention to repair and heal a physiologically relevant hernia defect.

Conclusion

The present study resulted in the development of a technique to create a critical-size defect in the abdominal wall of NZW rabbits that recreated wound pathology associated with chronic hernia development in humans including the presence of a distinct hernia sack, hernia ring, and various visceral adhesions.

Acknowledgements

Research reported in this article was supported by NIGMS of the National Institute of Health under award number R43GM112194. The authors would like to acknowledge the contributions of Dr. John Parrish and Travis Pruitt at Godley-Snell Research Center at Clemson University.

References

- 1 Kingsnorth A and LeBlanc K: Hernias: Inguinal and incisional. *Lancet* 362: 1561-1571, 2003.
- 2 Penttinen R and Grönroos JM: Mesh repair of common abdominal hernias: a review on experimental and clinical studies. *Hernia* 12(4): 337-344, 2008.
- 3 Horan RL, Bramono DS, Stanley JRL, Simmons Q, Chen J, Boepple HE and Altman GH: Biological and biomechanical assessment of a long-term bioresorbable silk-derived surgical mesh in an abdominal body wall defect model. *Hernia* 13(2): 189-199, 2009.
- 4 Ditzel M, Deerenberg EB, Grotenhuis N, Harlaar JJ, Monkhorst K, Bastiaansen-Jenniskens YM, Jeekel J and Lange JF: Biologic meshes are not superior to synthetic meshes in ventral hernia repair: an experimental study with long-term follow-up evaluation. *Surg Endosc* 27(10): 3654-3662, 2013.
- 5 Baptista ML, Bonsack ME and Delaney JP: Seprafilm reduces adhesions to polypropylene mesh. *Surgery* 128(1): 86-92, 2000.
- 6 Felemovicius I, Bonsack ME, Hagerman G and Delaney JP: Prevention of adhesions to polypropylene mesh. *J Am Coll Surg* 198(4): 543-548, 2004.
- 7 Rosch R, Junge K, Quester R, Klinge U, Klosterhalfen B and Schumpelick V: Vypro II® Mesh in Hernia Repair: Impact of Polyglactin on Long-Term Incorporation in Rats. *Eur Surg Res* 35(5): 445-450, 2003.
- 8 Klinge U, Klosterhalfen B, Birkenhauer V, Junge K, Conze J and Schumpelick V: Impact of polymer pore size on the interface scar formation in a rat model. *J Surg Res* 103(2): 208-214, 2002.
- 9 Muftuoglu M a T, Gungor O, Odabasi M, Ekinci O, Teyyareci A, Sekmen U and Saglam A: The comparison of heavyweight mesh and lightweight mesh in an incisional animal model. *Hernia* 14(4): 397-400, 2010.
- 10 Judge TW, Parker DM and Dinsmore RC: Abdominal wall hernia repair: a comparison of sepramesh and parietex composite mesh in a rabbit hernia model. *J Am Coll Surg* 204(2): 276-281, 2007.
- 11 Young RM, Gustafson R and Dinsmore RC: Sepramesh vs. Dualmesh for abdominal wall hernia repairs in a rabbit model. *Curr Surg* 61(1): 77-79, 2004.
- 12 Greenawalt KE, Butler TJ, Rowe EA, Finneral AC, Garlick DS and Burns JW: Evaluation of sepramesh biosurgical composite in a rabbit hernia repair model. *J Surg Res* 94(2): 92-98, 2009.
- 13 Hjort H, Mathisen T, Alves a, Clermont G and Boutrand JP: Three-year results from a preclinical implantation study of a long-term resorbable surgical mesh with time-dependent mechanical characteristics. *Hernia* 16(2): 191-197, 2012.
- 14 Grommes J, Binnebösel M, Klink CD, von Trotha KT, Junge K and Conze J: Different methods of mesh fixation in open retromuscular incisional hernia repair: a comparative study in pigs. *Hernia* 14(6): 623-627, 2010.
- 15 Cornwell KG, Zhang F and Lineaweaver W: Bovine fetal collagen reinforcement in a small animal model of hernia with component repair. *J Surg Res* 201(2): 416-424, 2015.
- 16 Simón-Allué R, Montiel JM, Bellón JM and Calvo B: Developing a new methodology to characterize in vivo the passive mechanical behavior of abdominal wall on an animal model. *J Mech Behavior of Biomed Mater* 51: 40-49, 2015.
- 17 Panaro F, Matos-Azevedo AM, Fatas JA, Marin J, Navarro F and Zaragoza-Fernandez C: Endoscopic and histological evaluations of a newly designed inguinal hernia mesh implant: Experimental studies on porcine animal model and human cadaver. *Ann Med Surg* 4(2): 172-178, 2015.
- 18 DuBay D a, Wang X, Adamson B, Kuzon WM, Dennis RG and Franz MG: Progressive fascial wound failure impairs subsequent abdominal wall repairs: a new animal model of incisional hernia formation. *Surgery* 137(4): 463-471, 2005.
- 19 DuBay D a, Wang X, Adamson B, Kuzon WM, Dennis RG and Franz MG: Mesh incisional herniorrhaphy increases abdominal wall elastic properties: a mechanism for decreased hernia recurrences in comparison with suture repair. *Surgery* 140(1): 14-24, 2006.
- 20 Akinci M, Ergul Z, Kantarcioglu M, Tapan S, Ozler M, Gunal A, Kulacoglu H, Ide T, Sayal A, Eryilmaz M and Kozak O: The effect of relaparotomy timing on wound healing in an animal model. *Int J Surg* 12(12): 1434-1438, 2014.
- 21 Minossi JG, Caramouri CA, Leite CVDS and Naresse LE: Comparative study between two techniques of incisional hernia repair with polypropylene mesh in rabbits. *Acta Cir Bras* 25(5): 423-427, 2010.
- 22 Silva W da, Fagundes DJ, Seidel AC and Taha MO: Models, Biological Animal model of chronic abdominal hernia in rabbit. *Acta Cir Bras* 24(4): 256-261, 2009..
- 23 Jenkins ED, Melman L, Deeken CR, Greco SC, Frisella MM and Matthews BD: Evaluation of fenestrated and non-fenestrated biologic grafts in a porcine model of mature ventral incisional hernia repair. *Hernia* 14(6): 599-610, 2010.

Received March 30, 2016

Revised June 1, 2016

Accepted June 21, 2016