

Lateral Approach for Excision of Maxillary Incisor Pseudo-Odontoma in Prairie Dogs (*Cynomys ludovicianus*)

IGOR PELIZZONE¹, GAETANO D. VITOLO², MASSIMO D'ACIERNO^{2†},
DAMIANO STEFANELLO³, ANNALISA FORLANI³ and GUIDO BROICH⁴

¹Belvedere Veterinary Clinic, Reggio Emilia, Italy;

²Turro Veterinary Clinic, Milan, Italy;

³Department of Veterinary Science and Public Health, University of Milan, Milan, Italy;

⁴Institute of Forensic Medicine, University of Ferrara, Ferrara, Italy

Abstract. *Aim: To describe our experience with lateral approach for excision of maxillary pseudo-odontomas and to illustrate surgical outcomes and postoperative complications in seven pet prairie dogs. Materials and Methods: Excision of 11 maxillary pseudo-odontomas was performed in seven prairie dogs with a lateral approach technique and clinical presentation, duration of surgery, time and type of post-surgical complications, presence or absence of symptom recurrence, time to follow-up, overall survival time and causes of death of each case were recorded. Results: Duration of surgery, postoperative hospitalization and time to autonomous feeding were 54.8 min, 58 h and 1 day, respectively. Recurrence of respiratory symptoms was observed in four cases. Mean follow-up time was 632 days. Six out of seven cases were still alive at the end of the study. Conclusion: The lateral approach to excision showed good and promising results for treatment of maxillary pseudo-odontomas in prairie dogs.*

Prairie dogs (*Cynomys ludovicianus*) belong to the order of rodents and suborder of *Sciuromorpha* (1). In prairie dogs, the incisor teeth are elodont (also called aradicular, since they do not develop anatomical roots and grow continuously) (2). The cheek teeth (common definition in rabbits and rodents, for teeth different from incisors) are anelodont (with a limited period of growth) (2). A common disease in prairie dogs is pseudo-odontoma, which is considered a dysplastic

disease that affects the apex and the reserve crowns of maxillary and mandibular incisors (4). This lesion has also been called “odontogenic dysplasia of ageing rodents” (4) and seems to be the result of crowding of the odontogenic tissue rather than true excessive proliferation (4, 5). The pathogenesis of these dysplastic lesions is still unknown, but various hypotheses have been postulated (4, 5).

Another disease that may affect maxillary and mandibular incisors in prairie dog is odontoma (6). Odontomas are classified as tumors of odontogenic origin, which are further classified as compound and complex (7). Some authors consider them to be more correctly designated as hamartomas (7). Chronic mild trauma or severe traumatic incidents, such as falling from height have been proposed as causes of odontomas in prairie dogs (8). Boy and Steenkamp in 2006, stated that “the debatable hamartomatous vs. neoplastic nature of odontomas in brachyodont teeth warrants a separate term to describe lesions with similar histological features in elodont teeth” proposing the term 'elodontoma' to replace the term odontoma in respect of hamartomatous lesion in species with elodont teeth (4).

According to a retrospective study performed by the Northwest Zoological Pathology Service in the United States between 1999 and 2009, elodontoma was ranked as the third most common tumor (9.4%) in prairie dogs, after hepatic adenocarcinoma and lymphoid malignancies (35.8% and 14%, respectively) (6) even though in the discussion the authors underlined the hamartomatous nature of this lesion, as also postulated by recent literature (3-6).

Pseudo-odontomas in prairie dogs usually affect animals between 2 and 6 years of age (9) and can affect either maxillary and mandibular incisors or both, but clinical signs and symptoms are elicited mainly by diseased maxillary incisors (3, 5, 8-11). Pseudo-odontomas originate from the germinal plaque and the adjacent areas of the single incisors, where proliferative odontoblastic cells are present and active (4, 12). Anatomically, growth starts from the apical part of

†Posthumous publication.

Correspondence to: Igor Pelizzone, Via G.Beltrami 1, 42123 Reggio Emilia, Italy. Tel: +39 3470489897, e-mail: igorpelizzone@gmail.com

Key Words: *Cynomys ludovicianus*, dentistry, exotic medicine, prairie dog, pseudo-odontoma, surgical excision.

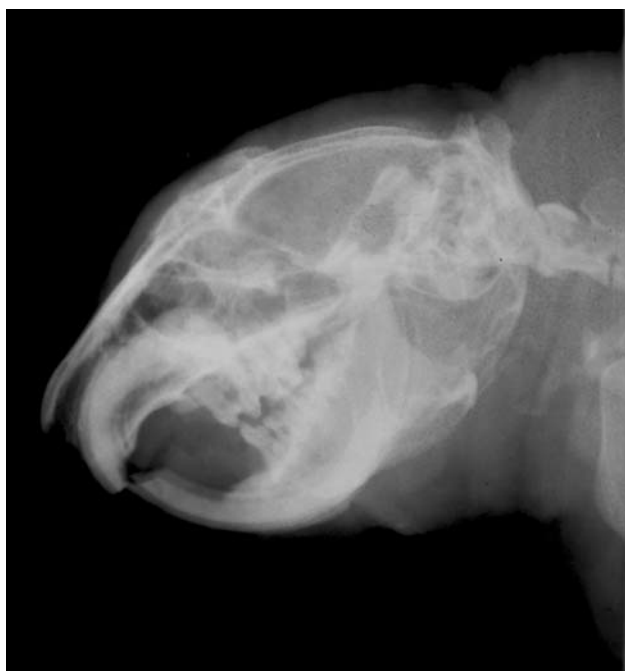

Figure 1. Case 2. Lateral skull radiograph of prairie dog with pseudo-odontoma of a maxillary incisor. At the apex, folds of newly-formed dentine make it thick and irregular. Note the obliteration of the periodontal space.

the tooth within the incisive bone which is close (lateral and dorsal) the hard palate, and progresses to occlude the posterior choanae and the posterior nasal meatus (2).

Different procedures have been reported in the literature for the surgical treatment of this disease. Some techniques are causative in order to remove the pseudo-odontoma completely, while others are considered palliative since they have the purpose of by-passing the pseudo-odontoma and enlarging the respiratory opening to improve the clinical symptoms. Permanent rhinostomy is a palliative procedure to extend the lifetime of the animal, or to relieve the symptoms temporarily, until the stoma remains open (10, 13). Recently, bilateral rhinotomy with surgical excision was described for the treatment of pseudo-odontoma in three black-tailed prairie dogs (14). In these cases, after surgical excision of the mass and the diseased tooth, the authors placed two red rubber catheters into each nasal passage providing a temporary stent and placed a temporary dorsal rhinostomy stent using a cut endotracheal tube (14). A transpalatal approach is also reported (5). This technique can be performed through the palate from an intraoral approach.

We describe our experience with a lateral approach for the excision of maxillary pseudo-odontomas in a homogeneous population of pet prairie dogs, and we report on the surgical outcome and postoperative complications.

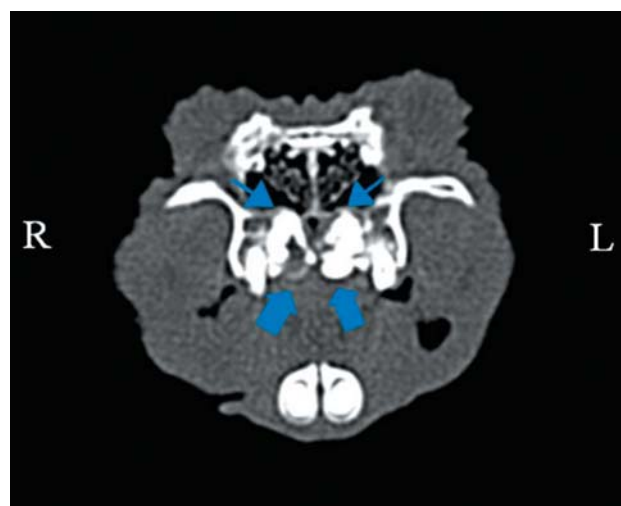


Figure 2. Case 4. Computed tomography (axial view, bone window) of the head. Note the partial obstruction of nasopharyngeal meatus due to bilateral pseudo-odontomas. On the right side (R) the lesion involves the palatine bone (thick arrow), whereas on the left side (L) there is a fracture of the hard palate (thin arrow).

Materials and Methods

A retrospective study was performed including pet prairie dogs with diagnosis of maxillary pseudo-odontoma presented at our clinic between August 2012 and November 2013.

Patients were included in the study if they were not eligible for extraction of incisors using the standard technique performed in rabbits and had pre- and post-surgical evaluation of the skull with standard x-rays with/without computed tomography (CT) (Figures 1 and 2) (Siemens Somatom Emotion®; Siemens Milan, Italy). Data retrieved included: sex, age, weight, clinical signs, complete blood count and biochemistry panel before surgery, duration of surgery (from skin incision to excision of the pseudo-odontoma), presence of unilateral or bilateral masses, postoperative hospitalization period, time needed to regain autonomous feeding, type and time of postoperative complications (dysphagia, sneezing, nasal discharge, dyspnea, anorexia, death), time to symptom recurrence, follow-up time (from the date of surgery to the last follow-up), overall survival time (from the date of surgery to death) and cause of death. If necropsy was performed, this was recorded. In the presence of recurrent symptoms or signs, such as nasal discharge and dyspnea that were non-responsive to medical therapy, a surgical revision was performed.

All excised specimens were formalin fixed and submitted to a pathology service for histological evaluation. Short term re-evaluations were scheduled 7 and 14 days after surgery. Long-term follow-up ranged between 395 and 760 days (mean=632 days).

Anesthetic and analgesic procedures. For diagnostic procedures, all prairie dogs were anesthetized with medetomidine [50 µg/kg intramuscularly (*i.m.*), Domitor®, Orion Pharma, Italia Srl, Milan, Italy], ketamine (10 mg/kg, *i.m.*), Imalgene 1000®, Merial Italia SpA, Milan, Italy], and supplemental oxygen was given by facemask.

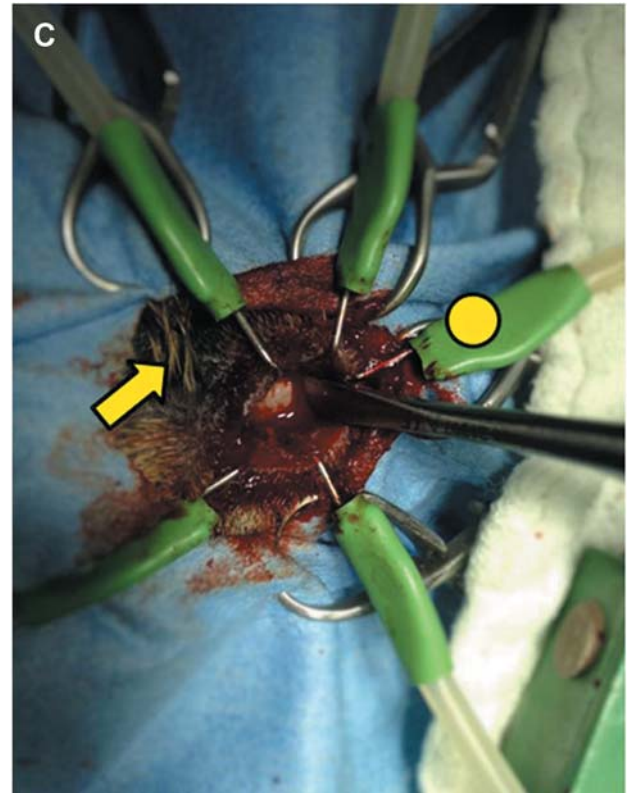
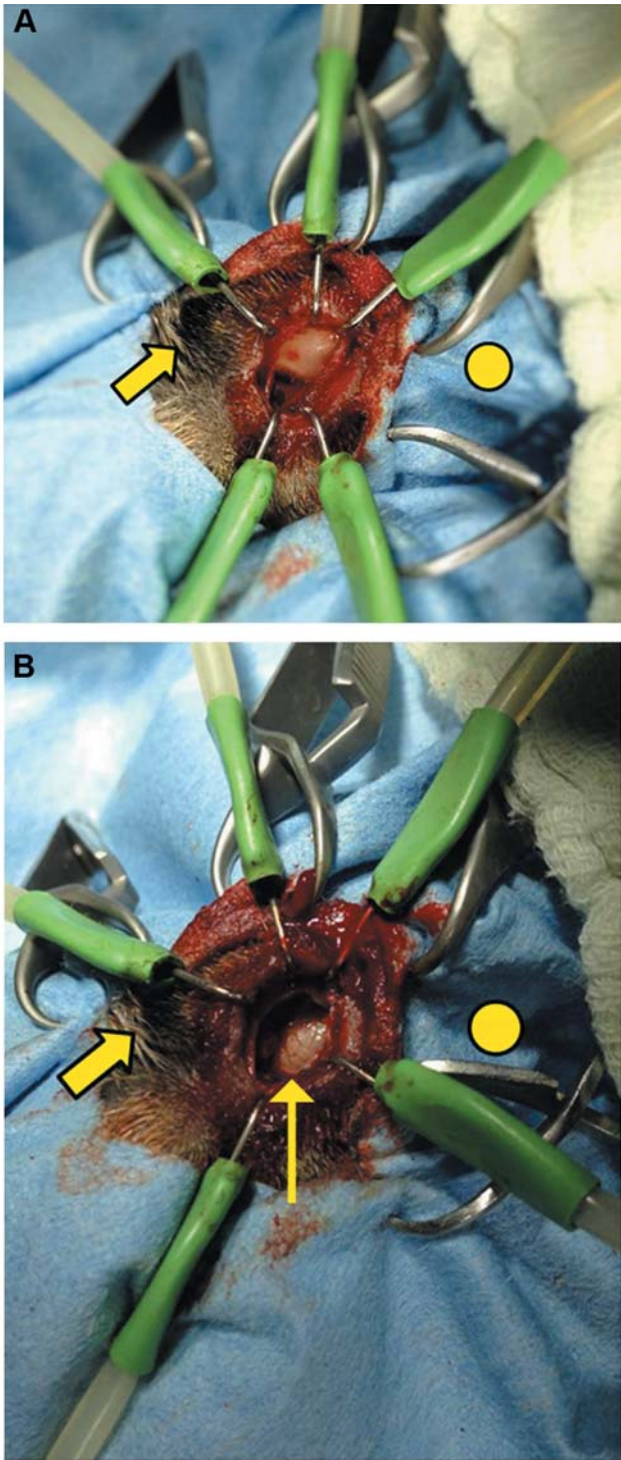


Figure 3. A: Skin incision and dissection of underlying tissue rostral to the medial canthus of the eye showing nasal bone close to the incisive bone in a prairie dog. B: Bone window between the nasal and incisive bones enables access to part of reserve crown of the affected maxillary incisor (thin arrow). C: Periosteal elevator used for removal of the apex and part of reserve crown of tooth with pseudo-odontoma. Thick line: Medial canthus of the eye. Yellow dot: Cranial side of the head.

Before surgery, animals were hyperoxygenated for approximately 15 min. They were anesthetized with medetomidine (80 µg/kg *i.m.*, Domitor®; Orion Pharma Italia Srl, 20124, Milan, Italy) and ketamine (10 mg/kg *i.m.*, Imalgene 1000®; Merial Italia SpA); tramadol (4 mg/kg *i.m.*, Altadol®; Formevet Italia, Milan, Italy) was given as analgesic. Ten minutes later, an intravenous (*i.v.*) catheter was placed

in the cephalic vein and propofol (4 mg/kg *i.v.*, Propovet®; Esteve Italia SpA, Milan, Italy) was given to facilitate intubation. The patients were intubated with a Sheridan ID 2.0 endotracheal tube using blind intubation technique. Anesthesia was maintained with 2% isoflurane (Isoflo®; Esteve Italia SpA) in oxygen.

Surgical technique. Prairie dogs were placed in sternal recumbency. Hair was clipped over the surgical site, and the skin was aseptically prepared. A skin incision was made approximately half way between the medial canthus of the eye and sagittal median line, running longitudinally in the rostral direction for approximately 2-3 cm. Blunt dissection of the periosteum was performed with a periosteal elevator, and a Lone Star retractor (CooperSurgical, Inc., Trumbull, CT, USA) was placed. The joint between the nasal and the incisive bone was identified (Figure 3A).

A 1.5 cm × 1.5 cm osteotomy of the nasal and incisive bone was performed with a tapered grit diamond burr on a high-speed air turbine hand piece (SuperAir®; TecnoMed Italia Group, Castelvecchio di Monte Porzio, PU, Italy). The bone window was created at that level to preserve the infraorbital neurovascular bundle, avoiding hemorrhage and postsurgical paresthesia. The reserve crown was exposed through

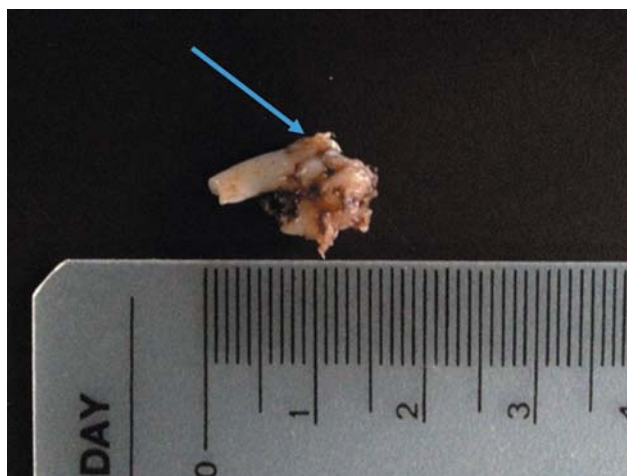

Figure 4. Case 7. Maxillary incisor characterized by the presence of a mass affecting its apex and the reserve crown. Blue arrow: Apical part of maxillary incisor (reserve crown) with alteration of surface due to multiglobular masses. Note the corrugated aspect of the tooth.

the osteotomy (Figure 3B) and the incisor tooth was cut with the same drill head. Using a small dental luxator or a periosteal elevator, the whole caudal part of the tooth including the apical pseudo-odontoma was mobilized (Figure 3C), and with small longitudinal torsional movements the excision was performed. Excision should be performed taking great care to preserve the periosteum of the palatal side of the incisor tooth and underlying buccal mucosa (Figure 4). The rostral portion of the reserve crown and the clinical crown of the tooth stay in place. The surgical wound was not closed.

Separate surgical excision was performed on prairie dogs with bilateral pseudo-odontomas when allowed by the clinical condition of the patient.

In cases in which recurrent symptoms were unresponsive to medical treatment, a surgical debridement of the wound was performed. Additional surgical treatment consisted in a surgical curettage under anesthesia primarily directed at the scar tissue where the surgical breach was, whereas the caudal part of the socket was drilled with a round dental diamond burr on a high speed hand piece (P125; iM3 Pty Ltd., Lane Cove, NSW, Australia).

Postoperative care. Postoperative therapy was similar for all patients and included enrofloxacin (Baytril® flavour 2.5%, Bayer SpA, Milan, Italy) 10 mg/kg given orally (*o.s.*) every 24 h for 10 days, meloxicam (Metacam® Sol. Iniettabile, Boehringer Ingelheim Italia SpA, Milan, Italy) 0.3 mg/kg given subcutaneously (*s.c.*) every 24 hours for 7 days and wound cleaning and disinfection 2-3 times a day until the surgical wound was completely healed. Support feeding formula for herbivores (Critical Care®; Oxbow Animal Health, Murdock, NE, USA) was administered orally to animals until they were able to eat spontaneously.

Results

Seven prairie dogs (*Cynomys ludovicianus*), five males and two females, median age=46.85 months (range: 29-72 months), median weight 1237.14 g (± 256 g), were studied. Blood

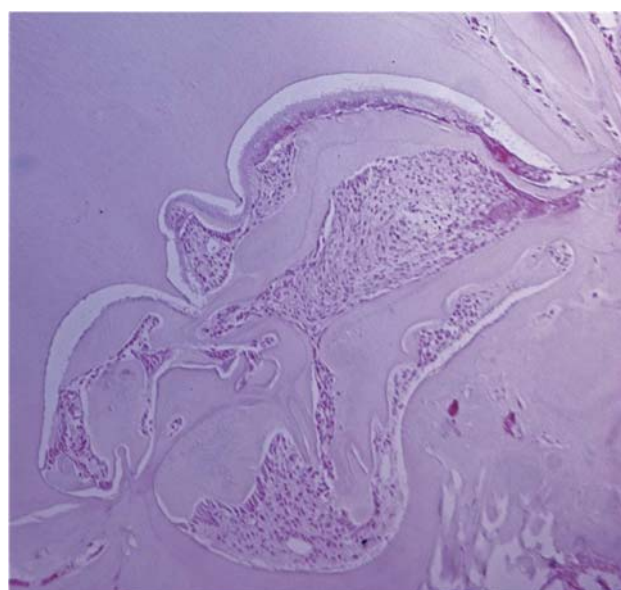


Figure 5. Case 7. Histopathology of pseudo-odontoma in a prairie dog. The mass was composed of disorganized odontogenic elements including ameloblastic epithelium (A), stellate reticulum-like structure (SR), dentine and cementum. (Hematoxylin & eosin, $\times 50$).

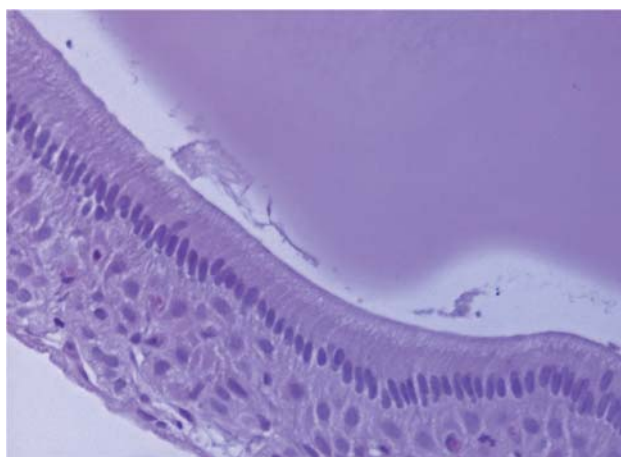


Figure 6. Magnified view of the ameloblastic epithelium shown in Figure 5. Note the prominent palisading arrangement of cells with basal nuclei (hematoxylin & eosin, $\times 200$). M: Male; F: female; R: right; L: left.

analysis results were within previously reported normal ranges (12). Five prairie dogs presented with different degrees of respiratory distress (from sneezing to open mouth breathing), one for fracture of the right maxillary incisive tooth and one to assess an oronasal fistula. Six cases were CT scanned, and one case underwent a skull radiographic study (Figure 1) because the owners declined cross-sectional imaging.

Table I. Clinical data and surgical times for lateral approach to pseudo-odontoma in seven prairie dogs (*Cynomys ludovicianus*).

Case	Gender	Weight (g)	Age (months)	Respiratory distress	Presentation	Surgical time for each side (min)	Recovery time (days)	Residual respiratory distress (long-term)	Revision surgery	Survival time mean (days)	Status at study end
1	M	1290	29	Yes	Bilateral	66 (R) 56 (L)	3	Yes	Yes	655	Died from hepatic cancer
2	M	1100	32	No	Unilateral	51	4	No	No	760	Alive
3	M	1250	54	Yes	Bilateral	57 (L) 52 (R)	1	Yes	Yes	715	Alive
4	M	1100	48	Yes	Bilateral	55 (R) 56 (L)	1	No	Yes	685	Alive
5	F	920	71	No	Unilateral	50	1	No	No	630	Alive
6	F	1800	43	Yes	Bilateral	54	3	No	No	425	Alive
7	M	1200	51	Yes	Unilateral	52	3	No	No	395	Alive

M: Male; F: female; R: right; L: left.

Clinical, radiological and CT evaluation were suggestive of the presence of bilateral and unilateral maxillary pseudo-odontoma in four and three prairie dogs, respectively. Eleven incisor pseudo-odontomas were excised from seven prairie dogs. All prairie dogs were able to eat spontaneously 24 h after surgery (Table I). No patients showed complications during hospitalization or at discharge.

Histologically, the parenchyma of the mass comprised of islands or nests of epithelial and mesenchymal elements that formed abortive tooth structures. The epithelial component was composed of a single layer of tall columnar cells, 25 microns in length, with variably distinct cells borders, and a moderate amount of intensely eosinophilic cytoplasm. Nuclei were round to oval, 10 micron in diameter, basal with dispersed chromatin and no evident nucleoli (ameloblasts). The cells were characterized by a palisading arrangement in contrast to the dentine layer. The mesenchymal structures were composed of round to stellate cells, 25 microns in diameter, with variably distinct cell borders and a moderate to abundant pale eosinophilic cytoplasm. The nuclei were oval, 10-12 microns in diameter, centrally to eccentrically placed, with dispersed chromatin and no evident nucleoli (odontogenic mesenchyme).

Both types of cells were characterized by minimal anisocytosis and anisokaryosis, and no mitotic Figures were evident. The remaining 80% of the lesion was composed of an acellular material containing two irregular demarcated layers. The layer opposing the mesenchyme was homogeneous and eosinophilic (predentine), while the adjacent outer layer was composed of eosinophilic material containing tubular structures (dentine) that blended into loosely arranged basophilic homogeneous tissue (cementum). Cysts containing disorganized structures slightly resembling developing teeth were present, scattered throughout the tissue (Figures 5 and 6). Clinical presentation, diagnostic imaging findings along

with histological features were consistent with a diagnosis of pseudo-odontoma. Postoperative complications after eleven excisions of incisor pseudo-odontomas were detected in four prairie dogs, all of which had bilateral pseudo-odontomas. Three prairie dogs developed sneezing and nasal discharge 14, 30 and 30 days after surgery. One patient was noted to show nasal discharge and respiratory distress 30 days after surgery.

Enrofloxacin (Baytril[®] flavour 2.5%; Bayer SpA) 10 mg/kg *o.s.* every 24 h and meloxicam (Metacam[®]Sol. Iniettabile; Boehringer Ingelheim Italia SpA) 0.3 mg/kg *s.c.* every 24 h were administered in all four cases with postoperative complications. In two cases, ongoing respiratory impairment persisted despite medical therapy. The resolution of inspiratory effort required for surgical revision. Long-term complications, such as sneezing and nasal discharge, were identified in these two patients at day 201 and 240, respectively. At the time of writing, six cases remain alive and one had died of a malignant liver neoplasm, as diagnosed at necropsy.

Discussion

Several surgical techniques have been reported to treat pseudo-odontomas in prairie dogs. Some procedures are palliative (temporary or permanent rhinostomy and debulking of the mass) (5, 10) and others are definitive (excision with standard technique (5, 15, 16), intraoral transpalatal approach (3), rhinotomy dorsal approach (5, 14), rhinotomy through the incisive bone (11).

Although temporary or permanent rhinostomy are associated with a low morbidity, postoperative management to keep the stoma open and to prevent the inhalation of foreign bodies can be difficult (5, 10).

Given the fact that the mass involves the apex and the reserve crown of the tooth, where there is still active odontoblastic tissue, classical rostral extraction of the

affected incisor teeth is challenging at advanced stages of the disease because the reserve crown would fracture (9).

The close relationship between the pseudo-odontoma and the palatal bone makes the surgical approach challenging because of the possible creation of an oronasal fistula. The oral and nasal flora are very different, and great care must be taken to avoid continuity of the oral and the nasal or sinus mucosae (17, 18). These fistulas have to be closed surgically, as they generally cannot be managed successfully conservatively (17, 18). To avoid a fistula, integrity of the buccal mucosa is of utmost importance (3, 18).

Furthermore local recurrence, upper airway respiratory postoperative complications and prolonged postoperative care were described in prairie dogs following the excision of pseudo-odontomas (14).

In the present study, a lateral approach was used to reduce the incidence of postoperative complications.

We decided not to proceed with the extraction of the rostral part of the diseased tooth (reserve crown and clinical crown) in order to reduce recovery after surgery and to avoid drilling or extracting mandibular incisors. Initially we considered proceeding with the extraction of the four incisors in a second stage but to our experience, this has not been necessary in any prairie dog.

CT was used for preoperative planning in most of our cases. CT facilitates the diagnosis of bilateral involvement compared to conventional skull x-rays, and allows the extent of the pseudo-odontoma to be clearly defined. In addition, if symptoms recur after surgery, CT can help discriminate between reactive tissue and pseudo-odontoma recurrence.

Results showed a good surgical outcome, short recovery time, and absence of oro-nasal fistula in the follow-up period. Comparison with other case series is very difficult due to the low number of cases enrolled, different inclusion criteria and variables investigated (14).

This technique is less invasive compared to bilateral rhinostomy (14), allows for a good exposure of the apex of the incisor and minimizes the risk of oronasal fistula.

Even though this technique appears promising, different outcomes were observed among the enrolled prairie dogs. In particular, we found that prairie dogs with bilateral disease had a higher prevalence of postoperative complications and symptom recurrence compared to those with unilateral presentation. Treatment of symptom recurrence was conservative, although, in the absence of improvement, additional surgical treatment was used. This approach was necessary in two out of the four cases with bilateral presentation in which previous medical management of postoperative complications had failed. These additional surgical procedures were considered anecdotal and are not corroborated by previous studies. We are aware that further studies are needed to explore their real usefulness.

In a previous study (8), data on local recurrence were reported, although the method of recurrence diagnosis was not specified. Further studies are needed to demonstrate the etiology of symptom recurrence and assess its relationship with the type of pathology (pseudo-odontoma *versus* elodontoma) and tissues involved (hard or soft tissues). A larger study population is needed to confirm the surgical results achieved in the present study.

In conclusion, the aim of this study was to describe our experience with a lateral approach to pseudo-odontoma in prairie dogs. This surgical approach appeared to have low morbidity, to allow an uneventful postoperative recovery and was effective in all our patients for long-term control of the clinical signs.

Acknowledgements

The Authors wish to thank Dr. Gena Seaberg, Ph.D., whose insightful suggestions and advice in the field of prairie dog care and health were of immense value.

Dr. Massimo D'Acerno was awarded the AICDP 'Sansone' Prize for Research of 2012 for his scientific activity in the field of surgical approach on prairie dog odontoma. Sadly, he unexpectedly died in July 2013 in a road traffic accident. We propose to name this lateral surgical approach after D'Acerno, in memory of the first among the Authors that applied this surgical treatment approach.

References

- 1 Macdonald DW: Rodents. *In: The Encyclopedia of Mammals* Second Edition. Macdonald DW (eds.). Oxford, University Press, pp. 128-167, 2010.
- 2 Capello V, Gracis M and Lennox AM (eds.): *Rabbit and Rodent dentistry Handbook*. Ames, IA: Blackwell Publishing, (formerly Zoological Education Network, Lake Worth, FL), 2005.
- 3 Capello V: Diagnosis and treatment of dental disease in pet rodents. *J Exotic Pet Med* 17(2): 114-123, 2008.
- 4 Boy SC and Steenkamp G: Odontoma-like tumors of squirrel elodont incisor-elodontomas. *J Comp Pathol* 135(1): 56-61, 2006.
- 5 Crossley DA: Small Mammal Dentistry. *In: Ferrets, Rabbits and Rodents, Clinical Medicine and Surgery* Second Edition. Quesenberry KE, Carpenter JW (eds.) St. Louis MO, Elsevier Saunders, pp. 370-382, 2004.
- 6 Thas I and Garner MM: A retrospective study of tumours in black-tailed prairie dogs (*Cynomys ludovicianus*) submitted to a Zoological Pathology Service. *J Comp Pathol* 147(2-3): 368-375, 2012.
- 7 Head KW, Cullen JM, Dubielzig RR, Else RW, Misdorp W, Patnaik AK, Tateyama S and Van der Haag I: Histological classification of tumors of the alimentary system of domestic animals. *In: WHO Histological Classification of Tumors of Domestic Animals, Vol 10*. Head KW (eds.). Washington DC, Armed Forces Institute of Pathology, pp. 46-57, 2003.
- 8 Phalen DN, Antinoff N and Fricke ME: Obstructive respiratory disease in prairie dog with odontomas. *Vet Clin North Am Exot Anim Pract* 3(2): 513-517, 2000.

- 9 Bennet RA: Odontomas in prairie dogs. Proceedings of the North Am Vet Conference, Orlando, FL, pp. 1628-1629, 2007.
- 10 Bulliot C and Mentrè V: Original rhinostomy technique for the treatment of pseudo-odontoma in a prairie dog (*Cynomys ludovicianus*). *J Exotic Pet Med* 22(1): 76-81, 2013.
- 11 Capello V: We are not smaller rabbits, either. Dentistry of other rodent species and ferrets. Proceedings of the North Am Vet Conference, pp. 1681-1684, 2011.
- 12 Legendre LF: Oral disorders of exotic rodents. *Vet Clin North Am Exot Anim Pract* 6(3): 601-628, 2003.
- 13 Wagner R and Johnson D: Rhinotomy for treatment of an odontoma in a prairie dog. *Exotic DVM* 3(5): 29-34, 2001.
- 14 Smith M and Dodd JR: Clinical techniques: Surgical removal of odontoma in the black-tailed prairie dog (*Cynomys ludovicianus*) and eastern fox squirrel (*Sciurus niger*). *J Exotic Pet Med* 22(3): 258-264, 2013.
- 15 Capello V: Incisor extraction to resolve clinical sign of odontoma in prairie dog. *Exotic DVM* 4(1): 9, 2002.
- 16 Stein GG and Da Silva Carissimi A: Pseudo-odontoma in a black tail prairie dog (*Cynomys ludovicianus*). *Acta Scientiae Vet* 36(2): 173-176, 2008.
- 17 Ahmed MV, Naz F, ul Haque Chand MA, Tambuwala A and Kaul D: Repair of iatrogenic oro-nasal fistula after periapical surgery. *Univ Res J Dent* 2(2): 83-86, 2012.
- 18 Degner DA: Surgical considerations of nasal discharge. *Clin Tech Small Anim Prac* 21(2): 64-68, 2006.

Received October 14, 2015
Revised October 31, 2015
Accepted November 5, 2015