in vivo *27*: 803-808 (2013)

Ultrasonographic Evaluation of *Gastrocnemius* Muscle in a Rat Model of *N*-Methyl-*N*-nitrosourea-induced Mammary Tumor

ANA ISABEL FAUSTINO-ROCHA[1], PAULA A. OLIVEIRA[1,2], JOSÉ ALBERTO DUARTE[2], RITA FERREIRA[3] and MÁRIO GINJA[1]

[1]*Department of Veterinary Sciences and Center for Research and Technology of Agro-Environmental and Biological Sciences University of Trás-os-Montes and Alto Douro, Vila Real, Portugal;*
[2]*Center for the Study of Animal Sciences and Research Centre in Physical Activity, Health and Leisure, Faculty of Sports, University of Porto, Porto, Portugal;*
[3]*Mass Spectrometry Center, Department of Chemistry, University of Aveiro, Aveiro, Portugal*

Abstract. *Background/aim: Ultrasonography is frequently used to study body tissues. Our aim was to evaluate by ultrasonography, gastrocnemius muscle wasting induced by cancer in a rat model of chemically-induced mammary tumor, muscular response to exercise. Materials and Methods: Female Sprague-Dawley rats were divided into as well as four groups. Groups I and II were injected with N-methyl-N-nitrosourea (MNU). Groups I and III performed endurance training on a treadmill. Gastrocnemius muscles were palpated for tonus evaluation. Gastrocnemius muscle and fibrous tissue between muscle and tibia were examined by ultrasonography. At necropsy, muscle was collected and weighed. Myostatin was assessed by immunoblotting. Results: The final body weight, gastrocnemius weight, length and width were similar among groups. Tone of muscle was higher in exercised animals. Myostatin was higher in MNU-treated groups. Echogenicity of muscle and fibrous tissue in group IV was higher than in other groups ($p<0.05$). Echogenicity of fibrous tissue was higher than echogenicity of muscle in all groups. Conclusion: Our results showed that muscle ultrasonography is a useful tool to identify alterations in muscle structure. More studies are necessary for researchers to understand the influence of fat location in muscle ultrasonographic imaging.*

Since 1950s, when Wild and colleagues discovered the utility of high-frequency ultrasonic waves in observing living tissues, ultrasonography has been extensively used in medical practice (1, 2). Ultrasonography has many advantages compared to other imaging methods: it is an easily-accessible and safe method to visualize several different types of body tissues, including the skeletal muscle (3), it does not impose ionizing radiation, and allows for dynamic and real-time study (4); ultrasound equipment is portable and less expensive than magnetic resonance imaging (MRI) and computed tomographic equipment (4-6); the ultrasonographic examination is more appropriate for patients with claustrophobia (7, 8) and is not contraindicated in patients with cardiac pacemaker or other metal implants (6, 8). Like other imaging methods, ultrasonography has some disadvantages, namely its operator dependency (6). The echo intensity of ultrasonographic images may be evaluated visually or by using a computer-assisted grey-scale analysis, the latter being the method more accurate to detect small changes in muscle (9). Ultrasonography of skeletal muscle may be used as alternative to or adjuvant non-invasive tool with other imaging methods (2, 5, 6, 10-12).

In ultrasonographic evaluation, skeletal muscle may easily be distinguished from other structures namely, fat, bone, nerves and blood vessels (6, 13). The normal fibers of skeletal muscle appear hypo-echogenic (black) and connective tissue is hyper-echogenic (white) (10-14). Fibrous tissue and fat infiltration in muscle cause increased reflections of the ultrasound beam and a consequent white appearance (13, 14).

Together with *soleus* muscle, the *gastrocnemius* muscle constitutes the *triceps* surae muscle. The *gastrocnemius* muscle has two parts: the lateral head and medial head, which originate on the lateral and medial condyles of the femur, respectively, and connect to the calcaneus. This muscle is located immediately below the skin, flexes the knee and extends to the tarsus (13, 15).

Breast cancer is the most frequent malignancy and the principal cause of death in women worldwide (16). Female rats exposed to *N*-methyl-*N*-nitrosourea (MNU) are the most

Correspondence to: Mário Ginja, Department of Veterinary Sciences, University of Trás-os-Montes and Alto Douro, 5001-801 Vila Real, Portugal. Tel: +351 259350666, Mob: +351 964839923 e-mail: mginja@utad.pt

Key Words: Ultrasonography, *gastrocnemius* muscle, rat, MNU, exercise, mammary tumor.

frequent animal models used by researchers to study mammary tumors (17, 18). MNU has the capacity to induce locally-aggressive mammary tumors in rats, with the capacity to metastasize, similar to those observed in women (19). Breast cancer is also associated with cachexia characterized by severe loss of adipose tissue and body weight (20, 21). Animal models are also useful in studying the effects of several exercise modalities, namely treadmill running and swimming (22). Regular physical exercise has beneficial effects in increasing muscle mass and strength in both animals and humans (23, 24).

The aim of this study was to evaluate by ultrasonography the occurrence of *gastrocnemius* muscle wasting induced by cancer in a rat model of MNU-induced, as well as the muscular response to exercise.

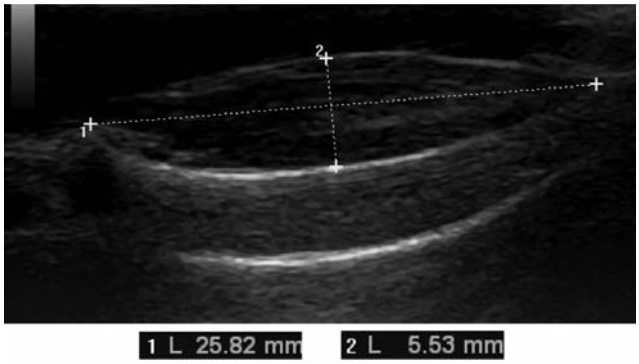

Figure 1. *Measurement of length (**1**) and width (**2**) of gastrocnemius muscle.*

Materials and Methods

Animals. Forty outbred female Sprague-Dawley rats (*Rattus norvegicus*), between four and five weeks of age weighing 170 g in mean, were acquired from Harlan Interfauna Inc. (Barcelona, Spain). Animals were housed in filter-capped polycarbonate cages (five or six rats per cage; 1264C Eurostandard Type II; Tecniplast, Buguggiate, Italy), with corncob for bedding (Mucedola, Milan, Italy). All cages were maintained on a 12/12 hour light/dark cycle in a ventilated room under controlled conditions of temperature (23±2˚C) and relative humidity (50±10%). Cages were cleaned once per week and water was changed weekly. Animals had *ad libitum* access to a basic standard diet (4RF21®; Mucedola) and acidified tap water throughout the study. All animal care and experimental procedures were carried out in accordance with the European Directive 2010/63/EU on the protection of animals used for scientific purposes. Animal procedures were approved by the Portuguese Direção Geral Agrária e Veterinária (no. 008961).

Animal experiments. After two weeks of acclimatization to laboratory conditions, animals were randomly divided to four groups: group I, MNU, exercised, n=10; group II, MNU, sedentary, n=11; group III, Control, exercised, n=10; and group IV, Control, sedentary, n=9. At seven weeks of age, animals from groups I and II were intraperitoneally injected with MNU (ISOPAC®, lot 100M1436V; Sigma Chemical Co., Madrid, Spain) at a dose of 50 mg/kg. Animals from groups III and IV were used as negative controls and were not exposed to MNU. Animals from groups I and III were exercised on a Treadmill Control LE8710 (Harvard Apparatus, Holliston, MA, USA) at a speed of 20 m/min, 60 min/day, 5 days/week, for 34 weeks. To avoid stress to the animals, they were submitted to a familiarization period with the treadmill. During this period the velocity of the apparatus and the duration of the exercise training were increased progressively. Animals from sedentary groups stayed in their cages in the treadmill room during the exercise period. The first week of the experimental protocol was defined at the time of MNU administration and the last week was the week when animals were euthanized. The rats' body weight was monitored weekly using a top-loading balance (METTLER® PM 4000; LabWrench, Midland, Ontario, Canada), starting with the first week of the experiment. The tone of the *gastrocnemius* muscle of both legs of each animal was evaluated at the end of the experiment by palpation by two investigators blinded to group assignment, and considered positive, *i.e.* animals showed an increase in tone of *gastrocnemius* muscle, or negative, *i.e.* the tone of *gastrocnemius* muscle was not increased.

Evaluation of MNU effects. All animals were weekly palpated to detect for the presence of mammary tumors. We recorded the time of appearance of the first tumor and the total number of tumors.

Ultrasound examination. At the end of the experimental protocol, the *gastrocnemius* muscle (lateral and medial heads) of the left leg of each animal was examined by B-mode ultrasound. Before the examination, the leg was shaved with a machine clipper (AESCULAP® GT420 Isis; Aesculap Inc, Center Valley, PA, USA). Animals were restrained in prone position and longitudinal ultrasonographic images were obtained under the same conditions in all animals using acoustic gel (Aquasonic®; Parker Laboratories Inc., Fairfield, NJ, USA) and a real-time scanner (Logic P6®; General Electric Healthcare, Milwaukee, WI, USA) with 10 MHz linear probe. Ultrasonographic apparatus parameters were adjusted as follows: depth: 2 cm, gain: 62 dB. The length and width of *gastrocnemius* muscle were measured by an investigator blinded to the group using electronic cursors integrated into the ultrasound apparatus. Cursors were set at the borders of muscle (Figure 1). The mean echogenicity of each muscle image (lateral and medial heads) and an approximately area of 2 cm^2 of the fibrous tissue between muscle and tibia was evaluated using the standard histogram function of Adobe Photoshop® version 7.0 (Adobe systems Inc., San Jose, CA, USA) (Figure 2).

Necropsy, sample collection and serum analysis. Thirty-five weeks after the start of the experimental protocol, animals from all groups were sacrificed according to the method used by Faustino-Rocha and collaborators (25). Blood samples were collected *via* intra-cardiac punction and serum levels of myostatin were posteriorly determined by immunoblotting technique. We carried out complete necropsies on all animals and collected all mammary tumors, organs and the *gastrocnemius* muscle. The mammary tumors and *gastrocnemius* muscle of each animal were weighed. Accurate body weight of each animal was calculated by the subtraction of the tumor weight from the animal body weight.

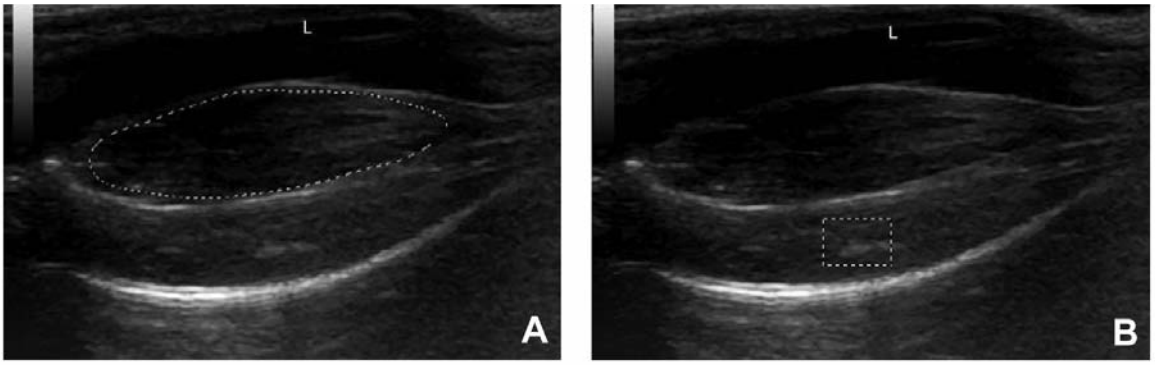

Figure 2. *Measurement of mean pixels using Adobe Photoshop® in the lateral gastrocnemius muscle (A) and in the tissue between muscle and the tibia (B).*

Table I. *Mean (±SD) body weight, tumor weight and accurate body weight.*

Group	Body weight (g)	Tumor weight (g)	Accurate body weight (g)
I (MNU, exercised)	296.73±24.73	19.10±24.28	279.54±25.05
II (MNU, sedentary)	290.30±17.45	13.35±17.70	278.16±22.19
III (Control, exercised)	296.87±24.70	-	-
IV (Control, sedentary)	294.64±18.05	-	-

No statistically significant differences were found (p>0.05).

Table II. *Mean (±SD) of the gastrocnemius muscle weight at necropsy, and its length and width measured by ultrasonography.*

Group	*Gastrocnemius* muscle		
	Weight (g)	Length (mm)	Width (mm)
I (MNU exercised)	1.808±0.295	25.598±0.778	5.806±0.268
II (MNU sedentary)	1.832±0.134	26.339±0.971	6.050±0.239
III (Control, exercised)	1.998±0.185	25.872±0.902	5.770±0.804
IV (Control, sedentary)	1.866±0.241	26.204±1.175	6.086±0.236

No statistically significant differences were found (p>0.05).

Statistics. A descriptive analysis was performed for all variables included in the study. Data were statistically analyzed using SPSS® (Statistical Pachage for the Social Sciences, version 17 for Windows; SPSS Inc., Chicago, IL, USA). Final body weight, *gastrocnemius* muscle weight, echogenicity of muscle and fibrous tissue between muscle and tibia and serum myostatin levels were compared among groups using analysis of variance (ANOVA) with the Bonferroni correction multiple comparison method. Independent *t*-test was also used to compare body weight between MNU (I and II) and Control (III and IV) groups, tumor weights and accurate body weights between groups I (MNU, exercised) and II (MNU, sedentary). Data are presented as the mean±standard deviation (SD). A *p*-value of less than 0.05 was considered to be statistically significant.

Results

General observations. The MNU administration was well-tolerated and all animals exhibited normal cage activity during the experimental protocol.

Body weight. We did not record any differences in body weight and accurate body weight among groups (Table I). However, the accurate body weight of MNU-treated groups (groups I and II) was different from that of Control groups (III and IV) (p<0.05).

Mammary tumors. All animals from groups I and II developed mammary tumors (incidence 100%). We palpated 23 tumors in animals from group I and 28 tumors in animals from group II (data not show). Tumor weight was not different between the MNU, exercised (group I) and non-exercised (group II) animals (p>0.05) (Table I).

Gastrocnemius muscle. All animals from exercised groups (I and III) exhibited an increase in the tone of *gastrocnemius* muscle and were considered positive by both researchers. We did not observe differences in *gastrocnemius* muscle weight, length and width among groups (Table II).

Echogenicity of muscle and fibrous tissue between muscle and tibia. We observed no differences in the echogenicity of the *gastrocnemius* muscle among groups I, II and III (p>0.05). The echogenicity of the *gastrocnemius* muscle of the animals from group IV was higher than what was observed for other groups (p<0.05) (Table III).

Table III. *Echogenicity of gastrocnemius muscle: mean (±SD) of pixels measured using Adobe Photoshop® version 7.0.*

Group	Pixels mean±SD
Gastrocnemius muscle	
I (MNU, exercised)	18.395±7.027
II (MNU, sedentary)	18.406±7.868
III (Control, exercised)	20.656±7.639
IV (Control, sedentary)	29.287±6.313*

*Statistically significant different from groups I, II and III ($p<0.05$).

Table IV. *Echogenicity of fibrous tissue between muscle and the tibia: mean (±SD) of pixels measured using Adobe Photoshop® version 7.0.*

Group	Pixels
Fibrous tissue between muscle and the tibia	
I (MNU, exercised)	40.239±12.437
II (MNU, sedentary)	41.683±9.394
III (Control, exercised)	44.773±9.705
IV (Control, sedentary)	58.104±7.918*

*Statistically significant different from groups I, II and III ($p<0.05$).

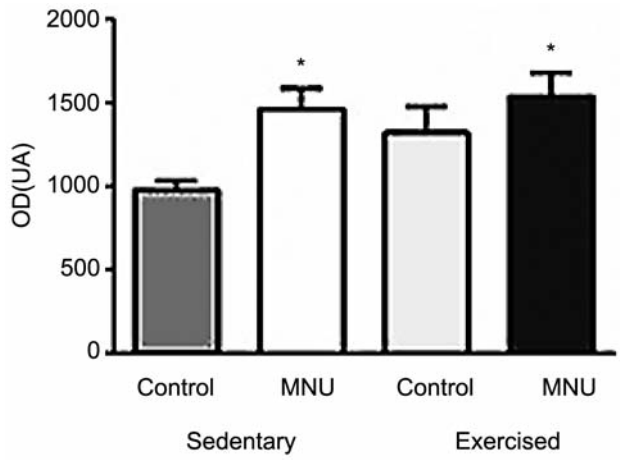

Figure 3. *Optical density measurements for myostatin. *p<0.05 versus Control, sedentary.*

The echogenicity of the fibrous tissue between muscle and tibia was higher than that of the *gastrocnemius* muscle in all groups. As observed for the echogenicity of *gastrocnemius* muscle, the echogenicity of the tissue between muscle and the tibia was similar among groups I, II and III ($p>0.05$) and different from animals of group IV ($p<0.05$) (Table IV).

Serum analysis. Serum myostatin levels were different ($p<0.05$) between MNU groups (group I and II) and group IV (Control, sedentary) (Figure 3).

Discussion

Ultrasonography is frequently used in real-time *in vivo* evaluation of different tissues and organs of the body (2). In this experimental protocol, we evaluated *gastrocnemius* muscle by ultrasonography due to its characteristics: it is a superficial muscle being located immediately below the skin, and its ultrasonographic image is easily obtained (13, 15).

As previously observed by Yeh and collaborators (22), using our experimental protocol the final body weight and *gastrocnemius* muscle weight were not different among groups ($p>0.05$). All animals from MNU groups developed mammary tumors; however the number of tumors was lower in group I. The lower body condition of animals with tumors was compensated in terms of animal live weight for the development of tumor masses. The absence of differences of muscle weight agree with the similar ultrasonographic lengths and widths of the *gastrocnemius* muscle of these animals ($p>0.05$). However, an increase in the tone of the *gastrocnemius* muscle of animals from the exercised groups (I and III) was observed. This may be associated with a greater development of muscle fibers in the exercised animals, not reflected in the increase of the weight or size of the muscle, but associated with a reduction of other constituents such as muscular fat. This explains the results of our ultrasonographic study, which showed a similar low echogenicity of the *gastrocnemius* muscle between animals from groups exposed to MNU (groups I and II) ($p>0.05$). The tumors developed in animals of group I and II may have had a catabolic effect on body tissues associated with fat infiltration decrease, as suggested by previous studies (20). Tumors can produce molecules such as lipid-mobilizing factor which act on adipose tissue and proteolysis-inducing factor which acts on skeletal muscle (20). These findings agree with the results for myostatin, as its levels were higher in the MNU-treated groups. Myostatin is a hormone produced in muscle that affects the growth and metabolic state not only of muscle, but also of other body tissues, including fat (26). High myostatin levels have been described in conditions associated with muscle wasting, including cancer (27, 28).

The echogenicity of *gastrocnemius* muscle of animals from group III was similar to the groups exposed to MNU (groups I and II) due to the exercise training and consequent decrease of fat infiltration in muscle. Animals from group IV were healthy animals without exercise training, and consequently had a higher fat infiltration and muscle echogenicity. In accordance with other researchers, the echogenicity of ultrasonographic

images of the *gastrocnemius* muscle is always influenced by fat infiltration (13, 14).

In all groups, the echogenicity of the *gastrocnemius* muscle was lower than that of the tissue between the muscle and the tibia ($p<0.05$) due to the intrinsic characteristics of this tissue. This tissue is rich in fibrous tissue and fat and these tissues are responsible for increased reflections of the ultrasound beam and a consequent whiter appearance of the ultrasonographic images (13, 14). As observed in the *gastrocnemius* muscle, the highest echogenicity was detected in healthy sedentary animals (group IV), possibly also associated with the different fat content of groups at this location. As far as we are aware of previous studies only compared the echogenicity of the *gastrocnemius* muscle and the tissue between muscle and the tibia.

Our results showed that muscle ultrasonography is a useful tool to identify alterations in muscle structure. However, more studies are necessary to understand the influence of fat location in muscle ultrasonographic imaging.

Acknowledgements

This work was supported by the Portuguese Foundation for Science and Technology [grant number PTDC/DES/114122/2009], European Regional Development Found (COMPETE, FCOMP-01-0124-FEDER-014707/022692) and by FCT Pest-OE/AGR/UI0772/2011.

References

1 Wild J and Neal D: Use of high-frequency ultrasonic waves for detecting changes of texture in living tissues. Lancet *1*: 655-657, 1951.
2 Pillen S: Skeletal muscle ultrasound. Eur J Transl Myol *1(4)*: 145-155, 2010.
3 Pillen S, Verrips A, van Alfen N, Arts I, Sie L and Zwarts M: Quantitative skeletal muscle ultrasound: diagnostic value in childhood neuromuscular disease. Neuromuscular Disord *17*: 509-516, 2007.
4 Jacobson J: Ultrasound in sports medicine. Radiol Clin N Am *40(2)*: 363-386, 2002.
5 Lento P and Primack S: Advances and utility of diagnostic ultrasound in musculoskeletal medicine. Curr Rev Musculoskelet Med *1*: 24-31, 2008.
6 Nazarian L: The top 10 reasons musculoskeletal sonography in an important complementary or alternative tecnhique to MRI. Am J Roentgenol *190*: 1621-1626, 2008.
7 Middleton W, Payne W, Teefey S, Hildbolt C, Rubin D and Yamaguchi K: Sonography and MRI of the shoulder: Comparison of patient satisfaction. Am J Roentgenol *183(5)*: 1449-1452, 2004.
8 Bangard C, Paszek J, Berg F, Eyl G, Kessler J, Lackner K and Gossmann A: MRI imaging of claustrophobic patients in an open 1.0T scanner: Motion artifacts and patient acceptability compared with closed bore magnets. Am J Radiol *64*: 152-157, 2007.
9 Pillen S, Scholten R, Zwarts M and Verrips A: Quantitative skeletal muscle ultrasonography in children with suspected neuromuscular disease. Muscle Nerve *27*: 699-705, 2003.
10 Pillen S, Tak R, Zwarts M, Lammens M, Verrijp K, Arts I, van der Laak J, Hoogerbrugge P, van Engelen B and Verrips A: Skeletal muscle ultrasound: correlation between fibrous tissue and echo intensity. Ultrasound Med Biol *35(3)*: 443-446, 2009.
11 Pillen S, Arts I and Zwarts M: Muscle ultrasound in neuromuscular disorders. Muscle Nerve *37*: 679-693, 2008.
12 Lee J and Healy J: Sonography of lower limb muscle injury. Am J Roentgenol *182*: 341-351, 2004.
13 Peetrons P: Ultrasound of muscles. Eur Radiol 12: 35-43, 2002.
14 Reimers K, Reimers C, Wagner S, Paetzke I and Pongratz D: Skeletal muscle sonography: A correlative study of echogenicity and mosphology. J Ultras Med *12*: 73-77, 1993.
15 Hashimoto BE, Kramer DJ and Wiitala L: Applications of musculoskeletal sonography. J Clin Ultrasound *27(6)*: 293-318, 1999.
16 Benson J and Jatoi I: The global breast cancer burden. Future Oncol *8(6)*: 697-702, 2012.
17 Huggins C, Grand L and Brillantes F: Mammary cancer induced by a single feeding of polymucular hydrocarbons, and its suppression. Nature *189*: 204-207, 1961.
18 Gullino P, Pettigrew H and Grantham F: *N*-Nitrosomethylurea as mammary gland carcinogen in rats. J Natl Cancer Inst *54*: 401-414, 1975.
19 McCormick D, Adamowski C, Fiks A and Moon R: Lifetime dose response relationships for mammary tumor induction by a single administration of *N*-methyl-*N*-nitrosourea. Cancer Res *41*: 1690-1694, 1981.
20 Tisdale M: Pathogenesis of cancer cachexia. J Support Oncol *1(3)*: 159-168, 2003.
21 Larkin M: Thwarting the dwindling progression of cachexia. Lancet *351(9112)*: 1336, 1998.
22 Yeh J, Niu Q, Evans J, Iwamoto J and Aloia J: Effect of circular motion exercise on bone modeling and bone mass in young rats: an animal model of isometric exercise. J Musculoskelet Neuronal Interact *1(3)*: 235-240, 2001.
23 McArdle A, Vasilaki A and Jackson M: Exercise and skeletal muscle ageing: Cellular and molecular mechanisms. Ageing Res Rev *1(1)*: 79-93, 2002.
24 Tipton KD: Muscle protein metabolism in the elderly: Influence of exercise and nutrition. Can J Appl Physiol *26(6)*: 588-606, 2001.
25 Faustino-Rocha A, Oliveira P, Pinho-Oliveira J, Teixeira-Guedes C, Soares-Maia R, Gil da Costa R, Colaço B, Pires M, Colaço B, Ferreira R and Ginja M: Estimation of rat mammary tumor volume using caliper and ultrasonography measurements. Lab Animal (NY) *42(6)*: 217-224, 2013.
26 Roth SM and Walsh S: Myostatin: A therapeutic target for skeletal muscle wasting. Curr Opin Clin Nutr *7(3)*: 259-263, 2004.
27 Kirk S, Oldham J, Kambadur R, Sharma M, Dobbie P and Bass J: Myostatin regulation during skeletal muscle regeneration. J Cell Physiol *184(3)*: 356-363, 2000.
28 Aversa Z, Bonetto A, Penna F, Costelli P, Di Rienzo G, Lacitignola A, Baccino FM, Ziparo V, Mercantini P, Fanelli FR and Muscaritoli M: Changes in myostatin signaling in non-weight-losing cancer patients. Ann Surg Oncol *19(4)*: 1350-1356, 2012.

Received July 25, 2013
Revised October 18, 2013
Accepted October 21, 2013