

An Odontogenic Keratocystic Tumor in the Buccal Space: An Unusual Site of Origin and a Review of the Literature

ALEXANDER GRÖBE¹, HENNING HANKEN¹, MARCO BLESSMANN¹,
JOZEF ZUSTIN², MAX HEILAND¹ and AHMED AL-DAM¹

Departments of ¹Oral and Maxillofacial Surgery and

²Pathology, University Medical Center Hamburg-Eppendorf, Hamburg, Germany

Abstract. *Aim: Keratocystic odontogenic tumors (KCOTs) arise from remnants of epithelial structures associated with the development of teeth and occur predominantly intraosseously. In rare occasions they can appear extraosseously in the gingiva as peripheral counterparts; only 15 cases have been reported to date. Even more rare are cases of KCOTs of the buccal soft tissues. The aim of this report is to present a rare case of KCOT affecting the buccal soft tissue as an original site and a review of the literature regarding diagnostic and therapeutic options.*

Regarding the soft tissues of the face, few cases have been documented. The odontogenic origin is discussed contrary, epithelial origin of the skin, traumatic implantation of odontogenic cells are possible causes of this type of lesion. In all cases, incisional or excisional biopsies were obtained before surgical resection *via* intraoral access. Because of its rare incidence, a standard treatment protocol is still lacking and further multicenter studies are necessary.

Among a variety of cysts occurring in the head and neck region, the odontogenic keratocyst is of special interest because of its unique behavior. Its characteristics are potentially aggressive, infiltrative growth, with solitary or multicystic formations of odontogenic origin with high rates of recurrence up to 62.5% (1) and in some cases, this cyst appears to be syndromic. Therefore the World Health Organization reclassified the term of odontogenic keratocyst to keratocystic odontogenic tumor (KCOT) (2)

Correspondence to: Alexander Gröbe, MD, DMD, Department of Oral and Maxillofacial Surgery, University Medical Center Hamburg-Eppendorf, Martinistr. 52, D-20246 Hamburg, Germany. Tel: +49 40741053259, Fax: +49 40741055467, e-mail: a.groebe@uke.de

Key Words: Keratocystic odontogenic tumor, buccal space, unusual site of origin, case report.

in 2005. KCOTs can affect both maxilla and mandible, but in most cases the mandible, at a ratio of 2:1, has a predilection for the molar-ramus region. The male to female incidence ratio is 1.6:1 (3). Syndromic variants, typically nevoid basal cell carcinoma syndrome, occur at a younger age than sporadic ones, with a mean age from 38 to 40 years (4, 5).

These tumors arise from remnants of epithelial structures associated with the development of teeth and occur predominantly intraosseously. On rare occasions, they appear extraosseously in the gingiva as peripheral counterparts; only 15 cases have been reported in the literature so far (6-9). Even more rare are cases of KCOTs of the buccal mucosa occurring as a controversial entity of questionable existence (10).

The aim of this report is to present a rare case of KCOT affecting the buccal soft tissue as a site of origin and to perform a review of the current literature.

Case Report

A 52-year-old male patient, otherwise fit and with good health, presented with a painless swelling in the right cheek, significantly increasing in size over the previous 6 months. The history of swelling was not related to food intake, toothache did not exist, nor did night sweats, weight loss or other diseases or allergies.

Clinical bimanual examination revealed a solid nodular mobile mass of about 2×2×1 cm in size without affecting the borders of the parotid gland (Figure 1). There were no limitations in sensitivity or motor function. The mouth opening was undisturbed, and there was no deviation or deflection of the mandible in habitual occlusion. Intraorally, a good flow of normal saliva from the excretory Stenson duct was observed.

On the panoramic x-ray there was no evidence of an odontogenically-induced process. An external computed tomographic scan showed a marginal contrasted displaced oval mass in the soft tissue of the right cheek without bony involvement (Figure 2).

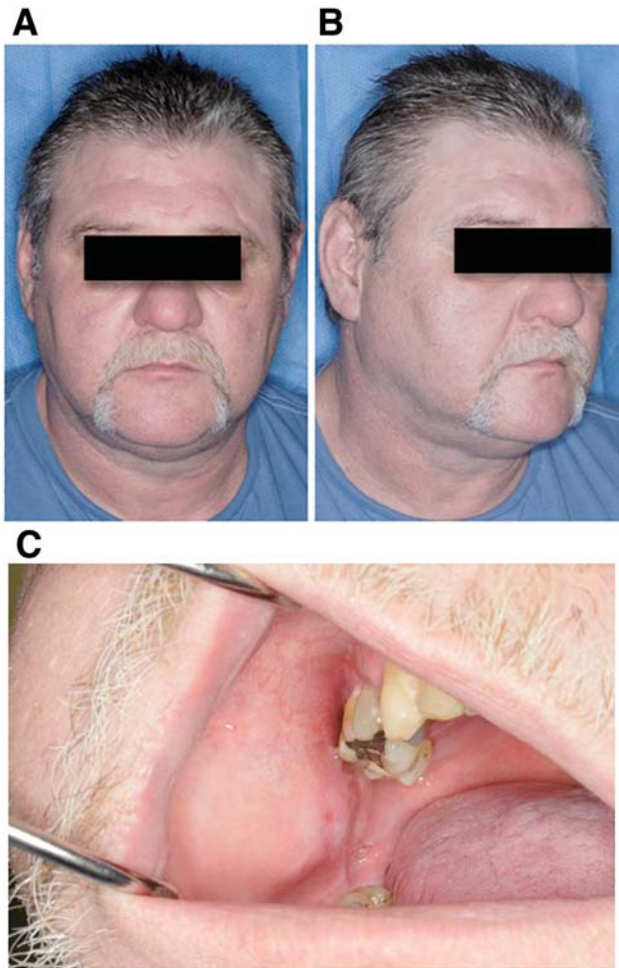


Figure 1. A-C: A 52-year-old male patient with a history of a painless swelling of the right cheek, significantly increasing in size.

One week after the initial presentation, the mass was excised *via* intraoral access. The mass was revealed after dissection through the buccinator muscle and was easily separated from the surrounding tissues. The cystic wall was perforated once during extirpation emptying gray-beige thick and cheesy content (Figure 3). The defect was primarily closed and the hollowing was corrected using a buccal fat pad as a pedicled graft. Surrounding structures, such as the parotid gland and the facial nerve were preserved.

The histopathological examination (haematoxylin & eosin staining) led to the diagnosis of a KCOT (Figure 4). The mass had parakeratinized stratified thin and friable squamous epithelium of 5-8 layers, with a weak interface between the epithelium and the connective tissue, and keratinized lamellae. The basal layer displayed palisading of cuboidal cells.

The patient has been without any signs of recurrence for four months.

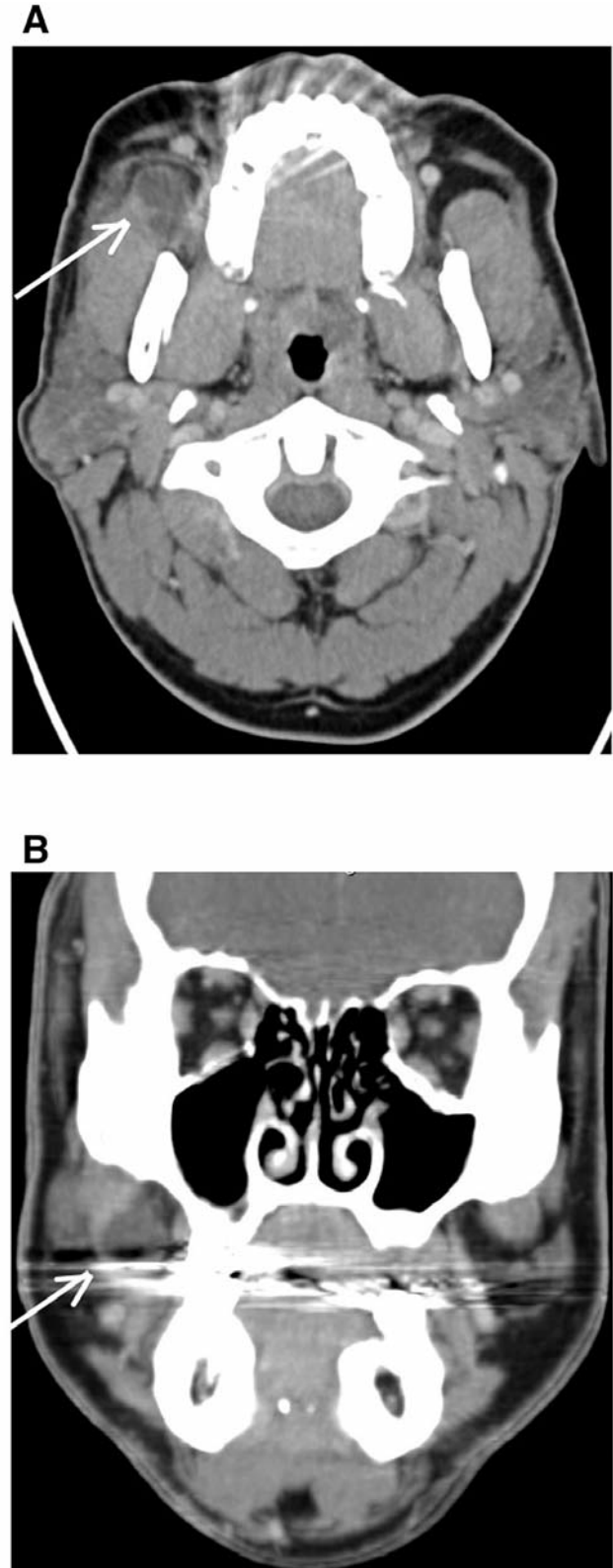


Figure 2. A, B: External computed tomography scan (Arrow): A marginal contrasted displaced oval mass in the area of the right cheek without bony involvement.

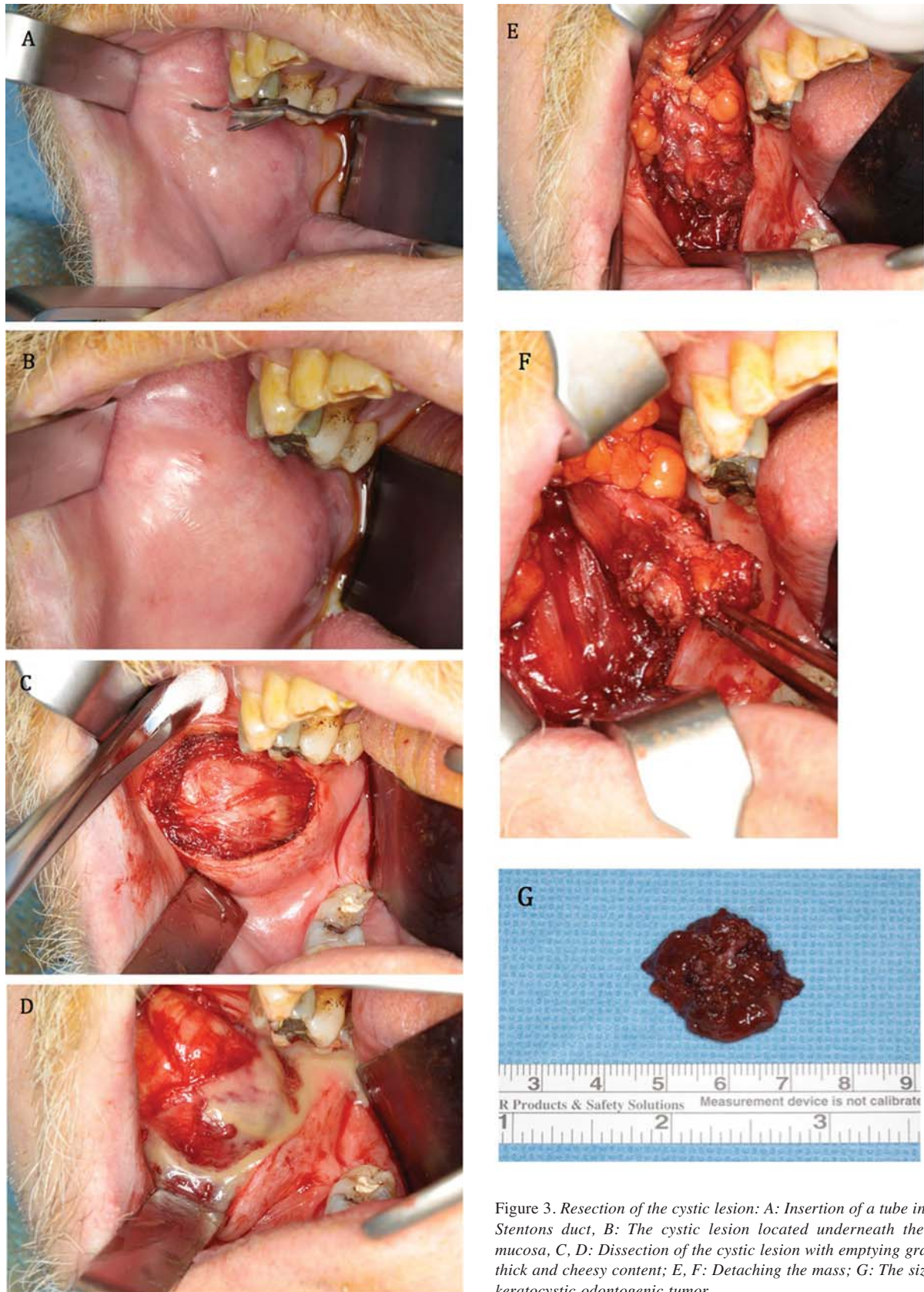


Figure 3. Resection of the cystic lesion: A: Insertion of a tube inside the Stentons duct, B: The cystic lesion located underneath the buccal mucosa, C, D: Dissection of the cystic lesion with emptying gray-beige thick and cheesy content; E, F: Detaching the mass; G: The size of the keratocystic odontogenic tumor.

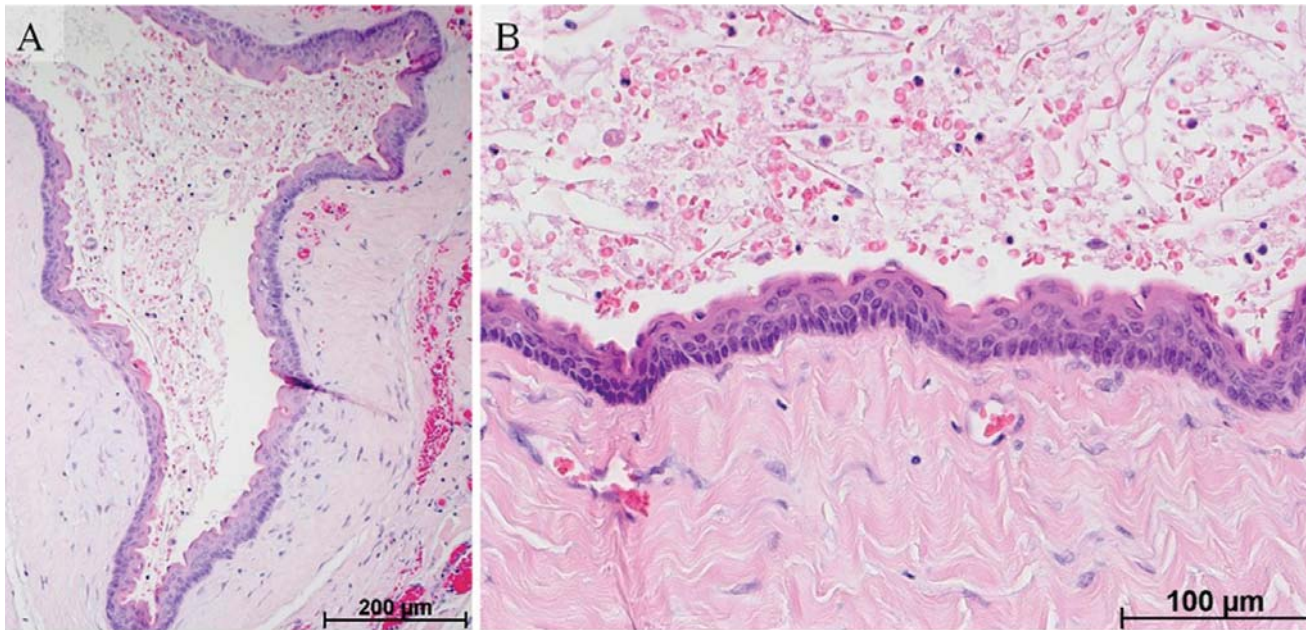


Figure 4. *Peripheral keratocystic odontogenic tumor (histopathology). A: The lesion shows a fibrous wall lined by stratified squamous epithelium with a corrugated parakeratinising surface. B: Under high power, columnar basal cells display palisaded nuclei without atypia. (A/B stain: hematoxylin-eosin, original magnification: A $\times 100$, B $\times 200$).*

Discussion

There are a variety of differential diagnostic considerations for a swelling of the cheek. Acute inflammatory and painful swellings are often caused by an odontogenic focus or a traumatic event. In these cases, individual patients medical history can provide important clues. Chronic painless swelling without primary involvement of the outer skin or the oral mucosa are observed less frequently. They are usually diagnosed as an incidental finding, especially if they exhibit an asymptomatic local growth. In addition, benign tumors and malignant lesions, such as pleomorphic adenoma and sarcoma, and carcinoma should always be excluded histopathologically. Therefore, a diagnostic biopsy is mandatory, and if possible, an excisional biopsy is advisable.

The histological findings of the present case were those characteristically exhibited by a typical KCOT. The evidence for an odontogenic origin is not obvious, although necessary for a definitive diagnosis. However, as the vestibular lamina integrates into the upper molar areas distal to the parotid duct during embryologic odontogenesis, an explanation could be displaced and persistent dental lamina rests (11, 12). Other authors have demonstrated the role of the patched gene (*PTCH*) in the etiology of KCOTs. In this context, they summarized an association of *PTCH* gene mutation and syndromic and sporadic forms of KCOTs; the *PTCH* gene encodes for a transmembrane protein operating in reverse to

the Hedgehog signaling protein which inhibits cell growth (13, 14). In cases of its mutation, proliferative and stimulating effects are no longer limited.

Treatment options for KCOTs have been discussed frequently over the past decades. Simple enucleation for intraosseous KCOTs has led to high recurrence rates. Curettage, cryotherapy, peripheral ostectomy, and application of chemical fixatives to the underlying bone are widely discussed and result in lower recurrence rates but also in increased morbidity (15-17). Decompression and marsupialization are beneficial in some circumstances and in addition to an irrigation protocol over 12 months have been proven to be a promising approach for large KCOTs (18). Surgical resection of the maxilla or mandible and microsurgical reconstruction of the resulting defect should be reserved for aggressive or recurrent lesions (19). Additional chemical fixation with Carnoy's solution reduces recurrence rates, however, its classical composition may possibly cause damage to adjacent tissues as well as systemic toxicity (20).

Reviewing the literature and according to some authors, peripheral KCOTs are considered to be less aggressive than their intraosseous counterparts (6), with simple surgical resection and excision of surrounding adherent soft tissue being justified. Concerning KCOTs within the soft tissues of the face, few case reports have been documented (3, 10, 21-23). Even the odontogenic origin is contrary discussed,

epithelial origin of the skin and traumatic implantation of odontogenic cells are possible causes (10, 21). In all reported cases, incisional or excisional biopsies were obtained before surgical resection *via* intraoral access. In one case, after enucleation, the overlying mucosa was excised as recommended by Stoelinga (24). No chemical fixatives or irrigation were used. Because of the rare incidence of this tumor entity and the lack of experience, a standard treatment protocol is still needed and further multicenter studies are necessary.

Conflict of Interest

The Authors declare, that there are no conflicts of interest. We hereby confirm, that we have read the Helsinki Declaration and have followed its guidelines in this investigation and that IRB was given for our study.

References

- Bell RB and Dierks EJ: Treatment options for the recurrent odontogenic keratocyst. *Oral Maxillofac Surg Clin North Am* 15(3): 429-446, 2003.
- Philipsen HP and Reichart PA: Classification of odontogenic tumours. A historical review. *J Oral Pathol Med* 35(9): 525-529, 2006.
- Eryilmaz T, Ozmen S, Findikcioglu K, Kandal S and Aral M: Odontogenic keratocyst: an unusual location and review of the literature. *Ann Plast Surg* 62(2): 210-212, 2009.
- Woolgar JA, Rippin JW and Browne RM: The odontogenic keratocyst and its occurrence in the nevroid basal cell carcinoma syndrome. *Oral Surg Oral Med Oral Pathol* 64(6): 727-730, 1987.
- Figueroa A, Correnti M, Avila M, Andea A, DeVilliers P and Rivera H: Keratocystic odontogenic tumor associated with nevroid basal cell carcinoma syndrome: Similar behavior to sporadic type? *Otolaryngol Head Neck Surg* 142(2): 179-183, 2010.
- Chehade A, Daley TD, Wysocki GP and Miller AS: Peripheral odontogenic keratocyst. *Oral Surg Oral Med Oral Pathol* 77(5): 494-497, 1994.
- Chi AC, Owings JR Jr and Muller S: Peripheral odontogenic keratocyst: Report of two cases and review of the literature. *Oral Surg Oral Med Oral Pathol Oral Radiol Endod* 99(1): 71-78, 2005.
- Dayan D, Buchner A, Gorsky M and Harel-Raviv M: The peripheral odontogenic keratocyst. *Int J Oral Maxillofac Surg* 17(2): 81-83, 1988.
- Ide F, Shimoyama T and Horie N : Peripheral odontogenic keratocyst: A report of 2 cases. *J Periodontol* 73(9): 1079-1081, 2002.
- Ide F, Kikuchi K, Miyazaki Y, Mishima K, Saito I and Kusama K: Keratocyst of the buccal mucosa: Is it odontogenic? *Oral Surg Oral Med Oral Pathol Oral Radiol Endod* 110(5): 42-47, 2010.
- Hovorakova M, Lesot H, Peterka M and Peterkova R: The developmental relationship between the deciduous dentition and the oral vestibule in human embryos. *Anat Embryol (Berl)* 209(4): 303-313, 2005.
- Hovorakova M, Lesot H, Vonesch JL, Peterka M and Peterkova R: Early development of the lower deciduous dentition and oral vestibule in human embryos. *Eur J Oral Sci* 115(4): 280-287, 2007.
- Shear M: The aggressive nature of the odontogenic keratocyst: Is it a benign cystic neoplasm? Part 3. Immunocytochemistry of cytokeratin and other epithelial cell markers. *Oral Oncol* 38(5): 407-415, 2002.
- Barreto DC, Gomez RS, Bale AE, Boson WL and De Marco L: *PTCH* gene mutations in odontogenic keratocysts. *J Dent Res* 79(6): 1418-1422, 2000.
- Stoelinga PJ: The treatment of odontogenic keratocysts by excision of the overlying, attached mucosa, enucleation, and treatment of the bony defect with carnoy solution. *J Oral Maxillofac Surg* 63(11): 1662-1666, 2005.
- Giuliani M, Grossi GB, Lajolo C, Bisceglia M and Herb KE: Conservative management of a large odontogenic keratocyst: Report of a case and review of the literature. *J Oral Maxillofac Surg* 64(2): 308-316, 2006.
- Kolokythas A, Fernandes RP, Pazoki A and Ord RA: Odontogenic keratocyst: To decompress or not to decompress? A comparative study of decompression and enucleation *versus* resection/peripheral osteotomy. *J Oral Maxillofac Surg* 65(4): 640-644, 2007.
- August M, Caruso PA and Faquin WC: Case records of the Massachusetts General Hospital. Case 40-2005. An 18-year-old man with a one-month history of nontender left mandibular swelling. *N Engl J Med* 353(26): 2798-805, 2005.
- Tolstunov L, Treasure T. Surgical treatment algorithm for odontogenic keratocyst: combined treatment of odontogenic keratocyst and mandibular defect with marsupialization, enucleation, iliac crest bone graft, and dental implants. *J Oral Maxillofac Surg* 66(5): 1025-1036, 2008.
- Pitak-Arnnp P, Chaîne A, Oprean N, Dhanuthai K, Bertrand JC and Bertolus C: Management of odontogenic keratocysts of the jaws: A ten-year experience with 120 consecutive lesions. *J Craniomaxillofac Surg* 38(5): 358-364, 2010.
- van der Wal KG: Development of a keratocyst in the facial soft tissues. *J Oral Maxillofac Surg* 43(8): 614-616, 1985.
- Worrall SF: Recurrent odontogenic keratocyst within the temporalis muscle. *Br J Oral Maxillofac Surg* 30(1): 59-62, 1992.
- Precheur HV and Krolls SO: An unusual presentation of an odontogenic keratocyst in the buccal space: Case report. *J Oral Maxillofac Surg* 67(11): 2513-2515, 2009.
- Stoelinga PJ: The treatment of odontogenic keratocysts by excision of the overlying, attached mucosa, enucleation, and treatment of the bony defect with carnoy solution. *J Oral Maxillofac Surg* 63(11): 1662-1666, 2005.

Received April 28, 2012

Revised July 3, 2012

Accepted July 4, 2012