in vivo *26*: 571-576 (2012)

Urokinase Plasminogen Activator, uPAR, MMP-2, and MMP-9 in the C6-Glioblastoma Rat Model

PATRICK J. SCHULER[1], MARTIN BENDSZUS[2], SIGLINDE KUEHNEL[3], SVEN WAGNER[4], THOMAS K. HOFFMANN[1], ROLAND GOLDBRUNNER[5] and GILES H. VINCE[3]

[1]*Department of Otorhinolaryngology, University of Duisburg-Essen, Essen, Germany;*
[2]*Department of Neuroradiology, University of Heidelberg, Heidelberg, Germany;*
[3]*Department of Neurosurgery, University of Würzburg, Würzburg, Germany;*
[4]*Sartorius Stedim Biotech GmbH, Göttingen, Germany;*
[5]*Department of Neurosurgery, University of Cologne, Cologne, Germany*

Abstract. *Background: In glioblastoma multiforme (GBM), the serine protease urokinase plasminogen activator (uPA), and matrix metalloproteases (MMP-2 / MMP-9) contribute to its invasive growth pattern, which is the major obstacle to successful surgical treatment. Materials and Methods: The expression of uPA was determined in monolayers and spheroids of the rodent GBM cell line C6 by immunohistochemistry and polymerase chain reaction (PCR). The longitudinal expression of proteases was studied in orthotopically implanted spheroids by semi-quantitative immunohistochemistry (IHC) in Sprague Dawley rats (n=40). The tumor volume was monitored by magnetic resonance imaging (MRI). Results: In vitro, the GBM cell line C6 expresses high levels of uPA. In vivo, a continuous increase of uPA, uPA-receptor (uPAR), MMP-2, and MMP-9 expression was found in the infiltration zone. uPA was located exclusively in the infiltration zone and in the vascular basal layers. The mean tumor volume 23 days after implantation was 3.2 mm^3. Conclusion: uPA, uPAR, MMP-2 and MMP-9 play an important role in GBM growth. Blockade of uPA and interruption of the proteolytic cascade could become a useful tool in the therapy of GBM.*

Glioblastoma multiforme (GBM) accounts for one of the most malignant human brain tumors with median survival time no longer than 50 weeks (1, 2). It is characterized by its invasiveness and the ability to infiltrate the contralateral hemisphere even in early tumor stages (3, 4). Therefore, GBM is resistant to any attempt for curative surgery without affecting vital brain structures.

The invasive growth of GBM relies strongly on the restructuring of the extracellular matrix (ECM). ECM restructuring typically involves three steps, adhesion, degradation and migration, and it is physiologically important in many different biological processes, such as wound healing, embryogenesis and inflammation (5). ECM restructuring is induced by the serine protease urokinase plasminogen activator (uPA) and is carried out by plasmin and various matrix metalloproteases (MMPs). Tumor cells regularly overexpress uPA, its receptor uPAR, MMP-2 and MMP-9, in order to infiltrate the newly created space after ECM degeneration (6). In the case of GBM, a prominent infiltration zone (IZ) is created between the solid tumor and normal brain tissue, containing multiple tumor cell aggregates which are potentially responsible for recurrent tumor growth. Adhesion of tumor cells to the ECM is decisively linked to uPAR. In addition to the uPA binding site, uPAR possesses a binding site for the matrix protein vitronectin, and it has a high affinity for the cell integrin $a_V\beta_3$. Binding of uPA to the uPAR multiplies the proteolytic activity of uPA for plasminogen cleavage by ten-fold, and therefore, the proteolytic activity of uPA is concentrated to the IZ (7). Thus, uPAR can be defined as a binding factor between ECM and uPA-induced proteolysis.

Based on current knowledge, uPA plays a prominent role in the proteolytic network due to its ability to activate several MMPs and plasmin. On the other hand, plasmin preferentially activates receptor-bound uPA as a form of positive feedback signal. By the activation of plasmin, uPA can indirectly promote the activation of MMPs and the degradation of ECM (8). MMPs are a structurally closely related category characterized by a zinc-ion complex in its proteolytic centre. So far, several MMPs (MMP-1, MMP-11, MMP-19) have been associated with human malignant glioma (9). Regarding the degradation of ECM, in particular

Correspondence to: Patrick Schuler, MD, Department of Otorhinolaryngology. University of Duisburg-Essen, Hufelandstr. 55, 45147 Essen, Germany. Tel: +49 2017232481, Fax: +49 2017235903, e-mail: patrick.schuler@uk-essen.de

Key Words: uPA, C6-glioma, rat model, infiltration, glioblastoma multiforme.

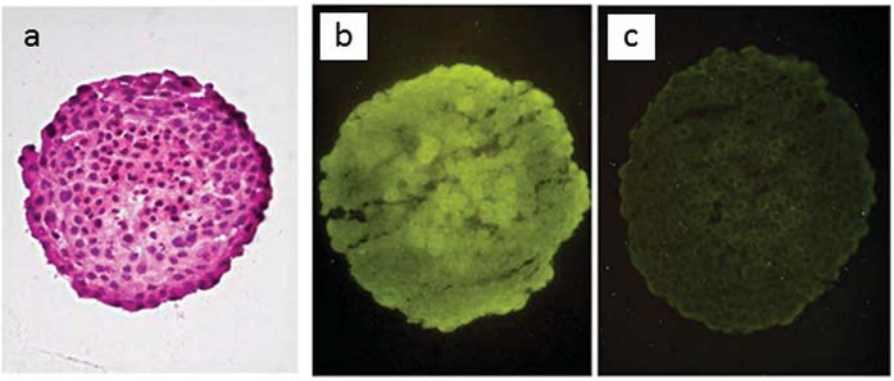

Figure 1. *Expression of urokinase plasminogen activator (uPA) and matrix metalloprotease (MMP-2) in spheroids of the C6 cell line, in vitro. a: Hemalaun-eosin staining with no evidence of central necrosis, b: fluorescence staining for uPA with homogenous distribution throughout the spheroid, and c: fluorescence staining for MMP-2. Magnification ×15.*

the group of gelatinases, including MMP-2 and MMP-9, are of major interest because of their strong proteolytic activity *in vitro* (9, 10).

Knowledge of the protease expression patterns during tumor growth could help to better understand the mechanisms of the proteolytic cascade, and could therefore help develop therapies to reduce the proteolytic activity in GBM (11). As a promoter of the proteolytic cascade and being a protease itself, uPA seems to be an appropriate target in order to prevent the degenerative activity of tumor growth (12).

Materials and Methods

Cell culture. The C6 cell line was purchased from ATCC (Manassas, VA, USA) and cultured in 15 mL Dulbecco's Modified Eagle Medium (DMEM, plus 10% fetal calf serum (FCS), amino acids, L-glutamine, 10,000 U/mL penicillin, 10,000 U/mL streptomycin) in 75-mL culture flasks at 37˚C with 5% CO_2. Under these conditions, C6 cells formed confluent monolayers after four days. For generation of cell spheroids, 75 mL culture flasks were coated with agar gel and 22 mL of culture medium were added to 8 mL of cell suspension, followed by 2:1 separation on day 2 into two new agar gel-coated culture flasks. After four days, spheroids had reached 300 μm ± 30 μm in diameter without central necrosis. Single spheroids were isolated under microscope control and kept for a maximum of three days under sterile conditions before implantation.

Animal experiments. The project was approved by the Ethics Committee of the University of Würzburg, Germany (AZ-621-2531.01 28/99). Spheroids (300 μm ± 30 μm) of the rodent C6 GBM cell line were orthotopically implanted into the left frontal lobe of 40 male Sprague Dawley rats (300 g ± 30 g body weight), obtained from Harlan Winkelmann (Borchen, Germany). Surgery was performed under sterile conditions, under microscope. Animals were anesthetized with an intramuscular injection of ketamin hydrochloride (100 mg/kg; Parke-Davis, Berlin, Germany) and xylazine (10 mg/kg; Bayer, Leverkusen, Germany). After cranial fixation with an in house-made mandible retainer and cranial skin incision, the periosteum was displaced and temporal bone trepanation was conducted in level with the coronal suture. Resection of the dura mater was followed by placing a spheroid into the crosswise incision of the cortex. Wound closure was performed with bone wax and skin suture.

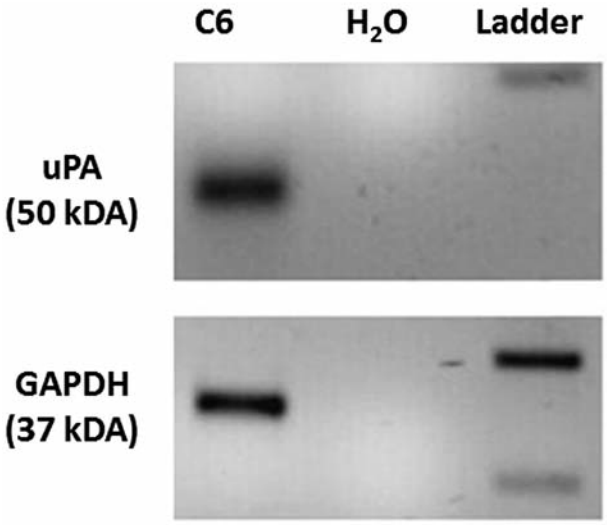

Figure 2. *Confirmation of urokinase plasminogen activator (uPA)-specific RNA expression, in vitro after reverse transcription to DNA, polymerase chain reaction (PCR) and gel electrophoresis. RNA specific for uPA was expressed in C6 wild-type cells.*

Animals were sacrificed on postoperative days (POD) 3 (n=5), 10 (n=15), 17 (n=15), or 23 (n=5) for determination of MMP-2, MMP-9, uPAR and uPA in the tumor core and of IZ, by semi-quantitative IHC on a scale from 0-3. Animals were sacrificed by intramuscular injection of 2 mL T61 (Intervet, Unterschleissheim, Germany), and the explanted brain was snap frozen in isopentane.

On POD 23, animals (n=5) were anesthetized as described above for magnetic resonance imaging (MRI) studies using a 1.5 Tesla unit

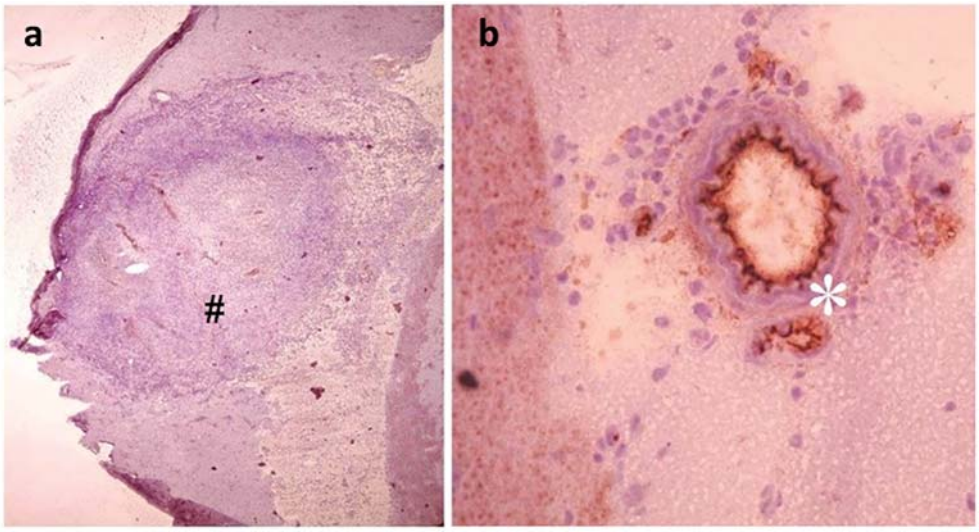

Figure 3. *Avidin-biotin complex-staining for urokinase plasminogen activator (uPA) at postoperative day 21. a: Overview of C6 tumor implanted into the left temporal lobe, with central necrosis (#, ×30). b: uPA is prominently located in the basal layer (*) of the intratumoral vessels (×100).*

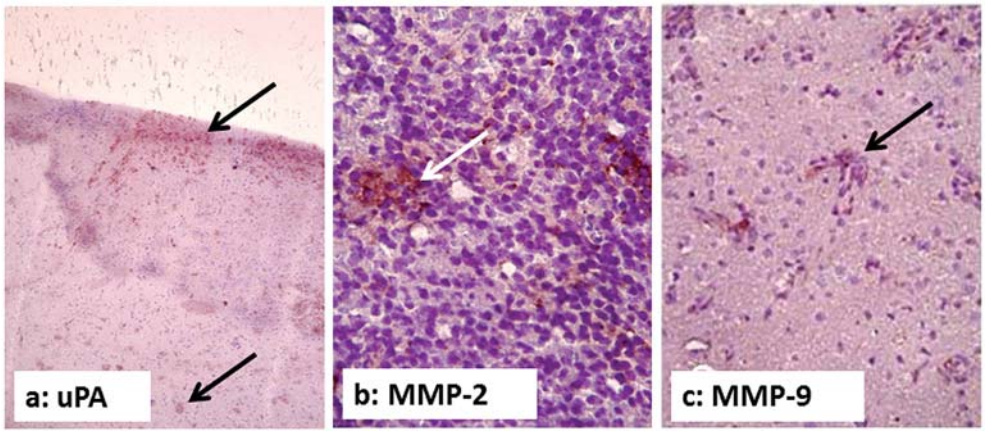

Figure 4. *Avidin-biotin complex-staining of implanted tumors on postoperative day 10. a: Urokinase plasminogen activator (uPA) is located in the tumor core and in the infiltration zone (×40). b: Strong expression of matrix metalloprotease MMP-2 in the tumor core (×60). c: MMP-9 in the infiltration zone (×60).*

(Magnetom VisionR; Siemens, Erlangen, Germany) with a round surface coil. The MRI protocol included a T2-weighted turbo spin echo sequence (slice thickness 3 mm, coronal plane), a T1-weighted spin echo sequence before and after application of contrast medium (slice thickness 3 mm, coronal plane), and a 'constructive interference in steady state' (CISS) 3D sequence for volumetry, as described previously (13). Tumor volumetry was performed by manually delimiting the tumor in every slice then multiplying by the slice thickness using the Virtuoso software (Siemens, Munich, Germany). Consequently, animals were sacrificed as described above and brains were explanted for IHC examination. No animals had to be sacrificed ahead of schedule due to extensive tumor growth or neurological deficits.

Immunohistochemistry. Cryopreserved tumor slides obtained from explanted rodent brain tissue were thawed, stained with hemalaun for 3 min, washed with sterile water for 10 min and then counterstained with eosin for 25 s (HE). Slides were then fixed with ethanol and covered with Eukitt mounting medium (EMS, Hatfield, PA, USA). For staining of cryopreserved C6 cell spheroids, primary antibodies for uPA sc-6831 (1:20), MMP-2 sc-8835 (1:50), and MMP-9 sc-6840 (1:50) (all overnight at 37˚C), were combined with secondary Fluoresceinisothiocyanat (FITC) antibody sc-2024 (1:100, 1 h at room temperature). All antibodies were purchased from Santa Cruz Biotech (Santa Cruz, CA USA). Slides were fixed with methanol and blocked with normal goat serum for 30 min before staining and mounted with fluorescent mounting medium

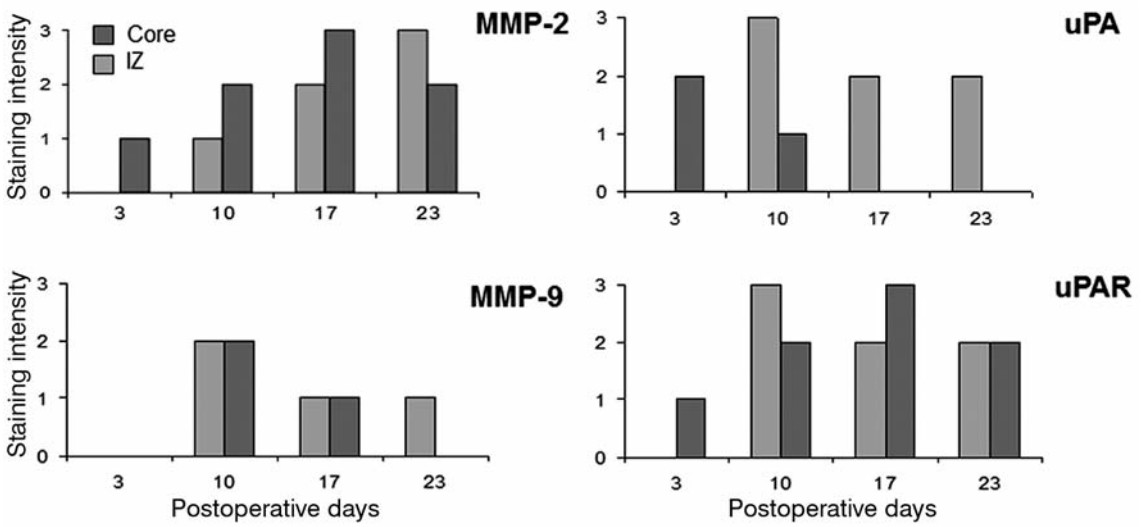

Figure 5. *Expression patterns of matrix metalloproteases MMP-2, MMP-9, urokinase plasminogen activator (uPA) and its receptor (uPAR) measured by immunohistochemistry on postoperative day 3 (n=5), 10 (n=15), 17 (n=15) and 23 (n=5) in the tumor center (core) and in the infiltration zone (IZ), after orthotopic implantation of C6 tumor spheroids. Expression was evaluated semi-quantitatively as the mean of ten consecutive visual fields at ×100 magnification by two independent investigators. The following grading system was applied: 0=no expression, 1=weak expression, 2=intermediate expression, 3=strong expression. MMP-2 and uPA appear early in tumor growth; MMP-9 and uPAR are expressed in late tumor stages.*

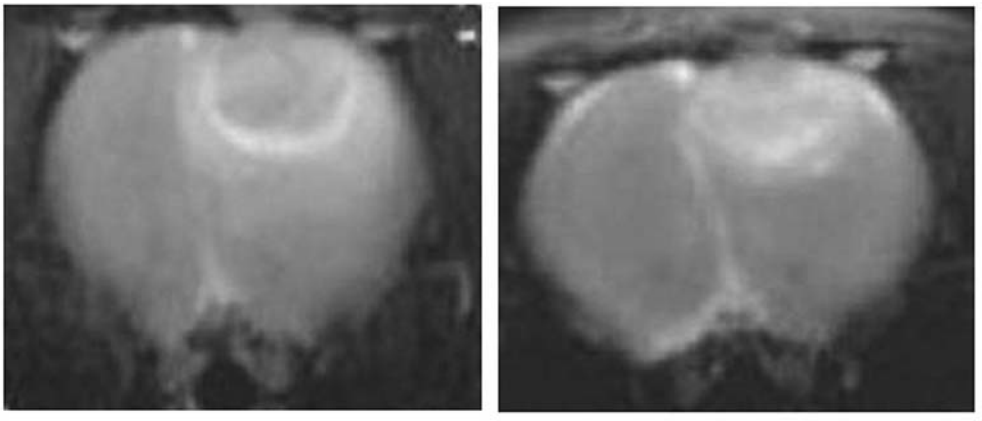

Figure 6. *T2-w magnetic resonance imaging (MRI) examination of implanted C6 glioblastoma multiforme spheroids in the left frontal lobe of two representative animals at postoperative day 23. After orthotopic implantation, the tumor lesion exhibits an intracerebral location with central necrosis and edema formation.*

(Zymed, San Francisco, CA, USA). For staining of cryopreserved rodent brain tumors, primary antibodies for uPA (1:50), MMP-2 (1:50), and MMP-9 (1:50) were combined with the Vector Elite ABC Kit (Vector Laboratories, Burlingame, CA, USA), as recommended by the distributor, followed by counterstaining with hemalaun for 10 min. A semi-quantitative scale (0-3) was applied by two independent investigators (GV, SK) for evaluation of the *in vivo* staining signal, defined by staining intensity and percentage of positive cells (0=negative, 1=low, 2=medium, and 3=strong).

PCR. C6 cell suspension was lysed with β-mercaptoethanol and guanidinium isothiocyanate and suspended with 70% ethanol before mRNA isolation on a silicone column. The gel membrane containing mRNA was washed twice with ethanol, and mRNA was isolated with H_2O plus diethylpyrocarbonate by centrifugation. RNA concentration was determined by photometry at 260 nm.

Reverse transcription of mRNA to DNA was performed by incubating 1 μg mRNA with Oligo-dT_{12-18}-Primer (2 μL) (Pharmacia-Biotech, Freiburg, Germany) and Random Hexamer Primer (1 μL) (Promega, Mannheim, Germany) in 5 μL diethylpyrocarbonate (DEPC)-treated H_2O for 10 min at 65˚C. The mixture was then cooled on ice. Next, 17 μL of the reverse transcription mix containing 1 μL Moloney Murine Leukemia Virus (M-MLV) reverse transcriptase (200 U/μL), 5 μl first strand buffer, 2.5 μL dithiothreitol (DTT, 0.1 M), 2.5 μl dNTP-Mix (dATP, dCTP, dGTP, dTTP), 0.8 μl RNasin, and 5.2 μl DEPC-treated H_2O (all

Gibco Life Technologies, Eggenstein, Germany) was added. The mixture was incubated at 37˚C for 70 min. To end the transcription process, the RT enzyme was denaturated by heat (3 min at 95˚C).

For PCR of uPA-specific DNA (157 base pairs), the primers AggTggCAgT-gAACTTggAg (sense) and gTATTggCCT-TTCCTCggTAA (antisense) were used. The ubiquitous enzyme, GAPDH, served as a positive control using TgTCAgCAAT-gCATCCTgCA (sense) and gCATgTCAgA-TCCACAACggAT (antisense, all TiB Molbiol, Berlin, Germany). The protocol was optimized to the following time and temperature settings: 94˚C (60 s), 56.7˚C (60 s), and 72˚C (80 s) for 40 cycles. Semi-quantitative analysis of DNA amplification was performed by gel electrophoresis (60 min, 100 V).

Results

Expression of uPA in vitro. The GBM cell line C6 expresses high levels of uPA *in vitro*, as shown on a protein basis by IHC. HE staining showed no evidence of central necrosis in the spheroids, and a homogenous contribution of uPA in the spheroids was seen by fluorescence staining. Compared to the serine protease uPA, the expression of the matrix metalloprotease MMP-2 was low in C6 spheroids as shown by fluorescence staining (Figure 1).

PCR. The presence of uPA-specific RNA in C6 tumor cells *in vitro* was measured by semi-quantitative PCR. Strong expression of uPA-specific RNA *in vitro* was shown by PCR results (Figure 2). GAPDH served as a positive control, and GAPDH-specific RNA was strongly expressed in both cell lines.

MMP-2, MMP-9, uPA and uPAR expression patterns in vivo. The orthotopically implanted tumor in the left temporal lobe can be seen to be well-confined on POD 23 (Figure 3a), and expression of uPA is prominent in the basal layer of infiltration vessels (Figure 3b). Expression of MMP-2, MMP-9, uPA and uPAR was measured in the tumor core and in IZ by semi-quantitative IHC on POD 3 (n=5), 10 (n=15), 17 (n=15) and 23 (n=5), *in vivo* (Figure 4). On POD 3, MMP-2 and MMP-9 were not expressed in the IZ. For both MMPs, expression in the core and in IZ was highest on POD 10 and 17, whereas expression was regressive on POD 23. For uPA, core expression reached its peak on POD 3 and IZ expression was highest on POD 10. No core expression was detected after POD 10. Expression of uPAR in the core and in IZ increased continuously until POD 23, when core expression dropped to minimum. In summary, MMP-2 and uPA appear early in tumor growth, whereas MMP-9 and uPAR are expressed in later stages. uPA is only found in the IZ of the tumor and expression of uPA decreases in the tumor core as tumor growth progresses (Figure 5).

MRI volumetry of tumor. Animals 36-40 were examined by MRI on POD 23 for volumetric analysis. After orthotopic spheroid implantation, tumors exhibited an intracerebral location, with characteristic circular enhancement of contrast medium and central necrosis (Figure 6). In MRI examinations, all animals had tumor growth (n=5), with a mean tumor volume of 3.2 mm^3.

Discussion

To our knowledge, this is the first time that the expression patterns of uPA, uPAR, MMP-2 and MMP-9 have been described in the C6 glioma rodent model *in vivo* and *in vitro*. The localization of uPA to the prominent IZ and the intratumoral vessel walls is in accordance to findings in human cancers (10), and it supports the importance of uPA for the infiltrative growth pattern of GBM, as well as for angiogenesis. Therefore, this model is considered to be valid for further studies with the aim of examining infiltrative tumor growth, tumor-induced angiogenesis, and anti-proliferative therapies.

Of the examined proteases, uPA makes the earliest appearance in the tumor core, being apparent as early as POD 3. Expression of MMP-2 and MMP-9 increase in the tumor core upon uPA expression, which fosters the theory that uPA activates MMPs for ECM degradation (6). MMP activation can be executed directly by uPA (14) or indirectly by plasmin activation, which in turn can cleave MMPs into their active form (8).

uPA expression is strictly focused at the edge and to the IZ of the tumor, which is in accordance with the data obtained by others (15, 16). The rapid decrease of uPA expression in the tumor core might be due to the fact that certain trigger mechanisms for uPA (*e.g.* vitronectin) are not available in the core as tumor growth advances. This is not true for the uPA receptor, as uPAR expression was detected in the tumor core throughout the experiment. It appears that the presence of uPAR alone is not sufficient to attract uPA. Interestingly, even MMP-9, but not MMP-2, disappeared from the tumor core as tumor growth continued. Therefore, MMP-9 activity might be more dependent on the presence of uPA than MMP-2 or, alternatively, MMP-2 might have a longer half-life than MMP-9 in the tumor cells.

Besides its importance for cell migration and ECM degradation, uPA plays an important role in neoangiogenesis (17). Vascular endothelial cells express uPA with the aim to destabilize the vessel wall which then allows for sprouting of new vessels. Furthermore, uPA supports neoangiogenesis by intracellular cell signaling and induction of cell adhesion and migration (18). Therefore, the finding of uPA in the basal layer of vessels within the tumor indicated a rich neovascularisation, which is characteristic of GBM.

The results of the present study indicate that the serine protease uPA is essential for ECM degradation and that inhibition of uPA may be able to reduce the invasive growth

pattern of GBM. This hypothesis calls for verification by applying a serine protease inhibitor, *e.g.* WX-UK1 (Mesupron®), in the C6 glioblastoma rat model. Serine protease inhibitors block the proteolytic center of uPA in a competitive manner, and they have been proven to efficiently inhibit tumor growth as well as metastasis, in animal models of a variety of extracerebral solid tumors (19).

The brain is a unique tumor environment in many ways, and none of the available uPA inhibitors has yet been proven to be able to pass the blood brain barrier and effectively prevent the invasive growth pattern of malignant brain tumors. Moreover, in contrast to other tumor locations, altered composition of serine proteases (*e.g.* trypsin) in the brain might lead to increased non-specific binding of drugs, which then have no effect on tumor growth. In contrast to humans, in animal models, *i.p.* drug administration is favored as it prevents emesis and spilling of the drug, and the successful administration of *i.p.* serine proteases in rodents has been shown by others (20). Nevertheless, uPA inhibitors might display different uptake characteristics than other tested serine proteases, which could result in an unfavorable biodistribution of the drug. Therefore, decreased biodistribution due to *i.p.* drug application and the location of an intracerebral tumor have to be considered when applying uPA inhibitors in animal brain tumor models.

References

1 Jeremic B, Milicic B, Grujicic D, Dagovic A, Aleksandrovic J and Nikolic N: Clinical prognostic factors in patients with malignant glioma treated with combined modality approach. Am J Clin Oncol *27*: 195-204, 2004.

2 Krex D, Klink B, Hartmann C, Deimling AV, Pietsch T, Simon M, Sabel M, Steinbach JP, Heese O, Reifenberger G, Weller M and Schackert G: Long-term survival with glioblastoma multiforme. Brain Oct *130*: 2596-2606, 2007.

3 Steltzer KJ, Sauve KI, Spence AM, Griffin TW and Berger MS: Corpus callosum involvement as a prognostic factor for patients with high-grade astrocytoma. Int J Radiat Oncol Biol Phys *38*: 27-30, 1997.

4 Kallenberg K, Bock HC, Helms G, Jung K, Wrede A, Buhk JH, Giese A, Frahm J, Strik H, Dechent P and Knauth M: Untreated glioblastoma multiforme: increased myo-inositol and glutamine levels in the contralateral cerebral hemisphere at proton MR spectroscopy. Radiology *253*: 805-812, 2009.

5 Ny T, Wahlberg P and Brandstrom IJ: Matrix remodeling in the ovary: regulation and functional role of the plasminogen activator and matrix metalloprotease systems. Mol Cell Endocrinol *187*: 29-38, 2002.

6 Rao JS: Molecular mechanisms of glioma invasiveness: the role of proteases. Nat Rev Cancer *3*: 489-501, 2003.

7 Mazar AP: The urokinase plasminogen activator receptor (uPAR) as a target for the diagnosis and therapy of cancer. Anticancer Drugs *12*: 387-400, 2001.

8 Ulisse S, Baldini E, Sorrenti S and D'Armiento M: The urokinase plasminogen activator system: a target for anti-cancer therapy. Curr Cancer Drug Targets *9*: 32-71, 2009.

9 Vince GH, Wagner S, Pietsch T, Klein R, Goldbrunner RH, Roosen K and Tonn JC: Heterogeneous regional expression patterns of matrix metalloproteases in human malignant gliomas. Int J Dev Neurosci *17*: 437-445, 1999.

10 Gondi CS and Rao JS: Therapeutic potential of siRNA-mediated targeting of urokinase plasminogen activator, its receptor, and matrix metalloproteases. Methods Mol Biol *487*: 267-281, 2009.

11 Mekkawy AH, Morris DL and Pourgholami MH: Urokinase plasminogen activator system as a potential target for cancer therapy. Future Oncol *5*: 1487-1499, 2009.

12 Gorantla B, Asuthkar S, Rao JS, Patel J and Gondi CS: Suppression of the uPAR-uPA system retards angiogenesis, invasion, and *in vivo* tumor development in pancreatic cancer cells. Mol Cancer Res *9*: 377-389, 2011.

13 Goldbrunner RH, Bendszus M, Sasaki M, Kraemer T, Plate KH, Roosen K and Tonn JC: Vascular endothelial growth factor-driven glioma growth and vascularization in an orthotopic rat model monitored by magnetic resonance imaging. Neurosurgery *47*: 921-929, 2000.

14 Zhao Y, Lyons CE Jr., Xiao A, Templeton DJ, Sang QA, Brew K and Hussaini IM: Urokinase directly activates matrix metalloproteases-9: a potential role in glioblastoma invasion. Biochem Biophys Res Commun *369*: 1215-1220, 2008.

15 Sandstrom M, Johansson M, Sandstrom J, Bergenheim AT and Henriksson R: Expression of the proteolytic factors, tPA and uPA, PAI-1 and VEGF during malignant glioma progression. Int J Dev Neuroscience *17*: 473-481, 1999.

16 Yamamoto M, Sawaya R, Mohanam S, Rao VH, Bruner JM, Nicolson GL, Ohshima K and Rao JS: Activities, localizations, and roles of serine proteases and their inhibitors in human brain tumor progression. J Neurooncol *22*: 139-151, 1994.

17 Parfyonova Y, Plekhanova O, Solomatina M, Naumov V, Bobik A, Berk B and Tkachuk V: Contrasting effects of urokinase and tissue-type plasminogen activators on neointima formation and vessel remodelling after arterial injury. J Vasc Res *41*: 268-276, 2004.

18 Tkachuk VA, Plekhanova OS and Parfyonova YV: Regulation of arterial remodeling and angiogenesis by urokinase-type plasminogen activator. Can J Physiol Pharmacol *87*: 231-251, 2009.

19 Reuning U, Sperl S, Kopitz C, Kessler H, Kruger A, Schmitt M and Magdolen V: Urokinase-type plasminogen activator (uPA) and its receptor (uPAR): development of antagonists of uPA/uPAR interaction and their effects *in vitro* and *in vivo*. Curr Pharm Des *9*: 1529-1543, 2003.

20 Tamao Y and Kikumoto R: Effect of argatroban, a selective thrombin inhibitor, on animal models of cerebral thrombosis. Semin Thromb Hemost *23*: 523-530, 1997.

Received March 29, 2012
Revised May 25, 2012
Accepted May 28, 2012