

# Association of Vacuum-assisted Closure and Platelet Gel for the Definitive Surgical Repair of an Enterocutaneous Fistula: A Case Report

MARCO SCALA<sup>1</sup>, FRANCESCO SPAGNOLO<sup>2</sup>, MARIA TRAPASSO<sup>2</sup>,  
PAOLO STRADA<sup>3</sup>, LUCIANO MORESCO<sup>4</sup> and PIERLUIGI SANTI<sup>4</sup>

<sup>1</sup>Division of Surgical Oncology and <sup>2</sup>Division of Plastic Surgery,  
National Institute of Cancer Research (IST), Genova, Italy;

<sup>3</sup>Blood Trasfusion Centre, St. Martino Hospital, Genova, Italy;

<sup>4</sup>Faculty of Medicine, University of Genova, Genova, Italy

**Abstract.** *Background: Regenerative surgery deals with damaged tissue via endogenous cell activation or through autologous cell implantation. Several clinical applications employing cell infusions, platelet gel (PG), or both, are currently applied in cases in which no other therapy is application. The vacuum-assisted closure (VAC) system is a non invasive device used in the management of complicated wounds, which creates sub-atmospheric pressure promoting the wound healing process. Patients and Methods: We describe the case of a 75-year-old woman who underwent several surgical interventions and presented a non-healing ileo-cutaneous fistula. All standard procedures in order to treat the trauma failed, so a treatment associating VAC and PG was performed. Discussion and Conclusion: VAC and PG represent promising opportunities for the treatment of difficult wounds. In this case, the association of regenerative medicine using homologous PG to the VAC therapy was employed in order to enhance the effect of both techniques on tissue repair.*

Regenerative surgery deals with damaged tissue via endogenous cell activation or through autologous cell implantation. It can be considered a relatively new branch, born in 1997 when Whitman *et al.* (1) proposed integrating platelet-enriched plasma (PRP) into fibrin glue. In 1998, Marx *et al.* (2) demonstrated that PRP was able to induce

bone regeneration of the jaw. At the same period, it was discovered that a fraction of stem cells of bone marrow origin was able to repair several mesenchymal tissues or organs.

Regenerative medicine/surgery can be considered as a 'trait de union' between basic research, tissue engineering and clinics, representing a good example of translational research. It is based on the employment of either stem cells with multipotent differentiating potential and/or biological products such as PRP, or its gel formulation, platelet gel (PG) that have the ability to induce the migration of stem cells to the damaged tissue, in order to stimulate their proliferation and eventually achieve tissue repair. In some cases, particularly in bone regeneration, in addition to PRP and/or stem cells, it is necessary to add to some biomaterials that besides having a support function operate as a guide for stem cells to obtain a spatial repair (3).

Tissue repair is an extremely complex biological process in which several factors interplay: age, site and depth of the lesion, and co-morbidity (*e.g.*: diabetes, concomitant infections) (4). Such a complex process is facilitated by so-called growth factors (GF), molecules of crucial importance that interplay and exchange biochemical information. GFs are produced by cells involved in the regenerative process and, when they reach an appropriate concentration, they trigger the reparation process. Cells sensitive to GFs migrate into the site of the lesion and give rise to supporting tissue and extracellular matrix, while endothelial precursor cells give rise to newly formed vessels (neo-angiogenesis) (4).

Several clinical applications employing cell infusions, PG, or both, sometimes in combination with biomaterials, are nowadays possible and are currently applied in cases in which no other therapy is applicable. These clinical applications are now cumulatively called Regenerative Medicine. Modern techniques employed in regenerative medicine involve the use of various fractions of autologous

*Correspondence to:* Marco Scala, S.C. Oncologia Chirurgica A, Istituto Nazionale per la Ricerca sul Cancro, L.go R. Benzi, 10, 16132 Genoa, Italy. Tel: +39 0105600728, Fax: +39 0105600850, e-mail: marco.scala@hotmail.it

**Key Words:** Platelet gel, VAC therapy, regenerative surgery, fistula, wound healing.

stem cells, biomaterials and PRP/PG, alone, or in combination. Clinical applications in which the best results have been obtained are vascular surgery, maxillofacial surgery, orthopedic surgery and esthetic medicine.

In fact, in addition to their well-known functions in hemostasis, platelet- $\alpha$ -granules release GFs, such as platelet-derived growth factor (PDGF), transforming growth factor beta 1 (TGF  $\beta$ 1) and transforming growth factor beta 2 (TGF  $\beta$ 2), epidermal growth factor (EGF), insuline-like growth factor (IGF) and fibroblast growth factors (FGF), which promote tissue regeneration. (5-6). These proteins regulate various processes involved in wound healing and tissue regeneration by regulating cell proliferation, cell differentiation, angiogenesis, matrix deposition and tissue remodeling (7).

PG use is mostly widespread in dentistry and oral-maxillofacial surgery, where it is used for implantation and bone regeneration (8, 9). Similarly, the use of PG is greatly expanding in orthopedic surgery (10). PG is also indicated for difficult wound healing, such as chronic cutaneous ulcers, diabetes foot ulcerations (11) and other chronic non-healing wounds (12), in the reduction of postoperative pain (13), in the treatment of soft tissue traumas and in soft tissue and bone reconstruction (14). PG can be obtained using different techniques according to clinical indications and needed quantity: from a single unit of whole blood, from a buffy coat pool, or by apheresis. As a laboratory product, platelet gel is easy and safe to use (15). Addition of cryoprecipitate, thrombin and excess of  $\text{Ca}^{++}$  to PRP triggers the coagulation cascade, eventually resulting in the formation of a thrombus-like gelatinous substance (PG) (14). Platelet GFs released by the  $\alpha$  granules following platelet aggregation (or following platelet disruption because of cryopreservation-thawing procedures) promote mesenchymal stem cell recruitment, initiating the tissue healing process (5-7). The PG can be shaped according to need, put on different vehicles, such as medical gauze, or even on advanced types of biocompatible carriers and scaffolds (14).

The vacuum-assisted closure (VAC) system is a non invasive device used in the management of complicated wounds; it creates sub-atmospheric pressure, promoting and accelerating the healing process. The technique utilizes an open-pored black hydrophobic polyurethane foam which is inserted into the wound. Alternatively, and depending on the size of the wound, a hydrophilic polyvinyl alcohol foam with smaller and denser pores may be used. A transparent and semi-occlusive adhesive film is put over the dressing in order to avoid air contact and to create a partial void inside the foam. Afterwards, a suction tube is secured to the wound over a small opening of the adhesive film. One extremity of the suction tube is connected to an aspiration device, which delivers a controlled negative pressure of -50 to -125 mmHg. The exudates reach the device by travelling through the foam

due to the negative pressure, which can be applied constantly or intermittently. The foam dressing is normally changed every 2 or 3 days. It is imperative that devitalized tissue is constantly removed and the wound is constantly drained: a cultural examination should be performed on the exudates.

The use of a VAC system is associated with accelerated development of granulation tissue, since it provides a humid and closed environment, which is optimal for the healing process of the wounds, and reduction of edema both by reduction of inhibiting factors in the interstitial space (chemical process) and by the decompression of small vessels, with re-establishment of perfusion (mechanical process). The final result is the reduction of the wound size due to contraction and approaching of the edges (16).

Traditional indications for this therapy are postoperative abdominal wounds; chronic, pressure, vascular and neuropathic ulcers; chronic diabetic foot ulcers; surgical dehiscence; muscular flaps and cutaneous grafts. VAC therapy should be employed in the pre-treatment of wounds planned to be reconstructed with split thickness skin graft, since it has marked advantages in the wound bed preparation compared with the traditional normal saline gauze dressings (17, 18).

## Case Report

We describe the case of a 75-year-old woman who underwent several surgical interventions for diverticulitis and presented a non-healing ileo-cutaneous fistula. She was first admitted with a clinical diagnosis of peritonitis: a computed tomographic (CT) scan showed severe diverticulitis, the presence of sigmoid-vesical and sigmoid-vaginal fistulas and a covered sigma perforation with a 1.5x5 cm abscess. An exploratory laparotomy showed purulent peritonitis and the presence of a pseudotumoral sigmoid lesion adherent to the uterus. A series of surgical procedures were performed after the resolution of the peritonitis, including sigmoidal resection, two abdominal wall reconstructions and a Brooke ileostomy. A high-volume enterocutaneous fistula was the major complication of these interventions: although all standard procedures were performed in order to treat it, the trauma continued to wide with an increasing loss of ileal material (Figure 1).

An association of a VAC system and PG was attempted to heal the fistula. Initially, the VAC system was applied to the whole area of the fistula in order to drain the contaminating materials and promote the development of granulation tissue (Figure 2). As granulation tissue began to appear, PG was placed close to the edges of the wound and in the cavity around the fistulous tracks and covered with a patch containing hyaluronic acid (Figure 3). The PG was obtained from a unit (450 ml) of whole blood, collected two days before the operation at the Immunohematology Service. The

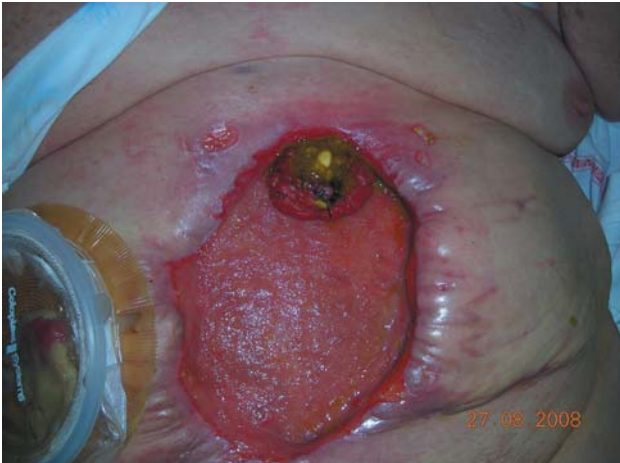

Figure 1. Patient presented a high-volume enterocutaneous fistula associated to a large loss of substance in the abdominal region.

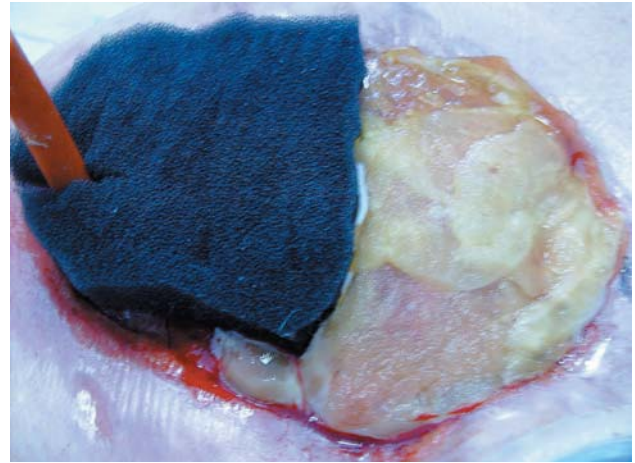


Figure 3. Platelet Gel was placed close to the edges of the wound and in the cavity around the fistulous tracks and covered with a patch containing hyaluronic acid.

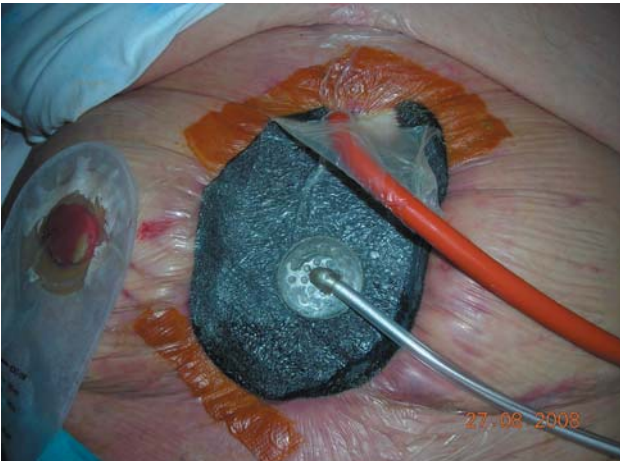

Figure 2. The VAC system was applied to the whole area of the fistula in order to drain the contaminating materials and promote the development of granulation tissue.

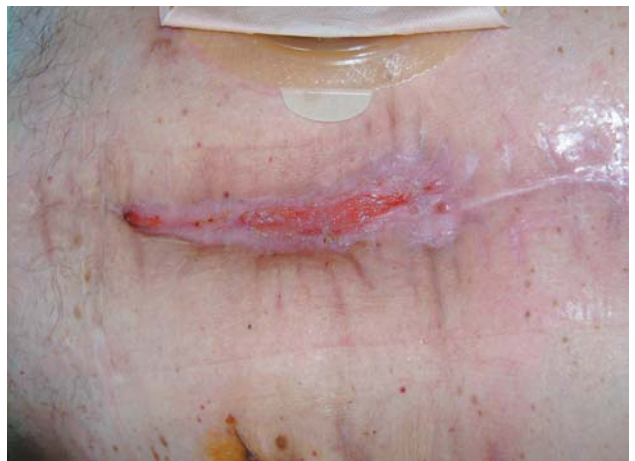

Figure 4. The fistula was almost completely healed at the time of discharging the patient.

blood was immediately centrifuged to obtain packed red blood cells (PRBCs) and PRP. PRBCs were reinfused to the patient. PRP was centrifuged to obtain platelet-poor plasma (PPP) and platelet-concentrate (PC). PPP was immediately frozen at  $-80^{\circ}\text{C}$  in a deep freeze refrigerator; then the frozen plasma (FFP) was left at  $4^{\circ}\text{C}$  for 18 h for spontaneous thawing. Cryodepleted plasma was removed and the residual cryoprecipitate was dissolved in 30 ml of plasma. PC was conserved at  $22^{\circ}\text{C}$  with continuous agitation.

In regards to the quality control of the product, PC had a platelet count equal to  $60 \times 10^9$ , a residual leucocyte count equal to  $0.2 \times 10^9$ , and a maximum volume of 30 ml. The

cryoprecipitate had factor VIII content equal to 70 UI/100 ml, fibrinogen equal to 140 mg/unit, and a maximum volume of 30 ml.

The PG was prepared as follows: 5 ml of PC was mixed with 5 ml of cryoprecipitate in a sterile plastic Petri dish; 1 ml of autologous thrombin was added for every 10 ml of PC-cryoprecipitate solution; then 1 ml of calcium gluconate was added every for 10 ml of PC-cryoprecipitate solution.

The contents of the Petri dish were then mixed in order to obtain a gel-like material in 10-15 min.

PG was applied four times about every 20 days. At each application, the wound area was smaller until, at last, the



Foley catheter was removed and the remaining cavity was filled with PG. As shown in Figure 4, the fistula had almost completely healed at the time of discharging the patient.

## Discussion and Conclusion

Platelet derivatives represent a promising therapeutic modality, offering opportunities for treatment of wounds, ulcers, soft-tissue and bone injuries, and various other applications in regenerative surgery. The use of PG is widespread in centers throughout the world, where its applications are most often linked to the physicians' perceived notion of clinical benefit. Hence the attention that regenerative surgery and medicine with PG is receiving, is progressively increasing but it is tempered by the absence of well-designed randomized trials that could assess the efficacy of this technique. The quality of recent clinical studies and case reports should promote the initiation of such clinical trials and therapies with PG and will probably expand both in the extent and in the variety of indications.

As shown by several recent clinical studies and case reports (11-14), VAC therapy may also be a useful therapeutic strategy for a variety of clinical issues whose management is difficult with current standard treatments.

In conclusion, the VAC system and PG represent promising therapeutic modalities, offering opportunities for the treatment of difficult wounds. In this case, we applied the combination of regenerative medicine using homologous PG with VAC therapy in order to enhance the effect of both techniques on tissue repair. As this case revealed, their use in combination could be indicated in order to manage particularly challenging clinical issues.

## Disclosure

Marco Scala, M.D., Francesco Spagnolo, M.D., Maria Trapasso, M.D., Paolo Strada, M.D. and Pierluigi Santi, M.D. have no financial interest in any of the products, devices, or drugs mentioned in this article.

## References

- Whitman DH, Berry RL and Green DM: Platelet gel: an autologous alternative to fibrin glue with applications in oral and maxillofacial surgery. *J Oral Maxillofac Surg* 55(11): 1294-1129, 1997.
- Marx RE, Carlson ER, Eichstaedt RM, Schimmele SR, Strauss JE and Georgeff KR: Platelet-rich plasma: Growth factor enhancement for bone grafts. *Oral Surg Oral Med Oral Pathol Oral Radiol Endod* 85(6): 638-646, 1998.
- Ripamonti U, Tsiroidis E, Ferretti C, Kerawala CJ, Mantalaris A and Heliotis M: Perspectives in regenerative medicine and tissue engineering of bone. *Br J Oral Maxillofac Surg* 49(7): 507-509, 2011.
- Singer AJ and Clark RA: Cutaneous wound healing. *N Engl J Med* 341: 738-746, 1999.
- Jurk H, Kehrel BE: Platelets: physiology and biochemistry. *Semin Thromb Hemost* 31: 381-92, 2005.
- Harrison P and Cramer EM: Platelet alpha-granules. *Blood Rev* 7: 52-62, 1993.
- Stammers AH, Trowbridge CC, Marko M, Woods EL, Brindisi N, Pezzuto J, Klayman M, Fleming S and Petzold J: Autologous platelet gel: fad or savoir? Do we really know? *J Extra Corpor Technol* 41: 25-30, 2009.
- Anitua E: The use of plasma-rich growth factors (PRGF) in oral surgery. *Int J Oral Maxillofac Implants* 14(4): 529-535, 1999.
- Scala M, Gipponi M, Pasetti S, Dellachá E, Ligorio M, Villa G, Margarino G, Giannini G and Strada P: Clinical applications of autologous cryoplatelet gel for the reconstruction of the maxillary sinus. A new approach for the treatment of chronic oro-sinusal fistula. *In Vivo* 21(3): 541-7, 2007.
- Cenni E, Savarino L, Perut F, Fotia C, Avnet S and Sabbioni G: Background and rationale of platelet gel in orthopaedic surgery. *Musculoskelet Surg* 94(1): 1-8, 2010.
- Akingboye AA, Giddins S, Gamston P, Tucker A, Navsaria H and Kyriakides C: Application of autologous derived-platelet rich plasma gel in the treatment of chronic wound ulcer: diabetic foot ulcer. *J Extra Corpor Technol* 42(1): 20-29, 2010.
- Frykberg RG, Driver VR, Carman D, Lucero B, Borris-Hale C, Fylling CP, Rappl LM and Clausen PA: Chronic wounds treated with a physiologically relevant concentration of platelet-rich plasma gel: a prospective case series. *Ostomy Wound Manage* 56(6): 36-44, 2010.
- Crovetti G, Martinelli G, Issi M, Barone M, Guizzardi M, Campanati B, Moroni M and Carabelli A: Platelet Gel for healing cutaneous chronic wounds *Transfus Apher Sci* 30: 145-151, 2004.
- Rozman P and Bolta Z: Use of platelet growth factors in treating wounds and soft-tissue injuries. *Acta Dermatovenerol Alp Panonica Adriat* 16(4): 156-165, 2007.
- Cervelli V, Gentile P and Grimaldi M: Regenerative Surgery: Use of fat grafting combined with platelet-rich plasma for chronic lower-extremity ulcers. *Aesthetic Plast Surg* 33(3): 340-345, 2009.
- Mouës CM, Heule F and Hovius SE: A review of topical negative pressure therapy in wound healing: sufficient evidence? *Am J Surg* 201(4): 544-556, 2011.
- Subramonia S, Pankhurst S, Rowlands BJ and Lobo DN: Vacuum-assisted closure of postoperative abdominal wounds: a prospective study. *World J Surg* 33(5): 931-937, 2009.
- Saaq M, Hameed-Ud-Din, Khan MI and Chaudhery SM: Vacuum-assisted closure therapy as a pretreatment for split thickness skin grafts. *J Coll Physicians Surg Pak* 20(10): 675-679, 2010.

Received August 23, 2011

Revised October 21, 2011

Accepted October 24, 2011