**in vivo** *24*: 877-882 (2010)

# Desmoid-type Infantile Fibromatosis of the Mandible: Case Report with Long-term Follow-up

REINHARD E. FRIEDRICH[1], ULRICH GRZYSKA[2], HANNA A. SCHEUER[3] and JOZEF ZUSTIN[4]

*Departments of [1]Oral and Maxillofacial Surgery, [2]Neuroradiology, [3]Orthodontics and [4]Pathology, Eppendorf University Hospital, University of Hamburg, Germany*

**Abstract.** *A 6-year-old girl was referred to Eppendorf University Hospital because of a suspected malignant mandibular tumour. An osteolytic lesion was depicted on panoramic radiograph in the premolar region. The tumour was resected with covering skin and the defect was closed by primary intention. Histological investigation revealed fibromatosis. No local recurrence of infantile fibromatosis occurred during seven years of follow-up. The differential diagnosis of fibro-osseous lesion of the facial region is challenging. Especially in children, caution should be exercised in the treatment of benign lesions that resemble malignant conditions derived from connective tissue, with special reference to long-term follow-up.*

Infantile fibromatosis of the facial skeleton is a rare diagnosis. This disease is a circumscribed, proliferative, well-differentiated entity consisting of fibrous tissue that is believed to originate from the muscles, fasciae or the periosteum (1). A serious aspect of infantile fibromatosis is the ability of the condition to invade adjacent structures and to recur in cases of incomplete excision. Neither clinical aspects nor radiographic findings are conclusive and histological diagnosis is often difficult to perform. Fibromatosis is an umbrella term that covers a broad range of entities with a biological behaviour spanning benign, self-limiting fibrous lesions and fibrosarcomas (2). Infantile fibromatosis is an aggressive fibromatosis (AF) of children and adolescents. The predominant sites that give rise to infantile fibromatosis are the anterior abdominal wall, the shoulders and upper arms (3). The percentage of head and neck lesions in studies on this entity varies between 10% and 45% (1, 4-7.) Any age group can be affected by fibromatosis. However, there is a predilection for children (4, 8, 9) and young adults (10), and about 25% of head and neck fibromatosis occurs in children (11). The recurrence rate depends on the state of the surgical margins and differs between 41 and 80% (12, 13).

Infantile fibromatosis is classified into diffuse and desmoid subtypes. The diffuse type is more frequently diagnosed and the histological phenotype is dominated by premature fibroblasts and a low collagen contingent, corresponding to the infiltrative growth. The desmoid type consists predominantly of extensive extracellular matrix and shows low cellularity (14).

This report describes the case of a child with a desmoid-type infantile fibromatosis of the mandible with long-term follow-up.

*Correspondence to:* Professor Dr. Reinhard E. Friedrich, Oral and Maxillofacial Surgery, Eppendorf University Hospital, University of Hamburg, Martinistr. 52, 20246 Hamburg, Germany. Tel: +49 40741053259, Fax: +4940741058120, e-mail: rfriedrich@uke.uni-hamburg.de

*Key Words:* Infantile fibromatosis, jaw tumour, immunohistochemistry, panoramic radiograph.

## Case Report

*Clinic*. The 6-year-old female patient was referred to Eppendorf University Hospital due to a firm mass adhering to the right side of the mandible that was first noticed about a year previously. On admission, the integument was intact, showed no local inflammation but had an impressive asymmetry between both sides of the chin region (Figure 1). On palpation, a small tough mass was palpable that could not be moved in relation to the mandible. The intraoral soft tissues were not affected and the mental nerve function was intact. The positions of the teeth inside the dental arch were symmetrical. The teeth of the affected region were entrenched to the mandible and reacted promptly on adequate stimuli. The mass was palpable in the right side of the floor of the mouth.

*Radiology*. On the panoramic radiograph the lower border of the right side of the mandible caudal to the premolar/molar region showed irregularity of the cortex. A spicula-like radiodense structure at the anterior border of the osseous lesion appeared as an expansion of the bone while

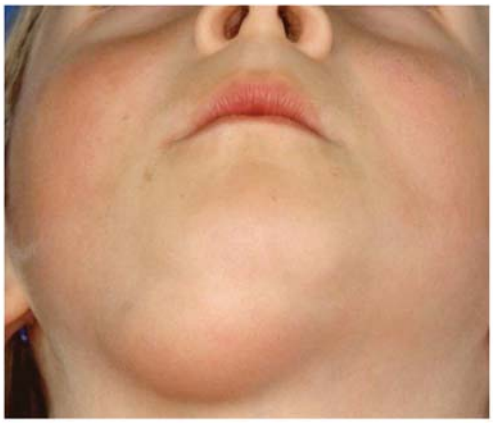

Figure 1. *Prominent submandibular tumour of the right side in a 6-year-old-girl.*

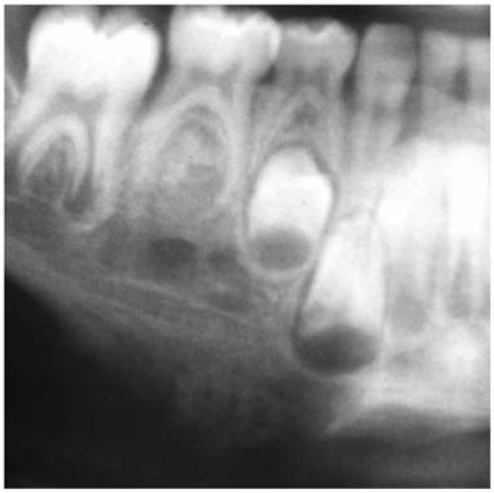

Figure 2. *Detail of panoramic radiograph at the time of first investigation. The inferior rum of the mandible showed an expansive bone-like mass with osteolytic zone.*

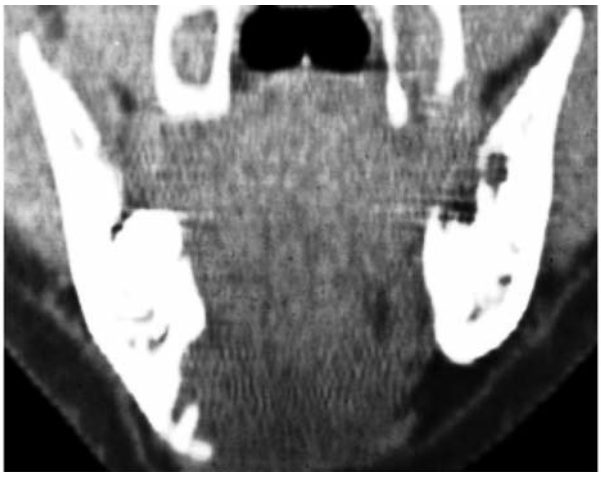

Figure 3. *Computed tomography coronal section of the mandible showing a lingual defect with caudal displacement of the bone on the right side.*

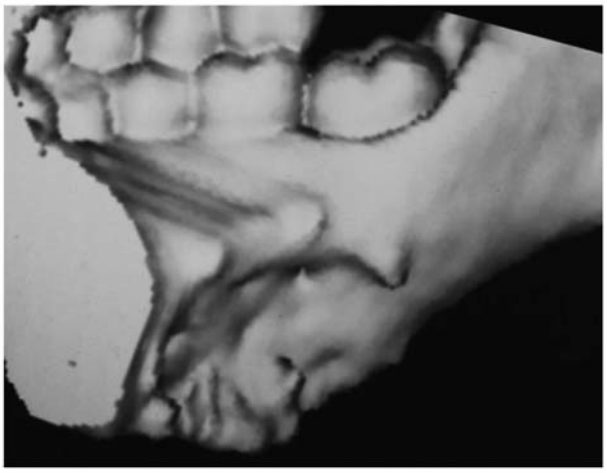

Figure 4. *Computed tomogram of the mandibular surface depicting the lingual lesion and bone-like particles at this site.*

maintaining the radiopacity of the cortex. This cortex sign passed abruptly over to the osteolytic zone. Protrusions isointense to spongious bone and in continuity to the mandible were depicted inside these empty spaces of the inferior mandibular border. Radiographic imaging was in favour of a malignant tumour. The germ of the permanent teeth in this region was not affected (Figure 2).

Coronal sections of computed tomograms revealed a lingual semicircular defect of the inferior site of the mandible in the right premolar region (Figures 3 and 4) with surrounding strands of bone-like particles. Computed tomograms of the reconstructed mandibular surface showed the lingual osseous defect of the affected side (Figure 5). Tentative diagnosis was osteosarcoma.

*Therapy.* In order to validate the diagnosis and to avoid a visible scar, an intraoral approach was chosen and a biopsy was taken from the soft tissue and adjacent bone. Intraoperatively, the firm soft tissue mass exhibited a pseudocapsular demarcation to the muscle, but apparently adhered to the mandible. The histological diagnosis was an infantile fibromatosis with tumour cells in the excision margins. As a consequence, complete excision of the lesion was planned via an extraoral approach in due consideration to maintain adequate safety margins to the lesion. The spindle-shaped skin defect was created and the tough soft tissue tumour was excised (Figure 5A-C), together with the lower rim of the mandible, leaving the tooth germs untouched. The situs showed the osseous defect as depicted on

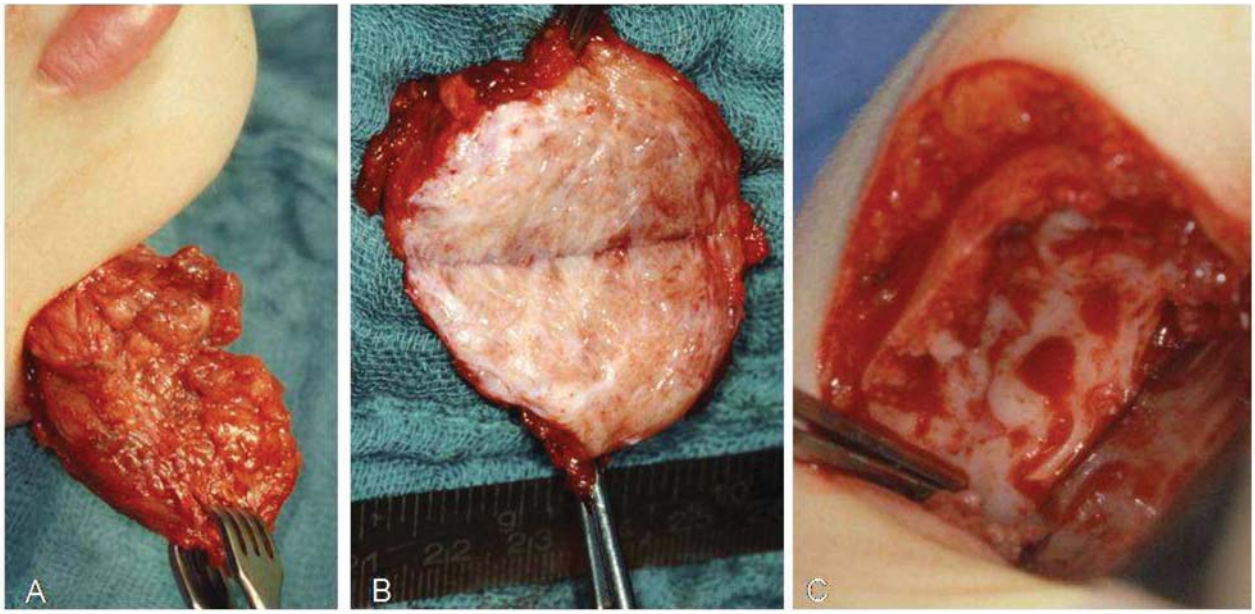


Figure 5. *Intraoperative view of the excision of the tumour (A), cross section of the excised tumour (B) and a view from the bottom onto the lingual osseous defect (C).*

radiograms (Figure 6). Mental nerve function was intact after marginal mandibulectomy. Healing was uneventful. The patient was regularly seen in the outpatient clinic. Follow-up showed a symmetrical growth of the mandible and undisturbed development of teeth (Figure 7). Seven years later there were no signs of local recurrence.

*Histology*. Surgically removed tissue was immediately fixed in formalin and sent to the histopathological laboratory. Histopathology revealed a moderately cell rich proliferation of fibroblastic spindle cells arranged in distinct fascicles with focal deposition of collagen (Figure 7A). Blood vessels were not prominent. Extensive nodular mesenchymal proliferative cells with regions of fascicular growth patterns included small capillaries. Occasionally multinucleated cells were present in the tumour, in particular in the vicinity of entrapped and regressively altered skeletal muscle fibres. The cells had pale staining nuclei with 1-3 minute nucleoli and eosinophilic cytoplasm. Necrosis or atypical mitoses were not present. Fat tissue was not found intralesionally. The resected bone from the inferior border of the mandible showed spongious bone but no invasive tumour.

Immunohistochemical analysis (Table I) showed a positive reaction for vimentin and focal positivity for smooth muscle actin (Figure 7B), with inconspicuous proliferative activity (Figure 7C). The proliferation index in terms of Ki-67 labelled cells was low. Tumour cells were negative for S-100 but nerve fibres were stained. Beta-catenin was detected in the cytoplasm only.

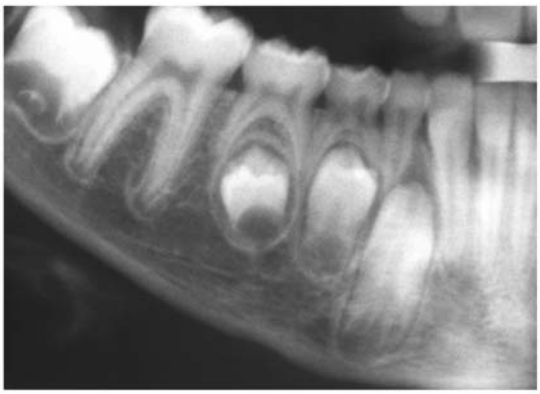

Figure 6. *Detail of panoramic radiograph taken 3 years after surgery showing the regenerated inferior rim of the mandible and the normal development of teeth.*

## Discussion

This report described the successful surgical treatment of a child with mandibular infantile fibromatosis. This type of fibromatosis occurring in children and adolescents was delineated as a clinical entity by Stout (15) and is a subtype of AF (10). A distinction between 'abdominal fibromatosis' and 'extra-abdominal fibromatosis' is of prognostic value: patients affected with the extra-abdominal type appear to have a better event-free survival (16). About 7 to 15% of AF

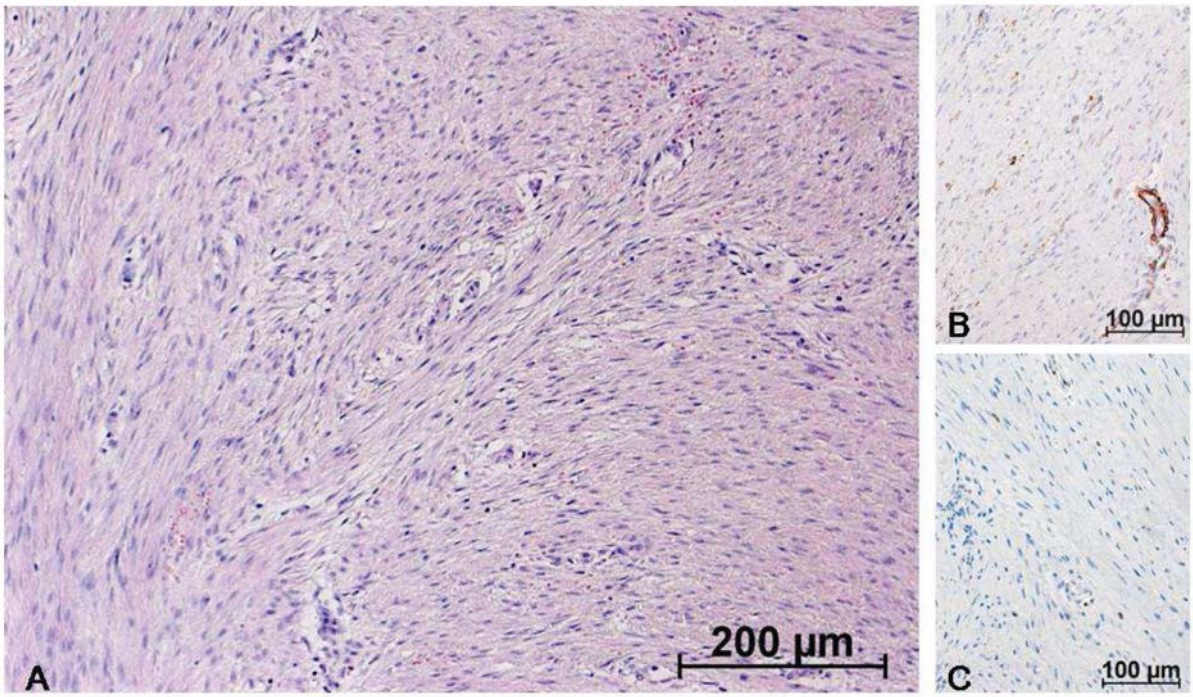


Figure 7. *Histopathological findings of mandibular infantile fibromatosis. A: Under low power magnification, interlacing bundles of fibroblastic spindle cells and small vessels with mild perivascular oedema were apparent (haematoxylin-eosin, original magnification: ×100). B: Immunohistochemically, intralesional blood vessel walls and focal fibroblasts were positive for smooth muscle actin (original magnification: ×200). C: Proliferative activity was low, with less than 5% positive nuclei for MIB1 (Ki-67, original magnification: ×200).*

develop in the head and neck region, thereof about 26% derived from the perimandibular soft tissues (7, 17, 18). Reviews on infantile fibromatosis are usually based on case reports and studies with small patient numbers. In one report, a preference for the maxilla was demonstrated as the site of origin of this entity (9). Seper *et al*. (10) published a review on 53 cases of AF of the jaw. The mandible was more frequently affected than the maxilla (43:10), according to their investigation. The review of Seper *et al*. (10) included AF of all age groups. Nine out of 53 patients were older than 20 years and 31 patients were 5 years of age or younger at the time of diagnosis (10). Recurrence is expected to occur predominantly in the first year after surgery (1).

The biological profile of fibromatosis varies considerably, with reports both about spontaneous regression (7) and extremely aggressive growth (14). Aetiology and pathogenesis are poorly understood. The neoplastic cells of infantile fibromatosis are believed to be derived from the musculoaponeurotic system (1-3) and have the capacity to invade tissues locally without developing distant metastases (4, 8).

Immunohistochemistry does not influence the differential diagnosis substantially, because both benign and malignant fibrous lesions are able to express vimentin and actin (10).

Table I. *Immunohistochemical reactivity of spindle cells within the lesion.*

| Target antigen | Clone/Antibody | Source | Dilution | Result |
|---|---|---|---|---|
| Vimentin | V9/ MO725 | Dako | 1:1000 | +++ |
| S-100 | Z0311 | Dako | 1:1000 | - |
| SMA | 1A4/M0851 | Dako | 1:400 | + |
| Desmin | D33/M0760 | Dako | 1:50 | - |
| CD 34 | Q BEnd 10/M7165 | Dako | 1:25 | - |
| CD117/c-kit | A4502 | Dako | 1:400 | - |
| β-Catenin | CAT-5H10 | Zymed | 1:50 | - |
| MIB1 | MIB-1/M7240 | Dako | 1:400 | <5% |

The mitotic index in terms of Ki-67-labelled tumour cells is lower than 5% in AF (10). Mitosis appears not to be a reliable index for the exclusion of malignancy in this age group (1).

Infantile fibromatosis of the jaws appears on plain radiographs as a radiolucent lesion in the majority of published cases (7, 10, 19, 20, 21). However, in rare cases an unexpected radiopacity of the jaw may also be an indicator of infantile fibromatosis, at least in the maxilla (9). Bony involvement is not always apparent on radiographs (4),

in particular in treatment of local recurrences of the tumour (10). Additional imaging is recommended such as B-scan ultrasound, magnetic resonance imaging and computed tomography, depending on the localisation of the space occupying lesion (8, 10). In this case, radiological investigations revealed a displacing growth of the tumour that matched the lingual defect of the mandible exactly. Long-term follow-up is indicated to document cure from this rare condition.

## References


1 Batsakis JG: Tumors of the Head and Neck, Williams and Wilkins, Baltimore, pp. 256-258, 1980.
2 Enzinger FM and Weiss SW: Fibrous tumors of infancy and childhood. *In*: Soft Tissue Tumors (3rd edition). Enzinger FM, SW Weiss (eds.). St. Louis, MO, Mosby-Year Book, pp. 231-268, 1995.
3 Shafer WG, Hine MK and Levy BM: A Textbook of Oral Pathology, 4th edition. Churchill Livingston, pp. 171-172, 1983.
4 De Santis D. Fibromatosis of the mandible: case report and review of previous publications. Br J Oral Maxillofac Surg *36*: 384-388, 1998.
5 Coffin CM and Dehner LP: Fibroblastic-myofibroblastic tumors in children and adolescents. A clinicopathologic study of 108 examples in 103 patients. Pediatr Pathol *11*: 569-588, 1991.
6 Vally IM and Altini M: Fibromatoses of the oral and paraoral soft tissues and jaws. Review of the literature and report of 12 new cases. Oral Surg Oral Med Oral Pathol *69*: 191-198, 1990.
7 Carr RJ, Zaki GA, Leader MB and Langdon JD: Infantile fibromatosis with involvement of the mandible. Br J Oral Maxillofac Surg *30*: 257-262, 1992.
8 Krokidis M, Raissaki M, Mantadikis, Giannikaki E, Velegrakis G, Kalmanti M and Gourtsoyiannis N: Infantile fibromatosis of the mandible: a case report. Dentomaxillofac Radiol *37*: 167-170, 2008.
9 Ogunsalu C and Barclay S: Aggressive infantile (desmoid-type) Fibromatosis of the maxilla. West Indian Med J *54*: 337-340, 2005.
10 Seper L, Hoppe P, Kruse-Lösler B, Büchter A, Joos U and Kleinheinz J: Aggressive Fibromatose im Kiefer-Gesichts-Bereich mit ossärer Beteiligung. Mund Kiefer Gesichtschir *9*: 349-362, 2005.
11 Conley J, Healey WV and Stout AP: Fibromatosis of the head and neck. Am J Surg *112*: 609-614, 1966.
12 Dormans JP, Spiegel D, Meyer J, Asada N, Alman BA, Pill SG, Himelstein B and Womer R: Fibromatoses in childhood: the desmoids/fibromatosis complex. Med Pediatr Oncol *37*: 126-131, 2001.
13 Janinis J, Patriki M, Vini L, Aravantinos G and Whela JS: The pharmacological treatment of aggressive fibromatosis: a systematic review. Ann Oncol *14*: 181-190, 2003.
14 Allen PW: The fibromatoses: a clinicopathological classification based on 140 cases. Am J Surg Pathol *1*: 305-311, 1977.
15 Stout AP. Juvenile fibromatosis. Cancer *7*: 953-978, 1954.
16 Meazza C, Bisogno G, Gronchi A, Fiore M, Cecchetto G, Alaggio R, Milano GM, Casanova M, Carli M and Ferrari A: Aggressive fibromatosis in children and adolescents: the Italian experience. Cancer *116*: 233-240, 2010.
17 Peterschulte G, Lickfeld T and Möslein G: The desmoid problem. Chirurg *71*: 894-903, 2000.
18 Reitamo JJ, Scheinin TM and Häyry P: The desmoid problem: new aspects in the cause, pathogenesis and treatment of the desmoid tumor. Am J Surg *15*: 230-237, 1986.
19 Pindborg JJ and Hjorting-Hansen E: Atlas of Diseases of the Jaws. Philadelphia, WB Saunders, p. 64, 1975
20 Wilkins SA, Waldron CA, Mathew WH and Droulias CA: Aggressive fibromatosis of the head and neck. Am J Surg *130*: 412-415, 1975.
21 Melrose RJ and Abram AM: Juvenile fibromatosis affecting the jaws. Report of three cases. Oral Surg *49*: 317-324, 1980.


*Received February 22, 2010*
*Revised April 12, 2010*
*Accepted April 22, 2010*