

Epithelioid Angiosarcoma of the Scapula

J. BÜRCK¹, U. GERLACH², T. BAUMANN¹, M. LANGER¹ and J. T. WINTERER¹

¹Department of Diagnostic Radiology and

²Department of Pathology, University Hospital Freiburg, 79095 Freiburg, Germany

Abstract. Epithelioid angiosarcoma is a rare variation of an angiosarcoma and its localization in the bone is exceptionally infrequent. This report presents the case of a 48-year-old male with an epithelioid angiosarcoma of the scapula. In CT and MRI scans an inhomogeneous tumour with osseous destructions, lytic areas, central necrosis and marginal hyperperfusion was observed. The bordering skeletal muscles were already infiltrated. The tumour was treated initially with neoadjuvant chemotherapy, followed by dose escalation, peripheral blood stem cell transplantation and resection of the lesion. Despite advanced local tumour stage at initial presentation, the patient is in complete remission.

Angiosarcoma accounts approximately for 2% of all soft tissue sarcomas affecting most frequently the head, neck, irradiated breast, pelvis and extremities (1). The epithelioid angiosarcoma is a rare variation of angiosarcoma that can occur in many different sites, such as thyroid gland, skin, adrenal gland and deep soft tissues (1, 2). However, the bone is a very rare primary site of origin and makes up only 1% of primary bone tumours (3). Angiosarcoma of the bone most commonly involves the femur and tibia, followed by the pelvis, vertebral column and bones of the upper limb (4). The epithelioid subtype predominantly arises in elderly patients and has a male predominance (5). Angiosarcomas in general are suggested to have the poorest prognosis of all soft tissue sarcomas (6). To our knowledge, this is the first case report of a solitary epithelioid angiosarcoma of the scapula.

Correspondence to: J. Bürck, Department of Diagnostic Radiology, University Hospital Freiburg, Hugstetter Strasse 49, D-79095 Freiburg, Germany. Tel: +49 7612703944, Fax: +49 7612703968, e-mail: jonas.buerck@uniklinik-freiburg.de

Key Words: Angiosarcoma, angiosarcoma of the bone, epithelioid angiosarcoma.

Case Report

A 48-year-old man suffered from left-sided shoulder pain and limited movement for five months. Physical examination of the shoulder displayed normal findings externally but there was obvious restricted and painful motion. Aesthesia and circulation of the left upper limb were not disturbed. Digital radiography of the affected shoulder showed faint lytic areas at the basis of the coracoid and the glenoid without calcification and without marginal sclerosis (Figure 1A, B). At CT, a solid, 5.8 cm × 3.9 cm, osteolytic lesion with muscle-like density was seen, destroying the scapular neck, as well as parts of the glenoid cavity (Figure 1D, E). The tumour extended beyond the scapular margins and infiltrated the neighbouring subscapular- and supraspinatus muscle (Figure 1C, F). Additionally, one enlarged lymph node in the axilla was present (Figure 1C). On MRI, the tumour revealed a high, inhomogeneous signal in diffusion-weighted and T2-weighted sequences (Figure 2A, E) and a rather homogenous muscle-like low signal on T1-weighted imaging (Figure 2B). Following the administration of contrast agent, a strong enhancement was detected (Figure 2C, F). The low signal, particularly in the centre of the lesion, was suggestive of necrotic areas. Again, the surrounding skeletal muscles, especially the supraspinatus- and subscapular muscle, appeared to be deeply infiltrated (Figure 2C, F). There was no sign of infiltration of the chest wall or humerus. However, the previously mentioned axillary lymph node exhibited a marked contrast-enhancement similar to the primary lesion and therefore was assumed to be infiltrated by tumour cells. Slightly, enlarged lymph nodes were found in the mediastinum on CT of the thorax and the abdomen, but there was no metastatic spread. The subsequently conducted bone scan did not reveal any metastases either.

For the histological characterization of the tumour, a tissue specimen was obtained by open biopsy of the scapula via the fossa supraspinata. Histopathology demonstrated predominantly large epithelioid-like endothelial cells with eosinophilic cytoplasm and large vesicular nuclei. Neoplastic vessels were irregular in shape, freely intercommunicating

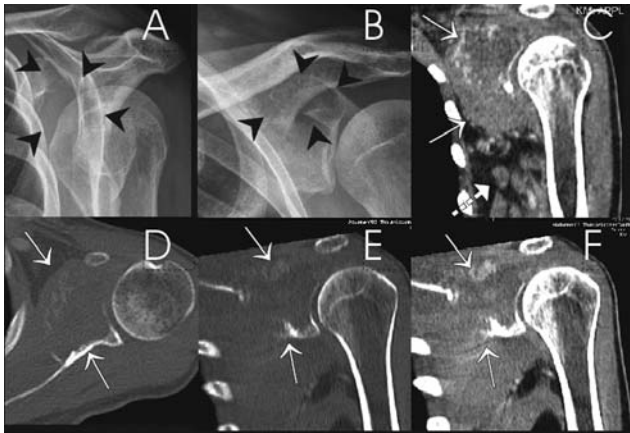


Figure 1. Image findings of the left shoulder in a 48-year-old man suffering from epithelioid angiosarcoma of the scapula. A, B: Plain x-ray radiography shows a large bone destruction of the glenoid appearing as homogenous radiolucent area with no calcification and no reactive bone sclerosis at the margins (arrowheads). C-F: CT-scan allows better assessment of the intraosseous extension (D, E: bone window, arrows) with partial destruction of the articular surface and the anterior border of the glenoid and adjacent scapula. Soft tissue window (C, F: arrows) exhibits the distinctive extraosseous soft tissue component extending to the axilla as well as local lymph node enlargement (C: broken arrow).

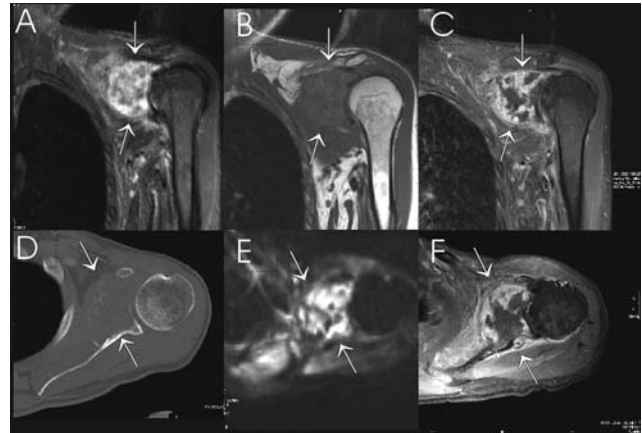


Figure 2. MR image findings of the left shoulder in a 48-year-old man suffering from epithelioid angiosarcoma of the scapula. Coronal views are displayed in the upper row, axial views are shown in the lower row. A: T2-weighted inversion recovery sequence. B: T1-weighted spin-echo sequence; C, F: fat-saturated T1 gradient echo sequence; E: diffusion-weighted sequence. A large tumour destruction of the glenoid and the adjacent scapula is seen (arrows). The lesion exhibits a high inhomogeneous signal in diffusion-weighted and T2-weighted sequences (A, E) and a rather homogeneously low signal on T1-weighted imaging (B). In contrast-enhanced images (C, F), a strong contrast-enhancement is seen, indicating the vascular origin of the tumour. However, the signal loss, particularly in the centre of the lesion indicates distinctive necrosis.

with one another in a sinusoidal fashion and infiltrating surrounding tissue. In some areas, the vessels were lined by a single attenuated layer of neoplastic endothelium (Figures 3 and 4). Extensive haemorrhage was the predominant feature of the tumour. Tumour cells expressed the usual vascular antigens including von Willebrand factor (FVIII) and CD31, following immunohistochemical staining. Staining for cytokeratin was only partial, that for S100 was negative. These findings are consistent with the diagnosis of epithelioid angiosarcoma (6, 7).

Discussion

Aetiology. Thus far the origin of an angiosarcoma remains unclear. Angiosarcomas can occur in irradiated fields (8) and in chronically lymphoedematous extremities (9).

Angiosarcomas may also arise in pre-existing benign vascular lesions and in benign and malignant nerve sheath tumours, neurofibroma, leiomyoma, spindle cell haemangioma, retinoblastoma, Klippel-Trenaunay syndrome, xeroderma pigmentosum, malignant germ cell tumour, herpes zoster lesion, and Aicardi syndrome (10). Angiosarcomas of the bone can also arise in bone infarcts (11) and fibrous dysplasia (12). One case report presents an angiosarcoma in Paget's disease (13). However, in case studies only the minority (11-27 %) of patients present these a etiological factors, and the majority of

angiosarcomas emerge sporadically (9, 14). In the case reported here, none of these a etiological factors were present.

Histological classification. Sarcomas can be categorized into low-, intermediate-, and high-grade tumours. Low-grade tumours grow slowly and there is a risk of recurrence after complete resection. High-grade tumours grow more rapidly, can recur locally and they have an increased risk of metastasis (9). Sarcomas can also be histologically divided into two subtypes: The classical, more frequent type, and the epithelioid, scarce type, which is poorly differentiated and biologically aggressive (1, 2, 15).

Prognosis and clinical classification. Tumour size is a significant prognostic factor and patients with tumours larger than 5 cm have a significantly poorer prognosis (9, 14). Negative margins after surgical resection and a distal location which facilitates resection improve prognosis (16). Multicentricity has no negative effect on the prognosis, in contrast to metastatic disease (17).

In order to discuss the appropriate treatment and to evaluate the prognosis the patients are usually classified according to the following criteria: Patients who present at initial diagnosis without metastases and who underwent a

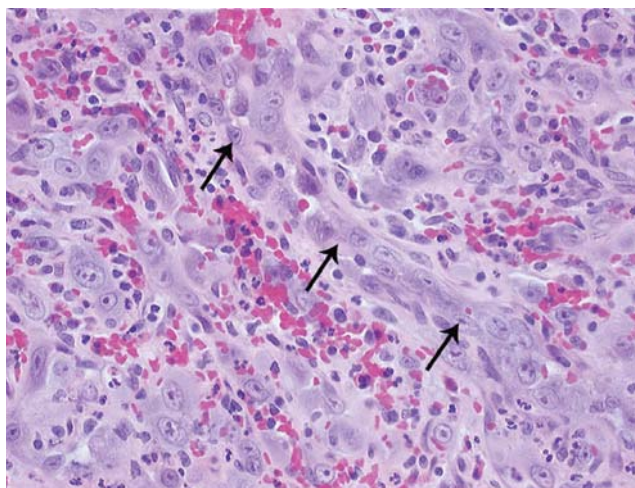


Figure 3. Haematoxylin and eosin stain, $\times 200$ magnification. Epithelioid angiosarcoma with proliferation of dilated vascular spaces with layers of endothelial cells (arrows) showing very prominent nucleoli.

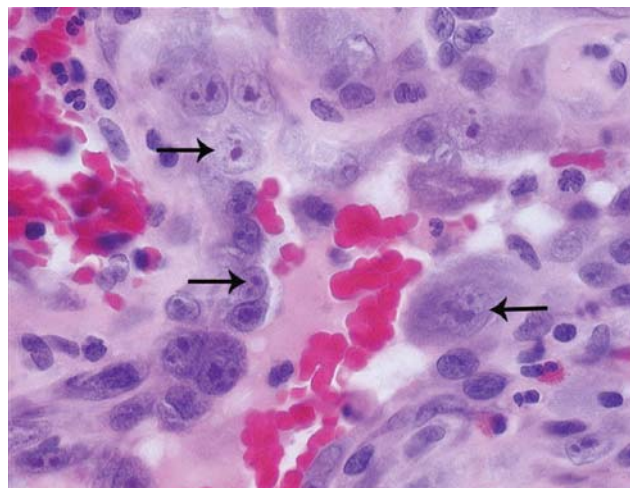


Figure 4. Haematoxylin and eosin stain, $\times 400$ magnification. Epithelioid angiosarcoma composed of solid sheets of large, oval or rounded epithelioid cells with amphophilic cytoplasm and very prominent nucleoli (arrows).

complete surgical resection are matched to the category of primary disease. Patients with advanced disease are defined as those who present with an unresectable disease at initial diagnosis, metastatic disease or both (9). The overall survival rate in patients with angiosarcoma and resected primary disease is approximately 60-70% (9, 14). A study including 82 patients showed that patients with advanced disease have a median survival of only 7.3 months (9).

Diagnostic imaging. In contrast to other bone tumours, angiosarcomas have no specific radiological characteristic features, but exhibit non-specific imaging signs of malignancy (18). Radiography shows bone destruction with lytic or lytic-sclerotic appearance and cortex arrosion (18). CT more accurately demonstrates the tumour's extent and pattern of bone destruction, particularly in complex regions such as the shoulder.

Like in other sarcomas, signal in diffusion-weighted and T2-weighted MRI sequences is high. Following contrast agent administration, typically a strong enhancement is seen, suggesting the vascular origin of the tumour. Central areas with absent enhancement are considered as necrosis and can be interpreted as a sign of rapid growth of the lesions.

Epithelioid angiosarcoma has to be differentiated from the epithelioid haemangioendothelioma, which is an intermediate grade malignant vascular neoplasm and shows comparable radiological findings, clinical presentation and localization (5). MRI appearance can be quite similar, featuring low to intermediate signal intensity on T1-weighted images, high

signal intensity on T2-weighted images and strong homogeneous Gd-DTPA enhancement. However, in contrast to angiosarcoma, destruction of the cortex and infiltration of the surrounding tissues are rare (19). Especially if epithelioid angiosarcoma presents in a multicentric pattern, it can be difficult for it to be differentiated from metastatic carcinoma. Both types of lesions occur in elderly patients and can affect multiple bones. In particular, metastases of neuroendocrine tumours can have a similar contrast-enhancement compared to vascular tumours. Due to overlapping imaging features and the large impact on the therapeutic approach, biopsy is considered mandatory to enable differentiation between epithelioid angiosarcoma, epithelioid haemangioendothelioma and metastatic carcinoma.

The final diagnosis of epithelioid angiosarcoma is usually made by immunohistology. Here, the tumour cells typically express the vascular antigens FVIII and CD31 (2, 6, 7).

Our patient presented with monostotic epithelioid angiosarcoma with no distant metastases. Due to advanced local tumour stage, an aggressive curative procedure was planned. In order to achieve an optimum presurgical condition, the patient underwent combination chemotherapy with dose escalation and subsequent peripheral blood stem cell transplantation. Subsequently a remarkable response of the tumour was achieved and wide resection was performed, involving the lateral part of the scapula, parts of the proximal humerus and the infiltrated muscles. The first follow-up examination six weeks after surgery showed no local recurrence or metastases, neither on CT nor on MRI.

References

- 1 Asmane I, Litique V, Heymann S, Marcellin L, Métivier AC, Duclos B, Bergerat JP and Kurtz JE: Adriamycin, cisplatin, ifosfamide and paclitaxel combination as front-line chemotherapy for locally advanced and metastatic angiosarcoma. Analysis of three case reports and review of the literature. *Anticancer Res* 28: 3041-3045, 2008.
- 2 Deshpande V, Rosenberg AE, O'Connell JX and Nielsen GP: Epithelioid angiosarcoma of the bone: a series of 10 cases. *Am J Surg Pathol* 27: 709-716, 2003.
- 3 Sanchez-Mejia RO, Ojemann SG, Simko J, Chaudhary UB, Levy J and Lawton MT: Sacral epithelioid angiosarcoma associated with a bleeding diathesis and spinal epidural hematoma: case report. *J Neurosurg Spine* 4: 246-250, 2006.
- 4 Saglik Y, Yildiz Y, Atalar H and Basarir K: Primary angiosarcoma of the fibula: a case report. *Acta Orthop Belg* 73: 799-803, 2007.
- 5 O'Connell JX, Nielsen GP and Rosenberg AE: Epithelioid vascular tumours of bone: a review and proposal of a classification scheme. *Adv Anat Pathol* 8: 74-82, 2001
- 6 Mittal S, Goswami C, Kanoria N and Bhattacharya A: Post-irradiation angiosarcoma of bone. *J Cancer Res Ther* 3: 96-99, 2007.
- 7 Lin CF, DeFrias D and Lin X: Epithelioid angiosarcoma: A neoplasm with potential diagnostic challenges. *Diagn Cytopathol* 38: 154-158, 2010.
- 8 Cha C, Antonescu CR, Quan ML, Maru S and Brennan MF: Long-term results with resection of radiation-induced soft tissue sarcomas. *Ann Surg* 239: 903-909, 2004.
- 9 Abraham JA, Hornicek FJ, Kaufman AM, Harmon DC, Springfield DS, Raskin KA, Mankin HJ, Kirsch DG, Rosenberg AE, Nielsen GP, Deshpande V, Suit HD, DeLaney TF and Yoon SS: Treatment and outcome of 82 patients with angiosarcoma. *Ann Surg Oncol* 14: 1953-67, 2007.
- 10 Weiss SW and Goldblum JR: Malignant vascular tumours. *In: Enzinger and Weiss and Soft Tissue Tumours*. Weiss SW and Goldblum JR (eds.). St. Louis, Mosby, pp. 917-954, 2001.
- 11 Abdelwahab IF, Klein MJ, Hermann G and Springfield D: Angiosarcomas associated with bone infarcts. *Skeletal Radiol* 27: 546-551, 1998.
- 12 Fukuroku J, Kusuzaki K, Murata H, Nakamura S, Takeshita H, Hirata M, Hashiguchi S and Hirasawa Y: Two cases of secondary angiosarcoma arising from fibrous dysplasia. *Anticancer Res* 19: 4451-4457, 1999.
- 13 Boulanger V, Chauveaux D, Kantor G, Loyer-Lecestre MJ, Rivel J, Coindre JM and Bui BN: Primary angiosarcoma of bone in Paget's disease. *Eur J Surg Oncol* 24: 611-613, 1998.
- 14 Sasaki R, Soejima T, Kishi K, Imajo Y, Hirota S, Kamikonya N, Murakami M, Kawabe T, Ejima Y, Matsumoto A and Sugimura K: Angiosarcoma treated with radiotherapy: impact of tumour type and size on outcome. *Int J Radiat Oncol Biol Phys* 52: 1032-40, 2002.
- 15 Dei Tos AP, Wagner AJ, Modena P, Comandone A and Leyvraz S: Epithelioid soft tissue tumours. *Semin Oncol* 36: 347-57, 2009.
- 16 Inoue YZ, Frassica FJ, Sim FH, Unni KK, Petersen IA and McLeod RA: Clinicopathologic features and treatment of postirradiation sarcoma of bone and soft tissue. *J Surg Oncol* 75: 42-50, 2000.
- 17 Maddox JC and Evans HL: Angiosarcoma of skin and soft tissue: A study of forty-four cases. *Cancer* 48: 1907-1921, 1981.
- 18 Wenger DE and Wold LE: Malignant vascular lesions of bone: radiologic and pathologic features. *Skeletal Radiol* 29: 619-631, 2000.
- 19 Wang CG, Jia NY, Yu HY, Liu HM and Wang J: Epithelioid hemangioendothelioma of thoracic vertebra: a case report *Eur Radiol* 19: 517-520, 2009.

Received December 2, 2009

Revised April 12, 2010

Accepted April 22, 2010