

# Ulnar Artery Thrombosis and Nerve Entrapment at Guyon's Canal: Our Diagnostic and Therapeutic Algorithm

G. MONACELLI, M. I. RIZZO, A. M. SPAGNOLI, C. MONARCA and N. SCUDERI

*Plastic Surgery of Emergency and Hand Surgery, Sapienza University of Rome, Rome, Italy*

**Abstract.** *Hypothenar hammer syndrome is a rare condition of ulnar artery aneurysm or thrombosis, which can be associated with a neuropathy of the ulnar nerve. There is no agreement regarding an optimal diagnosis and treatment for this syndrome. Most authors suggest angiography as the gold standard for diagnosis and recommend observation for the thrombotic type, and reconstructive surgery for the aneurysmal type. We report here our diagnostic and therapeutic algorithm, reviewing 9 patients with ulnar artery thrombosis and nerve entrapment at Guyon's canal; and an evaluation of the type of management including: anamnesis, diagnostic tests, and reconstructive surgery. We consider resection of the arterial thrombotic segment as the treatment of choice, due to the fact that ulnar arterial thrombosis can induce severe chronic inflammation into Guyon's canal and ulnar nerve sufferance. Therefore, we propose a planned approach, including 3 steps: clinical evaluation with Tinell and Allen's tests; magnetic resonance and ultrasound images; ulnar nerve decompression and arterial reconstruction. We believe that this practice is important for the early therapy of ulnar arterio-neuropathy in affected patients.*

Hypothenar hammer syndrome (HHS) describes a rare condition of aneurysm or thrombosis of the ulnar artery that is usually the result of repetitive trauma to the hypothenar region. According to the literature, treatment options include watchful observation for the thrombotic type and reconstructive surgery for the aneurysmal type (1). We would like to report our clinical experience with ulnar neuropathy and artery thrombosis in the presence of associated HHS and Guyon's canal syndrome and the successful surgical procedures. These

syndromes are two distinct pathologic entities that most often occur separately in the hypothenar eminence; however, they may also be associated, and, in that case, they are more difficult to diagnose (2). Guyon's canal is a fibro-osseous tunnel located along the anteromedial portion of the wrist. It is not a rigid conduit but rather a space of varying dimensions that conducts the ulnar neurovascular bundle through the wrist. The ulnar nerve lies between the pisiform bone and the ulnar veins and artery. Because of its anatomic position, the ulnar nerve is subject to entrapment and injury. The wrist (Guyon's canal) is the second most common site of ulnar nerve entrapment, also referred to as nerve compression syndrome. Possible causes of ulnar entrapment neuropathy at Guyon's canal include ganglia, lipomas, cysts, anomalies of ligaments or muscles, and fractures of the radius or pisiform bone or hook of the hamate. Ulnar entrapment may also be due to arterial compression. Segmental ulnar neuropathy has been reported as a result of ulnar nerve compression due to post-traumatic false aneurysms, thrombosis, true aneurysms, or tortuous distal ulnar artery (2-6). Lastly, Guyon's canal syndrome can also be the result of repetitive strain injury (7).

HHS is caused by blunt repetitive injury to the ulnar artery and superficial palmar arch from impact against the hamulus. Typically, the resultant trauma to the hypothenar eminence is chronic. Because of the anatomic configuration of the Guyon canal, the ulnar artery is particularly vulnerable to mechanical injury due to its entrapment between a hammer (external force) and an avil (the hamulus). Intimal hyperplasia is almost invariably present in HHS, along with duplication and fragmentation of the internal elastic lamina. Arterial wall damage may lead to aneurism formation with or without vessel thrombosis and to microemboli formation and compression of the sensory branch of the ulnar nerve (2, 8-10).

The aim of this report is to present nine cases of ulnar entrapment neuropathy due to ulnar arteriopathy at Guyon's canal, and to suggest an algorithm of diagnosis and treatment for the early identification and recovery from ulnar nerve compression.

*Correspondence to:* M.I. Rizzo, Via Fidenza 27, 00182 Rome, Italy. Via Masi 8 – 87060 Mirto (CS), Italy. Tel: +39 3391593646, Fax: +39 098342250, e-mail: mariaidarizzo@libero.it

**Key Words:** Ulnar artery thrombosis, ulnar nerve entrapment, Guyon's canal.

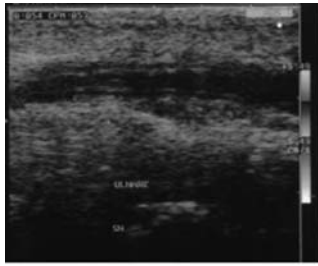


Figure 1. Ultrasound image of left ulnar artery showing arterial thrombosis and thickness with a triple ring aspect of the wall.

## Cases Report

Nine patients, 44 years old on average, Caucasian, male, five left-handed and four right-handed, manual workers used to repetitive injury, presented with complaints of pain in the little and ring fingers, burning sensation along the hypothenar eminence, weakness, numbness and discoloration of the hand. Patients had been experiencing this pain for about one or two weeks. There were no symptoms pertaining to previous trauma to the hand or upper extremity, no positional changes, and no change with altered environmental temperature. On examination, the blood pressures in both arms were similar, but there was relative ischemia of the affected digits. Respiratory, neurological and abdominal examinations were unremarkable. Little and ring fingers had cyanosis, and the capillary refill time was 4 seconds, compared to 2 seconds in the left thumb. Allen's test showed complete radial dominance. There was a slight diminution of the hypothenar eminence muscle mass, with weakness of the fourth and fifth digit abduction. Sensation to touch and pinprick was diminished in the ulnar distribution of the hand. Positive Tinel's sign at the Guyon's canal showed an ulnar nerve sufferance. It was necessary to identify the causes of ulnar nerve compression, and exclude hematological or immunological disorders. Therefore, patients underwent laboratory investigations (which were negative for vasculitis and connectivitis), Doppler-ultrasound (US) and angio-magnetic resonance (MR) (to study the ulnar artery), and MR imaging (to study the ulnar nerve and to exclude the presence of a mass lesion and bone or muscle anomalies). Grayscale and Doppler-US showed a thrombosed ulnar artery at the level of the hook of the hamate. The artery appeared thrombosed and thicker with a triple ring aspect of its wall (Figure 1). Angio-MR showed interruption of the palmar branch of the ulnar artery with ulnar occlusion at the level of Guyon's canal (Figure 2). MR showed diffused edema in the hypothenar eminence, no mass, thrombosis of the ulnar artery, inflammation of the ulnar nerve and surrounding tissue and fatty atrophy of the ulnar muscles (Figure 3). Ulnar neuropathy and arteropathy at the level of

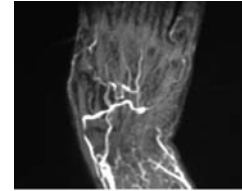


Figure 2. Angiogram of the left hand showing the ulnar occlusion at the level of Guyon's canal and interruption of the palmar arch.

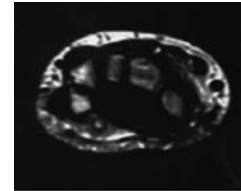


Figure 3. Magnetic resonance image showing ulnar artery thrombosis, inflammation of the ulnar nerve and surrounding tissue at the level of Guyon's canal, edema and ulnar muscle atrophy.

Guyon's canal we assessed in the absence of soft-tissue tumors; therefore nerve decompression and artery revascularization was performed. Under brachial plexus anesthesia and tourniquet, patients underwent vertical incision at the level of Guyon's canal and its release. Exploration of the ulnar nerve in the released canal showed a thrombosed tortuous and augmented ulnar artery, which was thrombosis affected, compressing the ulnar nerve. The ulnar artery was dissected from the underlying entrapped nerve. The diseased segment of the ulnar artery was resected and the contralateral basilic vein was used to create an interposition graft. The carpal ligament was incised. Patients were prescribed a low molecular weight heparin and discharged. The postoperative course was unremarkable. The patients reported immediate relief from symptoms. At 1-month follow-up, they were symptom free and digital pressures were normal. Moreover, patients were examined clinically with the Allen's test and instrumentally with CW Doppler sonography to evaluate the ulnar flow. At long-term follow-up, patients underwent electromyography that showed normal values of ulnar nerve conduction and of muscle excitability.

## Discussion

Analyzing our experience and according to the literature, although rare, vascular compromise can be a cause of hand pain (11). Physical examination usually enables differentiation between vascular causes and isolated ulnar

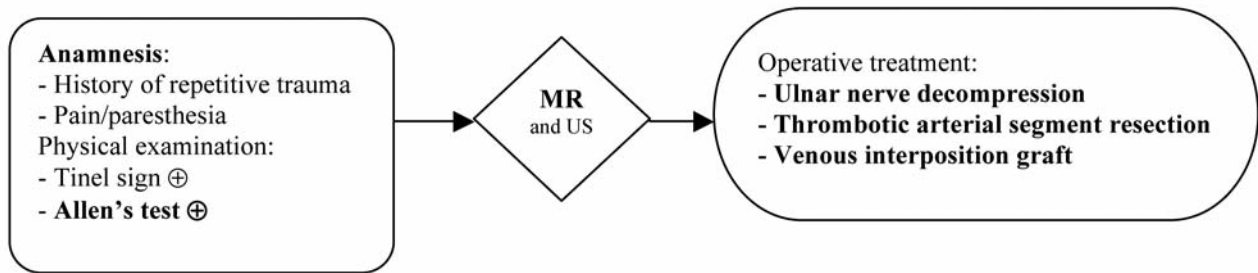


Figure 4. *Diagnosis and treatment (main steps in bold).*

nerve compression; the diagnosis can be confirmed with US, MR, multidetector computed tomography (CT), conventional angiography, CT angiography, or MR angiography (12-15). The selection of the imaging modality to be used for further work-up for peripheral neuropathies depends on the anatomic location of the abnormality, the clinician's preference, local availability, and the individual experience of the radiologist with each modality. However, angiography is the gold standard of diagnosis for well-evaluated blood flow (11) and it is required in order to determine the most appropriate treatment (16). However, several authors, such as Blum *et al.* and Andreisek *et al.*, suggest that MR imaging may provide useful information with regard to the exact anatomic location of the lesion or may aid in narrowing the differential diagnosis, and in patients with peripheral neuropathy, MR imaging may establish the origins of the condition and provide information crucial for management or surgical planning (2, 3).

Special care had to be taken for a correct diagnosis, performing angio-MR that showed clearly ulnar artery thrombosis and incomplete palmar arches (Figure 2). Nevertheless, we believe that in the presence of pain and digital ischemia along the hypothenar eminence and the little and ring fingers, Allen's test showing arterial insufficiency (with eventually US imaging demonstration) and MR imaging can be sufficient. These techniques confirmed the presence of HHS and Guyon's canal syndrome. Therefore, and in agreement with previous authors, we suggest that MR imaging is the modality of choice for evaluating the ulnar nerve and causal factor of compression. T1-weighted sequences are best suited for identifying the ulnar nerve within Guyon's canal: the bifurcation of the ulnar nerve and the course of both branches are well depicted, all the loose bodies with adherence to synovium and synovial cysts are detected, as well as osteoarthritis, synovitis, bone and muscle anomalies, accessory muscle and fibrous bands can be seen at MR imaging (2, 3, 17). On T1-weighted images (Figure 3), effectively, the ulnar nerve appears as a round structure with altered size and signal intensity, edema and fatty atrophy of the ulnar intrinsic muscles indicative of ulnar

muscle denervation, and the presence of mass lesion is excluded. Furthermore, MR imaging is an excellent method for demonstrating nerve compression by detecting abnormalities in the hand. The MR imaging and the clinical features allow a diagnosis to be made. US confirms lesions of the ulnar artery that may include wall thickening, stenosis, aneurysm, occlusion, and corkscrew configuration. In addition, although angiography is very efficient for the diagnosis of HHS, we understand that is not the modality of choice because physical examination and MR are sufficient. In fact, Allen's test is specific for arterial insufficiency and MR evaluates well the condition of the ulnar nerve and surrounding structures, demonstrating pathologic compression of the ulnar nerve within Guyon's canal with edema and atrophy of the ulnar intrinsic muscles of the left hand. Therefore, the diagnosis can be made easily and early for the surgeon to develop a therapeutic plan.

According to the literature, treatment of Guyon's canal syndrome begins with rest and splinting of the wrist. If compression is present, surgical decompression may be performed (2). Treatment of HHS consists of rest from the offending activity and therapy with vasodilators. Asymptomatic ulnar artery occlusions do not need surgical intervention (2, 11, 18). Therapeutic approach of this syndrome is strictly correlated to its symptoms starting from a simple oral anti-platelet aggregation therapy to a surgical excision of the affected vessel and its bypass reconstruction (11, 19). Klitscher *et al.* assert that the thrombotic form is mainly treated conservatively (20). But we believe that only surgical decompression of the ulnar nerve and resection of the ulnar involved arterial segment and anastomosis with autologous vein graft are effective. Moreover, we suggest that surgical decompression must be considered to avoid irreversible nerve alterations such as axonocachexia (21). Similarly, the thrombotic form must be resected to avoid occlusions of digital branches presumed to be secondary to thromboembolism (22).

In conclusion, we report the diagnosis and treatment of HHS in which the ulnar arterial thrombosis induced severe chronic inflammation in Guyon's canal and ulnar nerve

compression (Guyon's canal syndrome); and we discuss the management of the two syndromes associated. In the presence of upper limb digital ischemia and pain, history should be carefully obtained and investigations should be conducted before irreversible consequences take place: amputation of ulcerated necrotic finger tips may be required in advanced cases. Correct management suggested is Allen's test and MR with US images for diagnosis, and operative treatment with nerve decompression and vein interposition graft after resection of the arterial thrombotic segment (Figure 4). In our experience, within this framework, patients recover swiftly and effectively.

## References

- Nitecki S, Anekstein Y, Karram T, Peer A and Bass A: Hypothenar hammer syndrome: apropos of six cases and review of the literature. *Vascular* 16: 279-282, 2008.
- Blum AG, Zabel JP, Kohlmann R, Batch T, Barbara K, Zhu X, Dautel G and Dap F: Pathologic conditions of the hypothenar eminence: evaluation with multidetector CT and MR imaging. *Radiographics* 26: 1021-1044, 2006.
- Andreisek G, Crook DW, Burg D, Marincek B and Weishaupt D: Peripheral neuropathies of the median, radial, and ulnar nerves: MR imaging features. *Radiographics* 26: 1267-1287, 2006.
- Conn J Jr, Bergan JJ and Bell JR: Hypothenar hammer syndrome: post-traumatic digital ischemia. *Surgery* 68: 1122-1128, 1979.
- Jose RM, Bragg T and Srivastava S: Ulnar nerve compression in Guyon's canal in presence of a tortuous ulnar artery. *J Hand Surg [Br]* 31: 200-202, 2006.
- Sierakowski A, Zweifel CJ and Payne S: Compression of the ulnar nerve in Guyon's canal caused by a large hypothenar cyst. *Eplasty* 10: e4, 2009.
- Van Tulder M, Malmivaara A and Koes B: Repetitive strain injury. *Lancet* 369: 1815-1822, 2007.
- Ferris BL, Taylor LM, Oyama K, McLafferty RB, Edwards JM, Moneta GL and Porter JM: Hypothenar hammer syndrome: proposed etiology. *J Vasc Surg* 31: 104-113, 2000.
- Stone JR: Intimal hyperplasia in the distal ulnar artery: influence of gender and implications for the hypothenar hammer syndrome. *Cardiovasc Pathol* 13: 20-25, 2004.
- Walgenbach KJ, Krishnamurthy A, Walgenbach-Brünagel G and Lee WP: An anomalous muscle predisposing to the development of hypothenar hammer syndrome. *Plast Reconstr Surg* 24: 197e-199e, 2009.
- Karimi KM, Perlmutter AE and Freeman BG: Overuse-related vascular injury of the hand-hypothenar hammer syndrome: a case report. *W V Med* 101: 250-252, 2005.
- Velling TE, Brennan FJ, Hall LD, Puckett ML, Reeves TR and Powell CC: Sonographic diagnosis of ulnar artery aneurysm in hypothenar hammer syndrome: report of 2 cases. *J Ultrasound Med* 20: 921-924, 2001.
- Winterer JT, Ghanem N, Roth M, Schaefer O, Lehnhardt S, Thürl C, Horch RE and Laubenberger J: Diagnosis of the hypothenar hammer syndrome by high-resolution contrast-enhanced MR angiography. *Eur Radiol* 12: 2457-2462, 2002.
- Blum A, Water F, Payafar A, Witte Y, Ludig T and Roland J: Radiography of the upper limb revisited: the shoulder and the wrist. *J Radiol* 82: 355-369, 2001.
- Drapè JL, Cotten A and Chevrot A: Magnetic resonance imaging of nerve entrapment syndromes of the upper limb. *Chir Main* 23: S15-26, 2004.
- Anderson SE, De Monaco D, Buechler U, Triller J, Gerich U, Dalinka M, Stauffer E, Nagy L, Niedecker A, Campbell R, Araoz PA and Steinbach LS: Imaging features of the pseudoaneurysms of the hand in children and adults. *AJR Am J Roentgenol* 180: 659-664, 2003.
- Tsavellas G, Huang A and Ranaboldo CJ: Soft-tissue case 42 hypothenar hammer syndrome. *Can J Surg* 44: 409-467, 2001.
- Harris EJ, Taylor LM, Edwards JM, Mills JL and Porter JM: Surgical treatment of distal ulnar artery aneurysm. *Am J Surg* 159: 527-530, 1990.
- De Monaco D, Fritsche E, Rigoni G, Schlunke S and Von Wartburg U: Hypothenar hammer syndrome. Retrospective study of nine cases. *J Hand Surg [Br]* 24: 731-734, 1999.
- Klitscher D, Muller LP, Rudig L, Simiantonaki N, Arnold G and Rommens PM: Progressive hypothenar hammer syndrome indication for operative treatment. *Chirurg* 76: 1175-1180, 2005.
- Nemoto K: Experimental study on the vulnerability of the peripheral nerve. *Nippon Seikeigeka Gakkai Zasshi* 57: 1773-1786, 1983.
- Birrer M and Baumgartner I: Images in clinical medicine. Work-related vascular injuries of the hand – hypothenar hammer syndrome. *N Engl J Med* 347: 339, 2002.

Received March 3, 2010

Revised May 27, 2010

Accepted June 2, 2010