

# Chemotherapy in Canine Acute Megakaryoblastic Leukemia: A Case Report and Review of the Literature

MICHAEL WILLMANN<sup>1</sup>, LEONHARD MÜLLAUER<sup>2</sup>, ILSE SCHWENDENWEIN<sup>3</sup>,  
BIRGITT WOLFESBERGER<sup>1</sup>, MIRIAM KLEITER<sup>1</sup>, MAXIMILIAN PAGITZ<sup>1</sup>,  
EMIR HADZIJUSUFOVIC<sup>1,4</sup>, SARINA SHIBLY<sup>1</sup>, MARTIN REIFINGER<sup>5</sup>,  
JOHANN G. THALHAMMER<sup>1</sup> and PETER VALENT<sup>4</sup>

<sup>1</sup>Department for Companion Animals and Horses, Clinic for Internal Medicine and Infectious Diseases,

<sup>3</sup>Department of Pathobiology, Central Laboratory, and

<sup>5</sup>Institute of Pathology and Forensic Veterinary Medicine, University of Veterinary Medicine Vienna, A-1210 Vienna;

<sup>2</sup>Institute of Clinical Pathology <sup>4</sup>Department of Internal Medicine I,

Division of Hematology and Hemostaseology, Medical University of Vienna, A-1090 Vienna, Austria

**Abstract.** Acute myeloid leukemia (AML) in dogs is a rare disease with poor prognosis. In most subjects, palliative treatment or euthanasia is performed. A 3.5-year-old male castrated labrador with AML-M7, which was treated with induction polychemotherapy (8 cycles) using vincristine (0.5 mg/m<sup>2</sup>/cycle), daunorubicin (20 mg/m<sup>2</sup>/cycle), cytosine arabinoside (ARA-C, 100 mg/m<sup>2</sup>/cycle) and prednisolone (1 mg/kg/day) is reported. Treatment was well tolerated and complete remission was achieved. Postinduction chemotherapy consisted of ARA-C, daunorubicin and prednisolone. After 3, 5 and 18 months, the subject relapsed. Each relapse was treated with ARA-C (up to 1,000 mg/m<sup>2</sup>) and etoposide or daunorubicin. Again, no severe side-effects occurred and the disease was controlled, with 37 chemotherapy-cycles (ARA-C, 3 x 1,000 mg/m<sup>2</sup>/cycle), for 24 months. Based on a literature-search, this is the first report documenting a long-term response of canine AML, probably resulting from the high-dose ARA-C. Clinical trials using high-dose ARA-C are now required to confirm antileukemic efficacy in canine leukemias.

Acute megakaryoblastic leukemia (AML-M7) in dogs is a rare subtype of acute myeloid leukemia (AML), first described by Rudolph and Huebner (1). Reports of the disease to date have been sporadic and focused on diagnostic methods and

descriptions of clinical findings (6-16). While diagnosis of AML, in particular AML-M7, remains difficult in dogs, the advance of immunophenotyping to characterize leukemic cells has improved veterinary diagnostics (2-11). Similar to the human system, the diagnosis of AML in dogs is based on myeloid blasts in the marrow and/or blood with a threshold of  $\geq 30\%$  and their classification is based on morphology, cytochemistry and phenotype (2-5). Unfortunately, the prognosis for dogs with AML-M7 is grave (1-16). In particular, treatment with conventional chemotherapy, if performed at all, is ineffective in these subjects, with a life expectancy of less than 2 weeks (1, 6, 10, 12, 16). Thus, most AML-M7 cases are euthanized immediately after diagnosis or receive supportive or palliative therapy (7-9, 11, 13-15). In canine subjects with non-AML-M7 leukemias, the prognosis and survival are slightly better (17). However, no recommended standard chemotherapy regimen has so far been defined for AML in dogs (4).

In humans, it is generally accepted that remission status after induction therapy must be confirmed by bone marrow aspiration (18). Confirmed remission is followed by repetitive consolidation cycles with high-dose cytosine arabinoside (ARA-C) to maintain remission in these patients regardless of age (19, 20). Furthermore, long-term survival of AML patients receiving remission induction polychemotherapy exceeds that of patients considered for palliative treatment or low-dose ARA-C (19). By contrast, chemotherapy for canine AML frequently consists of low-dose (but never high-dose) ARA-C in combination with other cytoreductive drugs and has remained disappointing to date (10, 17, 21-23). We were therefore interested to learn whether induction or reinduction therapy with higher doses of ARA-C followed by repetitive consolidation cycles might serve as a more efficient (and also safe) treatment option in canine AML patients.

*Correspondence to:* Michael Willmann, DVM, Department for Companion Animals and Horses, Clinic for Internal Medicine and Infectious Diseases, University of Veterinary Medicine Vienna, A-1210 Vienna, Veterinarplatz 1, Austria. Tel: +43 1 250776870, Fax: +43 1 250775799, e-mail: michael.willmann@vu-wien.ac.at

**Key Words:** Acute megakaryoblastic leukemia, AML-M7, chemotherapy, cytosine arabinoside.

Table I. Complete blood count and blood chemistry at presentation.

		Reference interval
Erythrocytes	1.88×10 <sup>6</sup> /μL	5.5-8.0
Hematocrit	11.6%	37-55
Hb	4.1 g/dL	12.0-18.0
MCV	61.7 fl	60.0-77.0
MCHC	21.8 pg	19.0-24.5
WBC	7,730 /μL	6,000-15,000
Band	0 /μL	0-500
Seg	4,840 /μL	3,300-11,250
Lymphocytes	1,580 /μL	780-4,500
Monocytes	680 /μL	0-500
Eosinophils	340 /μL	0-800
Basophils	230 /μL	0-150
Platelets	1,480×10 <sup>3</sup> /μL	150-500
Unclassified cells	280 /μL	0-150
AP	243 U/L	<130
ALT	102 U/L	<80
Total bilirubin	0.05 mg/dL	<0.8
Albumin	3.59 g/dL	2.58-4.73
Total protein	6.31 g/dL	6.0-7.5
BUN	25.0 mg/dL	20-40
Serum creatinine	0.6 mg/dL	0.4-1.2
Glucose	118 mg/dL	55-90
Sodium	147 mmol/L	140-152
Potassium	3.6 mmol/L	3.6-5.6
Chloride	108 mmol/L	95-113
Calcium	2.51 mmol/L	2.40-3.00
Phosphorus	1.94 mmol/L	0.90-1.60

Hb, Hemoglobin; MCV, mean corpuscular volume; MCHC, mean corpuscular hemoglobin concentration; WBC, white blood cell count; Band, band neutrophils; Seg., segmented neutrophils; AP, alkaline phosphatase; ALT, alanine aminotransferase; BUN, blood urea nitrogen.

## Case Report

A 3.5-year-old male castrated labrador was presented with a short history of lethargy, anorexia and hemorrhagic diarrhea. Blood examination in a private clinic had revealed severe anemia (hematocrit (HCT) 18.8%, reference interval (RI), 37-55%), thrombocytopenia (platelets 5×10<sup>3</sup>/μL, RI, 150-500×10<sup>3</sup>/μL), leukocytosis (leukocytes 31,740/μL, RI, 6,000-15,000/μL) and a low percentage of blast cells in the blood smear (<10% of all nucleated cells (ANCs)). The subject received an unmatched whole blood transfusion (450 ml) and prednisolone (2 mg/kg body weight (BW), per os (*p.o.*) q12h) and was referred to our department. Physical examination showed pale mucous membranes, elevated breathing and heart rates as well as abdominal distension. Thoracic radiographs were inconspicuous. Abdominal ultrasonography showed an enlarged spleen, thickened intestinal wall and enlarged visceral lymph nodes. Blood counts showed severe normocytic anemia (HCT 12%),

Table II. Doses given during treatment cycles over the course of therapy.

	Cycle <sup>a</sup>	ARA-C (mg/m <sup>2</sup> )	DNR (mg/m <sup>2</sup> )	VP-16 (mg/m <sup>2</sup> )	VCR (mg/m <sup>2</sup> )	Pred (mg/kg/ day)
Induction 1	1, 2		20.0*		0.5	2.0
	3, 4	100.0*	20.0*			2.0
	5	100.0*	25.0*			2.0
	6	100.0*	27.5*			2.0
	7, 8	100.0***	25.0*			2.0
Consolidation 1	1-3	100.0*				2.0
Induction 2	1-4	100.0***		40.0*		2.0
	1	300.0***				2.0
	2	400.0***				2.0
	3	600.0***				2.0
	4-6	600.0***		20.0***		2.0
Induction 3 (Escalation)	7-9	800.0***		20.0***		2.0
	10-12	1000.0***		20.0***		2.0
Consolidation 2	1-5	1000.0***				2.0
	6-12	1000.0*				2.0
	13	1000.0***				2.0
Induction 4	1-5	1000.0***	20.0*			2.0
Induction 5	1	1000.0*	20.0**			2.0
	2	1000.0*		40.0*		2.0
	3	1000.0*	20.0**			2.0

<sup>a</sup>Cycle duration: one week; ARA-C, cytosine arabinoside; DNR, daunorubicin; VP-16, etoposide; VCR, vincristine; Pred, prednisolone; \*once weekly (day 1); \*\*twice weekly (day 1 and 3); \*\*\*three times weekly (day 1, 3 and 5).

thrombocytosis (1,480×10<sup>3</sup>/μL), a white blood count within RI (WRI) (7,700/μL) and few blast cells (<10% of ANC's). All the serum chemistry parameters were WRI (Table I). Evaluation of the blood smear revealed blast cells that were variable in size, had round nuclei and a deeply basophilic cytoplasm with vacuoles and cytoplasmic projections (Figure 1A). The bone marrow aspirate revealed hypocellularity with low numbers of mature neutrophils. More than 50% of ANC's were large immature cells with a deeply basophilic cytoplasm and frequent nucleoli. Several of these cells had bi- or polylobed nuclei and many exhibited cytoplasmic projections, resembling the morphology of immature megakaryocytic cells (Figure 1B). Although not definitive, the diagnosis of AML-M7 was considered most likely due to the morphology of the blast cells in the peripheral blood and bone marrow.

Induction chemotherapy (Figure 2) consisting of vincristine (0.5 mg/m<sup>2</sup> body surface (BS), intravenously (*i.v.*)) and daunorubicin (20 mg/m<sup>2</sup> BS, *i.v.* over 20 minutes)

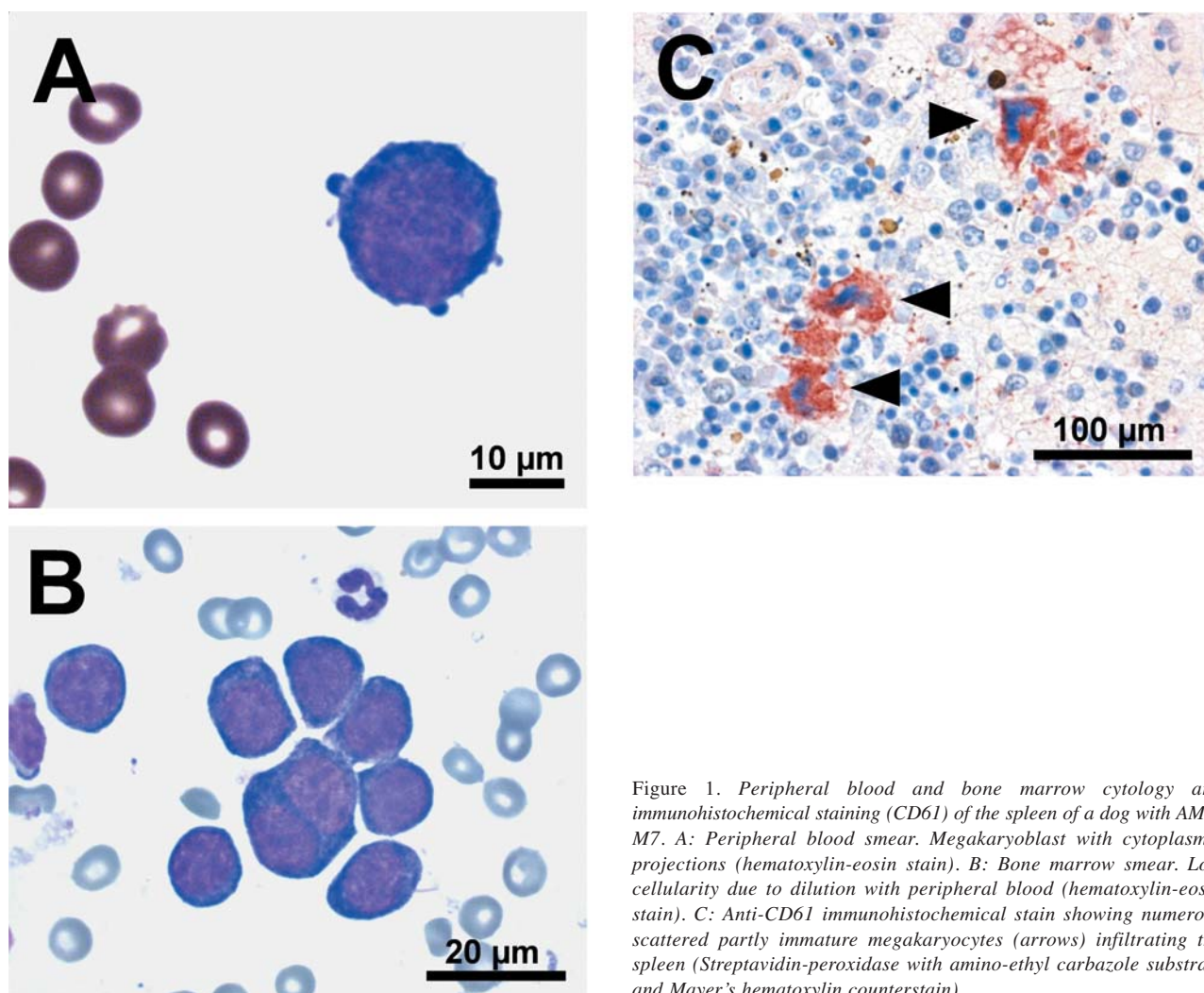


Figure 1. *Peripheral blood and bone marrow cytology and immunohistochemical staining (CD61) of the spleen of a dog with AML-M7. A: Peripheral blood smear. Megakaryoblast with cytoplasmic projections (hematoxylin-eosin stain). B: Bone marrow smear. Low cellularity due to dilution with peripheral blood (hematoxylin-eosin stain). C: Anti-CD61 immunohistochemical stain showing numerous scattered partly immature megakaryocytes (arrows) infiltrating the spleen (Streptavidin-peroxidase with amino-ethyl carbazole substrate and Mayer's hematoxylin counterstain).*

was administered once weekly (2 cycles), concurrently with prednisolone (1 mg/kg, *p.o.* q12h). In addition, the subject received prophylactic antimicrobial therapy. Adverse events (AE) were assessed according to the Veterinary Co-operative Oncology Group – Common Terminology Criteria for Adverse Events (VCOG-CTCAE) following chemotherapy or biological antineoplastic therapy in dogs and cats (24). Monitoring and scaling of quality of life (QoL) were performed up to 3 times a week based on the owner's report, complete physical examination and blood sampling, including complete blood counts (CBC) and biochemical profile (Figure 3 A-E).

Although the clinical condition of the dog improved after 2 cycles, the blood counts remained abnormal (Figure 3). A second blood transfusion (packed cell volume (PCV), dog erythrocyte antigen (DEA) 1.1 negative) was performed and chemotherapy was intensified using a combination of daunorubicin and cytosine arabinoside (ARA-C, *i.v.* over 30

minutes) once a week for four cycles (Table II). The therapy resulted in stable leukocyte counts. Two further chemotherapy cycles consisting of ARA-C and daunorubicin were applied (with 1-week treatment-free intervals between cycles). After two cycles, blood counts improved and a complete remission (CR) was obtained as determined by bone marrow investigations (Figures 2 and 3). Consolidation chemotherapy consisted of three cycles of ARA-C once a week.

Three months after the initial therapy, severe thrombocytopenia and anemia occurred and blast cells were detected in blood smear examination (first relapse). A second induction-chemotherapy phase consisting of four cycles of ARA-C combined with etoposide (*i.v.* over one hour) was initiated (1-week treatment-free intervals between cycles), resulting in an immediate improvement of erythrocyte and thrombocyte counts (Figure 3A and B). Two months later (5 months after the initial therapy), a decrease in platelet counts was noted and again blast cells were identified in peripheral

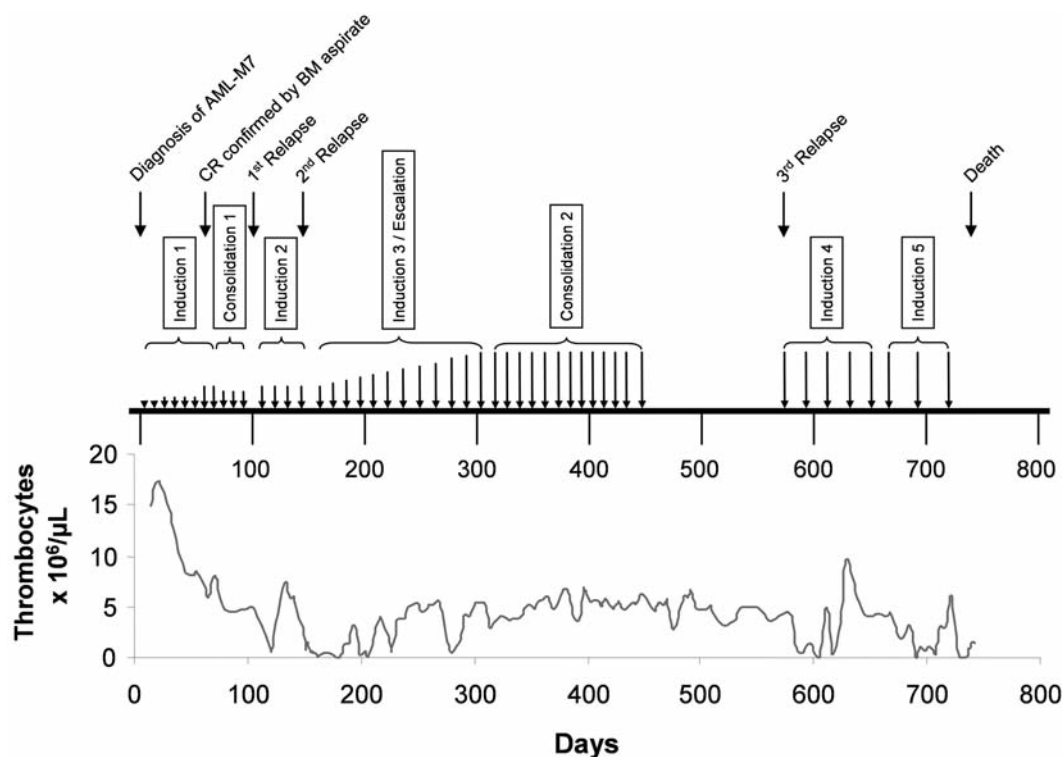


Figure 2. Polychemotherapy treatment sequence and thrombocyte profile over the course of therapy. Induction 1: 8 cycles, vincristine (VCR), daunorubicin (DNR) and ARA-C (▼, length of vertical bar above the arrow symbolizes dose of ARA-C); consolidation 1: 3 cycles of ARA-C; induction 2: 4 cycles, ARA-C in combination with etoposide (VP-16); induction 3/escalation: 12 cycles with escalating doses of ARA-C combined with VP-16; consolidation 2: 13 cycles with high-dose ARA-C; induction 4: 5 cycles with high-dose ARA-C combined with DNR; induction 5: 3 cycles with high-dose ARA-C combined with DNR or VP-16. All relapses coincided with severe thrombocytopenias. CR: Complete remission, BM: bone marrow.

blood smears (second relapse). Reinduction chemotherapy (induction 3) consisted of 3 weekly cycles using escalating doses of ARA-C (Table II), resulting again in an improvement of blood counts without severe leukopenia (lowest neutrophil count: 1,820/ $\mu$ L; RI, 3,300-11,250/ $\mu$ L) and without adverse side-effects. Despite a moderate decrease in platelet counts, 9 further chemotherapy cycles were administered, including escalating doses of ARA-C combined with etoposide. The subject did not suffer from severe side-effects and showed a stable clinical course and further improvement of erythrocyte counts. Therefore, chemotherapy (consolidation 2) was continued using ARA-C for 12 weeks. After 2 weeks without treatment, one final consolidation cycle with ARA-C was performed followed by three months without chemotherapy.

After a total of 19 months following initial therapy the dog exhibited sudden acquired weakness. Severe thrombocytopenia ( $38 \times 10^3$ / $\mu$ L), anemia (HCT 7.8%) and few blast cells in the blood smears were indicative of a further relapse. A fourth reinduction consisted of 5 cycles of ARA-C combined with daunorubicin, followed by 2 weeks without therapy between cycles. Supportive care consisted of four whole blood

transfusions during the first cycle. Immediate improvement of the platelet count and QoL of the subject indicated an initial treatment response, but severe thrombocytopenia ( $9 \times 10^3$ / $\mu$ L) and circulating blasts were detectable after the end of induction therapy, indicating a further relapse (fourth relapse). Reinduction (induction 5) was performed with 3 cycles of ARA-C combined with daunorubicin alternating with etoposide with intermittent therapy-free intervals of 2 weeks. After 24 months, however, the clinical situation worsened and progressive severe cytopenia (anemia, thrombocytopenia), as well as circulating blast cells, occurred. The dog developed anorexia, weakness and petechial bleeding, as well as generalized lymphadenopathy. Supportive therapy consisted of additional blood transfusions and antibacterial drugs. Finally, the subject was euthanized 24 months after the initial therapy.

All in all, 48 chemotherapy cycles consisting of a total of 108 mono- or polychemotherapies were administered (Figure 2). The cumulative dose of antimetabolite agents used in the course of treatment amounted to 56,026 mg ARA-C (maximum single dose: 1,000 mg/ $m^2$  BS, *i.v.*), 222 mg daunorubicin (maximum single dose: 27.5 mg/ $m^2$  BS, *i.v.*), 640 mg etoposide (maximum single dose: 40 mg/ $m^2$  BS, *i.v.*) and 1 mg vincristine.



Table III. Characteristics, diagnostic tests, therapy and survival time of dogs with AML-M7: cases from the literature and reported herein.

Case No.	Breed	Age (years)	Gender	Phenotyping (positive)	Therapy	Survival (days)	Reference
#1	German Shepherd	5.5	f	PAS	Chem, Pred	5	Rudolph and Huebner (1)
#2	Afghan	2.0	m	ANAE, PAS, SBB	ST	10	Holscher <i>et al.</i> (12)
#3	Beagle	1.5	m	ACHe, ANAE	14 BT	330	Cain <i>et al.</i> <sup>b</sup> (27 and 28)
#4	German Shepherd	3.0	m	ANAE, PAS	0	1	Shull <i>et al.</i> (13)
#5	English Bulldog	1.0	s	ANAE, PAS	ST, BT	33	Bolon <i>et al.</i> (14)
#6	Lhasa Apso	2.5	m	ANAE, ANBE, NASDC, vWF	0	1	Messick <i>et al.</i> (11)
#7	German Shepherd	7.0	m	ND	0	1	Canfield <i>et al.</i> (15)
#8	Mixed breed	3.0	f	ANAE, PAS, NASDC, vWF, CD61	ST	14	Colbatzky and Hesmanns (6)
#9	German Shepherd	3.0	m	ANAE, PAS, NASDC, vWF, CD61	ST	14	Colbatzky and Hesmanns (6)
#10	Louisiana Catahoula Leopard	7.0	s	vWF, CD61	0	3	Pucheu-Haston <i>et al.</i> (7)
#11	Maltese	8.0	f	ANBE	BT, ST, Pred	15	Miyamoto <i>et al.</i> (16)
#12	Dachshound	7.0	m	vWF, FXIII, CD61	0	1	Ledieu <i>et al.</i> (8)
#13	Shih Tzu	10.0	f	vWF, CD61	ST	1	Park <i>et al.</i> (9)
#14	German Shepherd	5.0	f	vWF, CD34, CD41	ST, Pred, Chem	14	Suter <i>et al.</i> (10)
#15	Labrador	3.5	c	CD61	108 Chem, 11 BT, ST	732	Current

f: Female; m, male; s, spayed female; c, castrated male; <sup>a</sup>Phenotyping: enzyme cytochemistry, immunocytochemistry or immunohistochemistry; AChE, acetylcholinesterase; ANAE, alpha naphthyl acetate esterase; ANBE, alpha naphthyl butyrate esterase; NASDC,  $\alpha$ -naphthol AS-D chloroacetate esterase; PAS, periodic acid-Schiff; SBB, Sudan black B; vWF, von Willebrand factor; FXIII, factor XIII; CD61, platelet glycoprotein IIIa; CD34, immature hematopoietic cell glycoprotein; CD41, platelet glycoprotein IIb; ND, not done; ST, supportive therapy; BT, blood transfusion; Pred, prednisolone; Chem, chemotherapy; <sup>b</sup>dog with radiation-induced megakaryoblastic leukemia.

Despite long-term chemotherapy with multiple cycles including high-dose ARA-C, side-effects were relatively mild and tolerable and the QoL was good. Mild gastrointestinal side-effects associated with chemotherapy included occasional lack of appetite and vomiting once on the day of treatment. Concomitant treatment consisted of metoclopramide (0.4 mg/kg BW, *p.o.* q12h) as needed and continuous administration of famotidine (0.5 mg/kg BW, *p.o.*, q12h). Due to the anaphylactic potential of etoposide, the patient received diphenhydramine (4 mg/kg BW, intramuscular (*i.m.*), once) and prednisolone (1 mg/kg BW, *i.v.*, once) prior to intravenous etoposide infusions and one hour infusion time was assigned. During etoposide infusions, mild anaphylactic reactions were noticed, including mild skin flashing and pruritus. On day 683 the subject collapsed during etoposide infusion, most probably as a result of an anaphylactic reaction. Immediate recovery within an hour was achieved by shock infusion. During treatment, bacterial infections, including urinary infections (n=2), arthritis (n=1) and dermatitis (n=2) occurred. In each case, the infection responded well and rapidly to antibiotic therapy. No life-threatening infection developed. The assessment of CTCAE revealed grade 1 to 2 events, mostly self-limiting except for the vascular collapse during etoposide infusion (grade 3). Elevated alanine-aminotransferase (ALT) with a maximum of 776 U/L (RI, <80 U/L) was consistent with grade 3 according to the CTCAE scale (Figure 3D). QoL monitoring confirmed good to excellent performance status of the dog for most of the time during therapy.

Necropsy immediately after euthanasia revealed marked splenomegaly, mild hepatomegaly and enlarged visceral lymph nodes. Tissue samples (bone marrow, spleen, liver and lymph nodes) were fixed in 7% neutral buffered formalin, embedded in paraffin and cut at 3  $\mu$ m. Sections were routinely stained with hematoxylin-eosin (HE) and Wright-Giemsa. To characterize the blast cells and to determine the lineage of the disease, histochemical staining and immunophenotyping were used. In particular, stainings for myeloperoxidase (MPO) and  $\alpha$ -naphthol AS-D chloroacetate esterase (NASDC) were performed and immunohistochemistry was applied using the following antibodies: CD3 (CD3-12; AbD Serotec, Oxford, UK), CD34 (1H6; Santa Cruz Biotechnology Inc., Santa Cruz, CA, USA), CD61 (Y2/51; Dako, Carpinteria, CA, USA) and CD79a (HM57; Dako), using previously described methods (3, 6, 9, 10). Unfortunately, another established antibody for CD41 to confirm megakaryocytic lineage is no longer available for immunohistochemical staining. Multiple organs including bone marrow, liver, spleen and visceral lymph nodes were infiltrated with neoplastic blast cells and pleiomorphic megakaryocytes. The leukemic cells exhibited a negative reaction for NASDC and MPO (data not shown). These blast cells were also negative for lymphocytic lineage markers (CD3 and CD 79a), negative for the hematopoietic progenitor marker CD34 and negative for glycoprotein GPIIIa (CD61). As mentioned above, diffusely scattered partly immature megakaryocytic cells that stained positively for CD61 were detectable in the bone marrow, enlarged spleen, liver and lymph nodes (Figure 1C). In

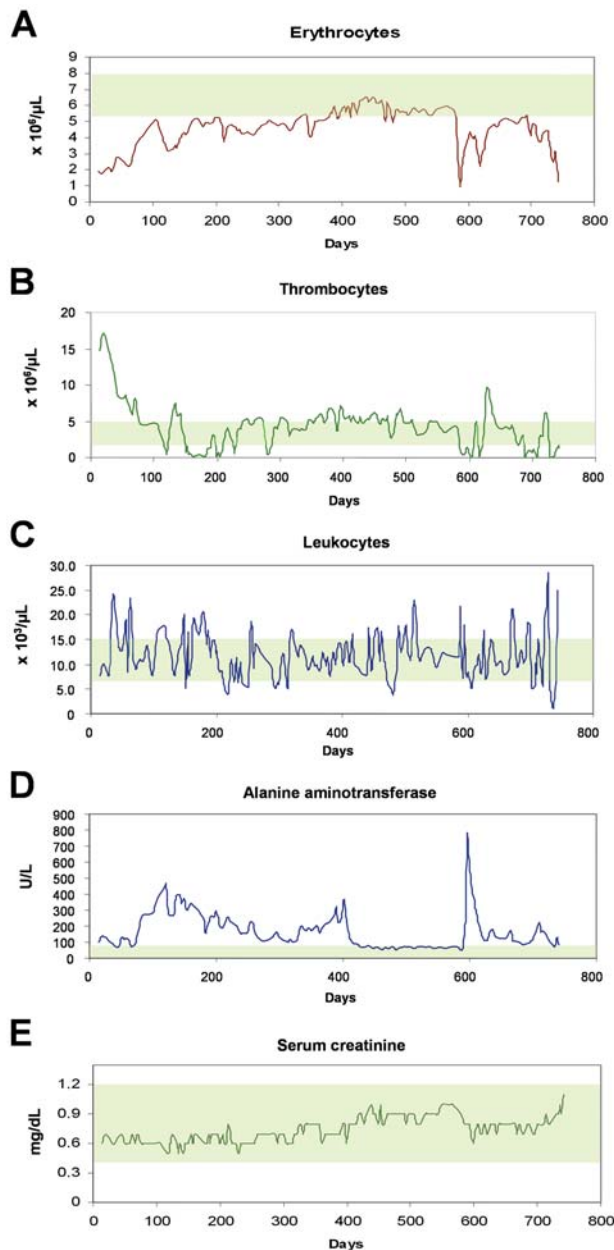


Figure 3. Blood counts and biochemical parameters during the course of treatment. Complete blood counts and biochemical profiles were performed up to three times weekly (total 94 blood samples). Underlying green background depicts reference interval.

addition, multiple clusters of mature megakaryocytes that stained clearly positively for CD61 were observed in the enlarged spleen, liver and the lymph nodes.

Although the blast cells stained negatively for CD61, the high number of CD61-positive immature and mature megakaryocytes detected in the peripheral blood, bone marrow, spleen, liver and lymph nodes, resulted in the final diagnosis of AML, most probably AML-M7.

Table IV. Clinical and laboratory characteristics of reported and present AML-M7 cases at presentation.

	Total (n=15)	
	Median (range)	Total (%)
Age (years)	3.5 (1-10)	
Gender (m/f)		8/7
Anorexia		14 (88%)
Lethargy		9 (56%)
Weight loss		7 (44%)
Bleeding		4 (25%)
Fever		3 (19%)
Shifting limb lameness		2 (12%)
Vomiting/diarrhea		2 (12%)
Polyuria/polydipsia		1 (6%)
Splenomegaly		13 (81%)
Lymphadenopathy		10 (63%)
Hepatomegaly		8 (50%)
Circulating blasts		11 (69%)
Bone marrow blast cells (%)	58 (30-95)	
Hematocrit (%)	13 (9-31)	
Hemoglobin (g/dL)	5 (2.7-8.0)	
WBC (/μL)	5,700 (1,500-54,000)	
Plts (×10 <sup>3</sup> /μL)	15 (2-2,880)	

m, Male and male castrated; f, female and female spayed; WBC, white blood cells; Plts, platelets.

## Discussion

In the present study, the successful treatment of canine AML-M7 using polychemotherapy similar to human regimes based on high-dose ARA-C in combination with daunorubicin and etoposide resulted in long-term survival without long-lasting bone marrow aplasia, only mild AE and good to excellent QoL. The diagnosis of AML-M7 was based on the presence of blast cells with typical cytoplasmic extensions and the diffusely scattered and partly immature megakaryocytes that stained positive for CD61, found in the bone marrow, spleen, liver and lymph nodes. The histopathological demonstration of immature megakaryocytes in the spleen in dogs with AML-M7 has also been reported by others (6-9, 12, 15, 16, 28). Similarly, thrombocytosis has been described in other canine (Table IV) and human patients with AML-M7 in the past (6, 9, 12, 16, 25, 26).

The observation that the blast cells in the present subject did not stain positively for CD61 was an unexpected finding, since in most AML-M7 cases the blast cells are CD61 positive. The failure to detect CD61 in the blast cells may be explained by the low expression of this antigen on blast cells as opposed to CD61 expression on megakaryocytes. Alternatively, the blast cells may have expressed an altered form of CD61 (so that the antibody could not bind). Finally, it might be that these blast cells were not committed to give rise to megakaryocytes.

Out of all the canine AML-M7 cases documented in the literature (including the present case), six were treated with supportive care alone, four with cytoreductive and supportive therapy including two with prednisolone monotherapy and five were euthanized immediately after diagnosis (Table III). The median survival time was 10 days (range 1 to 732 days), with two long-term survivors, the one reported in this article (732 days) and a second dog with AML induced experimentally by radiation, with 330 days survival (27, 28). The present AML-M7 subject achieved CR as confirmed by bone marrow aspiration using a combination of ARA-C, daunorubicin, vincristin and prednisolone for induction and 3 cycles of ARA-C for consolidation. The long-term survival beyond the first and second relapses achieved in this case probably resulted from treatment with repetitive cycles of chemotherapy and the use of high-dose ARA-C.

Chemotherapy for canine AML is associated with an increased risk of severe infections, bleeding and transfusion-dependence (21, 22). Though these side-effects are transient and can usually be controlled by supportive measures in responding individuals, prolonged cytopenia may be a life-threatening side-effect. In the present case, cytopenias developed during chemotherapy. The subject also required blood transfusions and antibiotics. However, no severe hematological AE were detected during the chemotherapy, although high doses of ARA-C were applied. Interestingly, the lowest neutrophil count was 1,820/ $\mu$ L. In addition, PVC levels constantly improved during further consolidation cycles without further blood transfusions.

Severe AE of chemotherapy, resulting in decreased QoL and financial consequences (*e.g.* hospitalization) are a major concern of clients (29). Therefore, the subject was monitored according to the VCOG-CTCAE and QoL was recorded two to three times a week during high-dose chemotherapy. As assessed by clinical and hematological examinations, severe AE did not develop at any time during therapy, despite high-dose ARA-C administration. Moreover, the chemotherapy was well tolerated with good to excellent QoL in the course of therapy.

In summary, in canine AML-M7 polychemotherapy based on high-dose ARA-C provides encouraging antileukemic effects with relatively low (acceptable) toxicity. As in humans, the combination of ARA-C, daunorubicin and etoposide can be used to induce remission in AML-M7 and multiple cycles of chemotherapy using high (escalating) doses of ARA-C are sufficient to keep the disease under long-term control. Importantly, this therapy has only few side-effects and thus is efficient in maintaining the QoL. In addition, to the authors' best knowledge, this is the first report of acute megakaryoblastic leukemia in a dog with a survival time of 24 months using polychemotherapy. Further investigations are now required to show whether beneficial effects with this therapy regime can also be seen in other individuals with AML.

## References

- 1 Rudolph R and Huebner C: Megakaryozyten Leukose beim Hund (Megakaryoblastic leukosis in a dog). *Kleintier Prax* 17: 9-13, 1972.
- 2 McManus PM: Classification of myeloid neoplasms: a comparative review. *Vet Clin Pathol* 34: 189-212, 2005.
- 3 Vernau W and Moore PF: An immunophenotypic study of canine leukemias and preliminary assessment of clonality by polymerase chain reaction. *Vet Immunol Immunopathol* 69: 145-164, 1999.
- 4 Moore AS and Ogilvie GK: Acute leukemias. *In: Managing the Canine Cancer Patient: Bone Marrow Neoplasia*. Henry RA (ed.). PA, MediMedia, Veterinary Learning System, Yardley, pp. 364-366, 2006.
- 5 Tasca S, Carli E, Caldin M, Menegazzo L, Furlanello T and Gallego LS: Hematologic abnormalities and flow cytometric immunophenotyping results in dogs with hematopoietic neoplasia: 210 cases (2002-2006). *Vet Clin Pathol* 38: 2-12, 2009.
- 6 Colbatzy F and Hermanns W: Acute megakaryoblastic leukemia in one cat and two dogs. *Vet Pathol* 30: 186-194, 1993.
- 7 Pucheu-Haston CM, Camus A, Taboada J, Gaunt SD, Snider TG III and Lopez MK: Megakaryoblastic leukemia in a dog. *J Am Vet Med Assoc* 207: 194-196, 1995.
- 8 Ledieu D, Palazzi X, Marchal T and Fournel-Fleury S: Acute megakaryoblastic leukemia with erythrophagocytosis and thrombosis in a dog. *Vet Clin Pathol* 34: 52-56, 2005.
- 9 Park HM, Doster AR, Tashbaeva RE, Lee YM, Lyoo YS, Lee SJ, Kim HJ and Sur JH: Clinical, histopathological and immunohistochemical findings in a case of megakaryoblastic leukemia in a dog. *J Vet Diagn Invest* 18: 287-291, 2006.
- 10 Suter SE, Vernau W, Fry MM and London CA: CD34<sup>+</sup>, CD41<sup>+</sup> acute megakaryoblastic leukemia in a dog. *Vet Clin Pathol* 36: 288-292, 2007.
- 11 Messick J, Carothers M and Wellman M: Identification and characterization of megakaryoblasts in acute megakaryoblastic leukemia in a dog. *Vet Pathol* 27: 212-214, 1990.
- 12 Holscher MA, Collins RD, Glick AD and Griffith BO: Megakaryocytic leukemia in a dog. *Vet Pathol* 15: 562-565, 1978.
- 13 Shull RM, DeNovo RC and McCracken MD: Megakaryoblastic leukemia in a dog. *Vet Pathol* 23: 533-536, 1986.
- 14 Bolon B, Buergelt CD, Harvey JW, Meyer DJ and Kaplan-Stein D: Megakaryoblastic leukemia in a dog. *Vet Clin Pathol* 18: 669-721, 1989.
- 15 Canfield PJ, Church DB and Russ IG: Myeloproliferative disorder involving the megakaryocytic line. *J Small Anim Pract* 34: 296-301, 1993.
- 16 Miyamoto T, Hachimura H and Amimoto A: A case of megakaryoblastic leukemia in a dog. *J Vet Med Sci* 58: 177-179, 1996.
- 17 Jain NC, Madewell BR, Weller RE and Geissler MC: Clinical-pathological findings and cytochemical characterization of myelomonocytic leukaemia in 5 dogs. *J Comp Pathol* 91: 17-31, 1981.
- 18 Cheson BD, Cassileth PA, Head DR, Schiffer CA, Bennett JM, Bloomfield CD, Brunning R, Gale RP, Grever MR and Keating MJ: Report of the National Cancer Institute-sponsored workshop on definitions of diagnosis and response in acute myeloid leukemia. *J Clin Oncol* 8: 813-819, 1990.
- 19 Buechner T, Hiddemann W, Schoch C, Haferlach T, Sauerland MC and Heinecke A: Acute myeloid leukaemia (AML): treatment of the older patient. *Best Pract Res Clin Haematol* 14: 139-151, 2001.

- 20 Sperr WR, Piribauer M, Wimazal F, Fonatsch C, Thalhammer-Scherrer R, Schwarzingner I, Geissler K, Knöbl P, Jäger U, Lechner K and Valent P: A novel effective and safe consolidation for patients over 60 years with acute myeloid leukemia: intermediate dose cytarabine ( $2 \times 1 \text{ g/m}^2$  on days 1, 3, and 5). *Clin Cancer Res* 10: 3965-3971, 2004.
- 21 Couto CG: Clinicopathologic aspects of acute leukemias in the dog. *J Am Vet Med Assoc* 186: 681-685, 1985.
- 22 Grindem CB and Buoen LC: Cytogenetic analysis of leukaemic cells in the dog: A report of 10 cases and a review of the literature. *J Comp Pathol* 96: 623-635, 1986.
- 23 Grindem CB, Stevens JB and Perman V: Morphologic classification and clinical and pathological characteristics of spontaneous leukemia in 17 dogs. *J Am Anim Hosp Assoc* 21: 219-226, 1985.
- 24 Vail D: Veterinary Co-operative Oncology Group – Common Terminology Criteria for Adverse Events (VCOG-CTCAE) following chemotherapy or biological antineoplastic therapy in dogs and cats v 1.0. *Vet Comp Oncol* 2: 194-213, 2004.
- 25 Oki Y, Kantarjian HM, Zhou X, Cortes J, Faderl S, Verstovsek S, O'Brien S, Koller C, Beran M, Bekele BN, Pierce S, Thomas D, Ravandi F, Wierda WG, Giles F, Ferrajoli A, Jabbour E, Keating MJ, Bueso-Ramos CE, Estey E and Garcia-Manero G: Adult acute megakaryocytic leukemia: an analysis of 37 patients treated at M.D. Anderson Cancer Center. *Blood* 107: 880-884, 2006.
- 26 Tallman MS, Neuberg D, Bennett JM, Francois CJ, Paietta E, Wiernik PH, Dewald G, Cassileth PA, Oken MM and Rowe JM: Acute megakaryocytic leukemia: the Eastern Cooperative Oncology Group experience. *Blood* 96: 2405-2411, 2000.
- 27 Cain GR, Kawakami TG and Jain NC: Radiation-induced megakaryoblastic leukemia in a dog. *Vet Pathol* 22: 641-643, 1985.
- 28 Cain GR, Feldman BF, Kawakami TG and Jain NC: Platelet dysplasia associated with megakaryoblastic leukemia in a dog. *J Am Vet Med Assoc* 188: 529-530, 1986.
- 29 Mellanby RJ, Herrtage ME and Dobson JM: Owners' assessments of their dog's quality of life during palliative chemotherapy for lymphoma. *J Small Anim Pract* 44: 100-103, 2003.

*Received July 5, 2009*

*Revised October 8, 2009*

*Accepted October 14, 2009*