

# The Prevalence of Colonic Amyloidosis in Baboons. A 22-year Survey at a Large Primate Facility

CARLOS A. RUBIO, EDWARD J. DICK Jr. and GENE B. HUBBARD

*Southwest National Primate Research Center at the Southwest Foundation  
for Biomedical Research, San Antonio, TX, 78245-0549, U.S.A.*

**Abstract.** *Background: Colonic amyloidosis has been previously reported in animals, however its prevalence rate has not yet been explored. The aim of the present work was to assess the prevalence of colonic amyloidosis at the Southwest National Primate Research Center since 1986. Materials and Methods: Colonic amyloidosis was sought in autopsy material from baboons collected under the diagnosis of systemic amyloidosis. Results: Between 1986 and 2007, a mean of 3,315 baboons per year (range 2,578-3,931) were housed at the Southwest National Primate Research Center. After examination, colonic amyloidosis was detected in 6 (6.8%) of the 88 baboons with systemic amyloidosis, yielding a prevalence rate of 0.27 cases per year since 1986. Colonic amyloid deposits were found in the interstitial aspect of the lamina propria, often replacing normal mucosal crypts of Lieberkuhn. Conclusion: It was observed that only 6.8% of animals with systemic amyloidosis examined between 1986 and 2007 developed colonic amyloidosis. The apparent natural resistance to colonic amyloidosis in baboons presenting systemic amyloidosis deserves to be further investigated.*

Amyloidosis is a disease caused by the abnormal tissue accretion primarily of insoluble plasma proteins conveyed by fibrillogenesis. The disease can be organ specific, however when systemic, it affects several organs such as the heart, liver, spleen, kidneys, lymph nodes, adrenals, thyroid and the gastrointestinal (GI) tract. Amyloidosis is found not only in humans but also in animals. Systemic amyloidosis secondary to chronic inflammation is the most common form in animals (1). Naumenko and Krylova (1) studied 133 cases of amyloidosis in macaques (*Macaca mulatta*, *M. nemestrina* and *M. fascicularis*). The liver, the spleen and the pancreas

were the most commonly affected organs. Hubbard *et al.* (2, 3) found systemic amyloidosis in the liver, pancreas, spleen, kidney, intestines and mesenteric lymph nodes in 12 chimpanzees (2), and mainly in the pancreas and less frequently in the spleen, kidney, adrenal, stomach and intestine in 40 baboons (3).

Amyloidosis affecting the intestinal tract was reported by Slattum *et al.* (4) who detected GI amyloidosis in 75% of 248 pig-tail macaques at necropsy and by Doepel *et al.* (5) in 3 out of 5 Rhesus monkeys. Colonic involvement was reported by Blanchard *et al.* (6) in 67% of 57 Rhesus monkeys with amyloidosis, by DiBartola *et al.* (7) in all of 15 Abyssinian cats with familial amyloidosis and by Gonzalez (8) in all of 30 hamsters having visceral leishmaniasis infection. On the other hand, the colon was not affected in several other studies in animals with systemic amyloidosis (1, 8-12).

The autopsy material of all baboons housed at the Southwest National Primate Research Center since 1986 having an initial diagnosis of systemic amyloidosis was recently reviewed with the aim of assessing the prevalence of animals exhibiting colonic amyloidosis and the results are presented in this paper.

## Materials and Methods

Since 1986, autopsy material of all baboons diagnosed with systemic amyloidosis has been collected at the Southwest National Primate Research Center. The baboons were members of colonies at this facility, the housing conditions of which have been reported elsewhere (3). Briefly, the animals were housed in metal and concrete indoor-outdoor cages and were fed commercial monkey diets occasionally supplemented with a variety of fruit and vegetables. Water was available *ad libitum*. Baboons were euthanized with a commercial barbiturate euthanasia agent or died naturally, then necropsied. Tissue samples were fixed in 10% neutral buffered formalin, processed conventionally, embedded in paraffin, cut at 5  $\mu$ m, stained with hematoxylin and eosin (H&E), and evaluated by light microscopy. All procedures were performed in accordance with the Institutional Animal Care and Use Committee. All H&E-stained histological sections from baboons diagnosed with systemic amyloidosis were reviewed. Sections stained with Congo Red were analyzed under polarized light.

*Correspondence to:* C.A. Rubio, MD, Ph.D, Gastrointestinal and Liver Pathology Research Laboratory, Department of Pathology, Karolinska Institute and University Hospital, 17176, Stockholm, Sweden. Fax: +46 8 51774524, e-mail: Carlos.Rubio@ki.se

*Key Words:* Amyloidosis, colon, baboon.

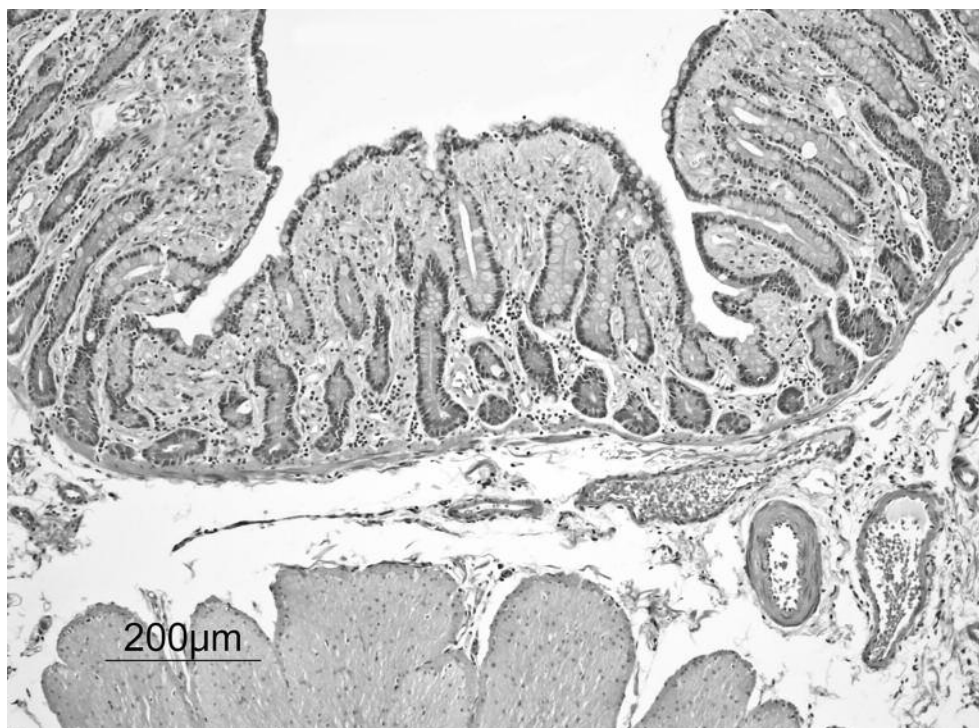


Figure 1. Colonic mucosa replaced by interstitial deposits of amyloid (H&E,  $\times 4$ , baboon).

## Results

**Frequency of colonic amyloidosis.** Histological sections from a total of 88 baboons with an initial diagnosis of systemic amyloidosis were retrieved from the files and reviewed. Colonic amyloidosis was found in 6 (6.8%) of the 88 baboons.

**Prevalence of colonic amyloidosis.** Between January 1986 and January 2007, a mean of 3,315 baboons per year (range 2,578-3,931 baboons per year) were housed at the Southwest National Primate Research Center. Consequently, the prevalence (defined as the number of cases of an illness or condition that exists at a particular time in a defined population) of colonic amyloidosis occurring since 1986 at this facility was 0.27 baboons per year.

**Histologic features.** In H&E-stained sections, amyloid appears as a pink, hyalinized material. Amyloid deposits were found in the interstitial aspect of the *lamina propria*, expanding this structure and replacing the normal crypts of Lieberkuhn (Figures 1 and 2). Amyloid material was also seen in the submucosal stroma. Sections with colonic amyloidosis stained with Congo Red demonstrated polarized light the characteristic apple-green bi-refringence in areas having amyloid deposits in all 6 animals.

## Discussion

In a comprehensive study of the pathology of amyloidosis in fishes, amphibians, reptiles, birds, rodents (gerbils, guinea pigs, nutria, dogs, stone martens and minks), cats, cattle, marsupials, and other mammals, Zschesche and Jakob (13) found amyloid deposits with increasing frequency in the liver, lymph nodes, spleen and the small intestine (13).

Large intestine amyloidosis was found in primates by Blanchard (6), in Abyssinian cats by DiBartola (7) and in hamsters by Gonzalez (8). On the other hand, Naumenko and Krylova (1), Rusell *et al.* (9), Hukkanen *et al.* (10) and Chapman *et al.* (11) found no colonic amyloidosis in primates with systemic amyloidosis. Similarly, Penttilä *et al.* (12) found no colonic amyloidosis in mice with systemic amyloidosis. The causes for these differences remain unclear.

Previous studies at this facility (3) showed amyloidosis in the liver, pancreas, spleen, kidney, intestines and mesenteric lymph nodes in 12 chimpanzees with systemic amyloidosis (2) and mainly in the pancreas and less frequently in the spleen, kidney, adrenal, intestine and stomach in 40 baboons with systemic amyloidosis (3).

In a recent review of H&E stained sections of the 88 baboons filed here since 1986 under the diagnosis of systemic amyloidosis, we found gastric amyloidosis in 9 (10.2%) of the 88 baboons (14). The present survey demonstrated colonic amyloidosis in 6 (6.8%) of these 88 baboons.

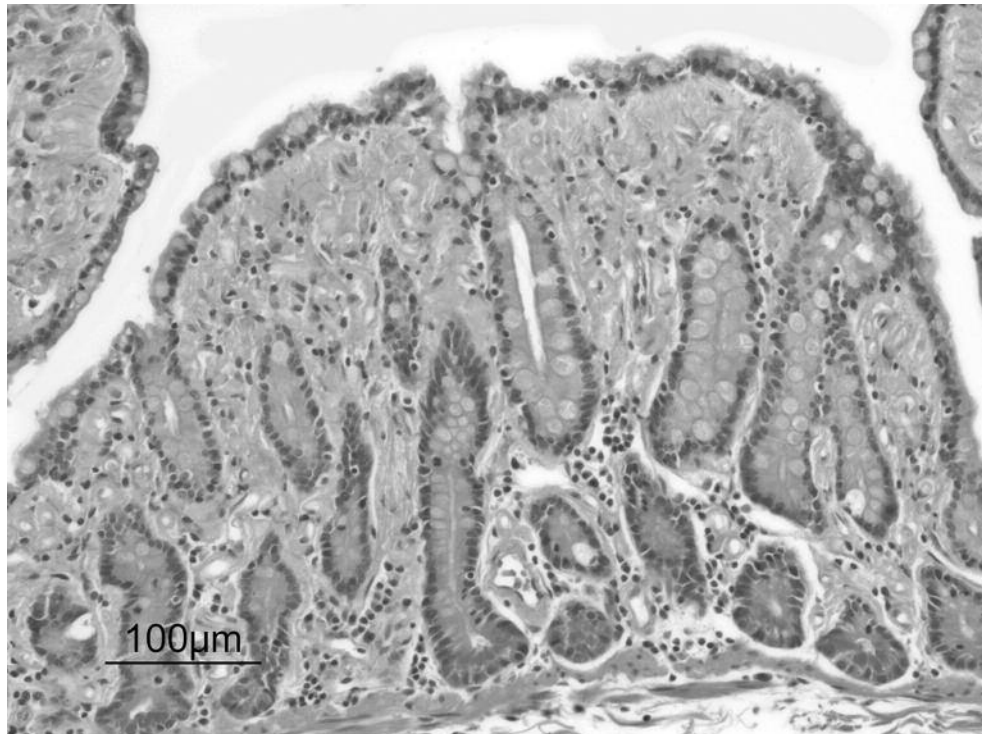

Figure 2. Detail to show the replacement of the colonic mucosa by interstitial deposits (H&E,  $\times 10$ , baboon).

In conclusion, it is apparent that baboons with systemic amyloidosis at this facility are affected, not only in the liver, pancreas, spleen, kidney, intestines and mesenteric lymph node, but also in other organs of the GI tract such as the stomach (3, 14) and the colon (present report). However, the latter two organs are less susceptible to amyloid substance accretion than the former ones. The apparent natural resistance of the colon of baboons to being affected by systemic amyloidosis, a phenomenon also observed in other animals (1, 10-12), should be investigated further.

## References

- 1 Naumenko ES and Krylova RI: Amyloidosis in macaques in Adler Primatological Center. *Bull Exp Biol Med* 136: 80-83, 2003.
- 2 Hubbard GB, Lee DR, Steele KE, Lee S, Binhazim AA and Brasky KM: Spontaneous amyloidosis in twelve chimpanzees, *Pan troglodytes*. *J Med Primatol* 30: 260-267, 2001.
- 3 Hubbard GB, Steele KE, Davis KJ 3rd and Leland MM: Spontaneous pancreatic islet amyloidosis in 40 baboons. *J Med Primatol* 31: 84-90, 2002.
- 4 Slattum MM, Tsai CC, DiGiacomo RF and Giddens WE Jr: Amyloidosis in pigtailed macaques (*Macaca nemestrina*): pathologic aspects. *Lab Anim Sci* 39: 567-570, 1989.
- 5 Doepel FM, Ringler DH and Petkus AR: Secondary amyloidosis in Rhesus monkeys with chronic indwelling venous catheters. *Lab Anim Sci* 34: 494-496, 1984.
- 6 Blanchard JL, Baskin GB and Watson EA: Generalized amyloidosis in Rhesus monkeys. *Vet Pathol* 23: 425-430, 1986.
- 7 DiBartola SP, Tarr MJ and Benson MD: Tissue distribution of amyloid deposits in Abyssinian cats with familial amyloidosis. *J Comp Pathol* 96: 387-398, 1986.
- 8 Gonzalez H, Insa F, Novoa C and Pizarro M: Intestinal amyloidosis in hamsters with visceral leishmaniasis. *Br J Exp Pathol* 67: 353-360, 1986.
- 9 Russell RG, Rosenkranz SL, Lee LA, Howard H, DiGiacomo RF, Bronsdon MA, Blakley GA, Tsai CC and Morton WR: Epidemiology and etiology of diarrhea in colony-born *Macaca nemestrina*. *Lab Anim Sci* 37: 309-316, 1987.
- 10 Hukkanen RR, Liggitt HD, Anderson DM and Kelley ST: Detection of systemic amyloidosis in the pig-tailed macaque (*Macaca nemestrina*). *Comp Med* 56: 119-127, 2006.
- 11 Chapman WL Jr and Crowell WA: Amyloidosis in Rhesus monkeys with rheumatoid arthritis and enterocolitis. *J Am Vet Med Assoc* 171: 855-858, 1977.
- 12 Penttilä G, Abonen A, Klinge F and Alhave E: Studies of catecholamines in amyloidosis. *Ann Clin Res* 7: 447-451, 1975.
- 13 Zschiesche W and Jakob W: Pathology of animal amyloidosis. *Pharmac Ther* 41: 49-83, 1989.
- 14 Rubio CA, Dick E Jr and Hubbard G: The frequency of gastric amyloidosis in baboons. A 22-year survey at a large primate facility. *In Vivo* 22: 663-666, 2008.

Received June 30, 2008

Revised August 25, 2008

Accepted September 4, 2008