

Effects of Aucubin on the Healing of Oral Wounds

KYUNG MI SHIM¹, SEOK HWA CHOI², MOON-JIN JEONG³ and SEONG SOO KANG¹

¹College of Veterinary Medicine, Chonnam National University, Gwangju;

²College of Veterinary Medicine, Chungbuk National University, Chungbuk;

³Department of Oral Histology, College of Dentistry, Chosun University, Gwangju, Republic of Korea

Abstract. Aucubin is an iridoid glycoside with a variety of pharmacological effects, such as antimicrobial and anti-inflammatory, whilst also promoting dermal wound healing. This study examined the effects of 0.1% aucubin on oral wound healing. ICR male mice were divided into two groups: an untreated control group (n=18) and an aucubin-treated group (n=18). Saline or 0.1% aucubin solution was injected and artificial full thickness wounds were made on either side of the buccal mucosa. Specimens were taken on days 1, 3 and 5, and light microscopic examination and quantitative histological analysis were performed to determine the extent of re-epithelization, inflammatory cell infiltration and matrix formation. Re-epithelization and matrix formation of the aucubin-treated group occurred earlier than that of the control group. In addition, the number of inflammatory cells of the aucubin-treated group was fewer than that of the control group. In conclusion, aucubin may be useful for oral wound healing and can be applied as a topical agent to oral wounds.

Oral wounds can arise from trauma, periodontal disease, tooth extraction and oral surgery. Oral wounds cannot be protected by bandages and can become severe as a result of self-mutilation during normal daily activities. Therefore, splints or drugs are needed to protect the wound area and to accelerate wound healing.

Antibiotics, corticosteroids, non-steroidal anti-inflammatory drugs (NSAIDs), disinfectants such as chlorhexidine or chlorine dioxide and vitamins have been used to help in oral wound healing (1). However, these drugs have many adverse effects such as gastrointestinal impairment, bacterial resistance, stimulation of the oral mucosa, discoloration and dysgeusia (2). Many

Correspondence to: Seong Soo Kang, DVM, Ph.D., College of Veterinary Medicine, Chonnam National University, 300 Yongbong-dong, Puk-gu, Gwangju 500-757, Republic of Korea. Tel: +82 62 5302877, Fax: +82 62 5302809, e-mail: vetkang@chonnam.ac.kr

Key Words: Aucubin, oral mucosa, wound healing, mouse.

researchers have examined the effects on wound healing of medicinal plants, which have more healing effects and fewer adverse effects than other chemicals (3).

Aucubin is an iridoid glycoside isolated from *Aucuba japonica* or *Plantago asiatica* (4). It has a variety of pharmacological effects such as hepatoprotective (5), choleric (6), hemodynamic (7), antispasmodic (8), antimicrobial (9), antinociceptive (10), anti-inflammatory (11), inhibition of RNA and protein biosyntheses in sarcoma 180 cells (12), and promotion of dermal wound healing (13).

This study examined the effects of a 0.1% aucubin solution on oral wound healing in mice.

Materials and Methods

Animals. Thirty-six 7-week-old male ICR mice (Damul Experimental Animal Center, Daejeon, South Korea) were used in this study. The animals were kept under normal laboratory conditions and given a standard pelleted diet and water *ad libitum*. The mice were allowed 1 week of quarantine and acclimatization before being divided into two groups: an untreated control group (n=18) and an aucubin-treated group (n=18). These experiments were carried out in accordance with the Guidelines for Animal Experiments of the Chonnam National University.

Intra-oral wounding and treatment. The mice were anesthetized with ether before wounding. Aucubin extracted and purified from leaves of *Aucuba japonica* by Chang's method (4) was diluted with saline to a concentration of 1 mg/ml (0.1% aucubin solution). Fifty µl of a 0.1% aucubin solution or saline were injected on either side of the buccal mucosa of mice of the aucubin-treated group and untreated control group. Artificial full thickness wounds were made on the site using a 1.5 mm biopsy punch with a sterile technique. The mice were sacrificed at 1, 3, and 5 days after wounding, and specimens were taken using a 4 mm biopsy punch. At each time point, 6 mice were used for histological analysis and the specimens were fixed in a 10% formaldehyde solution.

Specimen preparation. The specimens were fixed in a 10% formaldehyde solution at room temperature, dehydrated in a graded series of ethanol and embedded in Paraplast (Sherwood

Table I. Wound areas ($\mu\text{m}^2 \times 10^5$) of oral mucosa (mean \pm SD) in control and aucubin-treated mice.

	Days after wounding		
	1	3	5
Control	4.28 \pm 0.78	4.14 \pm 0.71	2.71 \pm 0.38
Aucubin	3.68 \pm 0.36*	3.32 \pm 0.34**	2.54 \pm 0.50

Significantly different from the control: * $p < 0.05$, ** $p < 0.01$.

Medical Industries, St. Louis, USA). The paraplasm-embedded tissues were cut to a 6 to 7 μm thickness with a Microtome (Reichert-Jung 820, Nussloch, Germany) and stained with hematoxylin and eosin for re-epithelialization, and Giemsa for inflammatory cell infiltration. For an analysis of collagen deposition, the paraffin sections were deparaffinized and rehydrated, and then stained with Masson's trichrome and picrosirius red.

Quantitative histologic analysis. The distance between the epithelial margins of the wound was measured from the sections taken at the central part of each wound, where the wound was widest, using the AxioVision 3.1 software (Carl Zeiss Vision GmbH, Muenchen-Hallbergmoos, Germany). The number of inflammatory cells of the left, middle, and right wound areas in the Giemsa stained sections were counted using the AxioVision 3.1 software (Carl Zeiss Vision GmbH).

Statistics. The differences in the mean values were evaluated by analysis of variance (Student's *t*-test). *P*-values < 0.05 were considered significant.

Results

The rate of oral wound repair was determined by measuring the wound areas ($\mu\text{m}^2 \times 10^5$) along the edges of the healing epithelium and connective tissue at 1, 3, and 5 days after wounding. Complete coverage of the wound site had not occurred by day 5 in either group. The wound area of the aucubin-treated group was reduced significantly at day 1 ($p < 0.05$) and 3 ($p < 0.01$). However, there was no difference between the two groups at day 5 (Table I).

The anti-inflammatory effect of aucubin was determined by counting the inflammatory cells in three distinct areas (left, middle and right wound area). There were significantly fewer inflammatory cells in the wounds of the aucubin-treated group. In particular, there were fewer inflammatory cells on day 5 compared with the wound areas of the control group ($p < 0.05$) (Table II).

In order to measure the effect of aucubin on collagen synthesis, the specimens were stained with Masson's trichrome and picrosirius red. The results revealed a significant higher amount of newly accumulated collagen

Table II. The number of inflammatory cells (mean \pm SD) in wound areas of control and aucubin-treated mice.

	Days after wounding		
	1	3	5
Control	1342.38 \pm 212.03	1219.63 \pm 281.05	1118.88 \pm 194.39
Aucubin	1298.33 \pm 117.74	1145.86 \pm 270.50	901.13 \pm 198.87*

*Significantly different from the control, $p < 0.05$.

in the healing area of the aucubin-treated group compared with that in the control at day 5 (Figure 1).

Discussion

Wound healing is a complex process involving a variety of cellular and matrix components acting in concert to reestablish the integrity of the injured tissue. The complexity of the healing response can be simplified into four broad categories that coincide with the temporal sequence of normal healing: hemostasis, inflammation, cell proliferation (repair) and tissue remodeling. After tissue injury, red blood cells and platelets aggregate and form an initial hemostatic plug to protect the wound. Within 24 hours, neutrophils enter the wound site and scavenge cellular debris, foreign bodies and bacteria. After 2-3 days, the inflammatory cell population begins to shift to macrophages and fibroblasts appear in the wound site. After 3-5 days, the fibroblasts become activated and begin synthesizing collagen. As the collagenous matrix forms, densely packed fibers fill the wound site and during remodeling, the wound gradually becomes stronger with time (14).

It has been reported that the oral mucosa heals faster than skin, and wound healing in the oral mucosa is clinically different from dermal wound healing in terms of both its rapidity and lack of scar formation (15). Several factors are believed to contribute to these differences such as gingival fibroblasts (16), saliva (17) and many intrinsic factors (18). However, an oral wound cannot be protected by bandages; moreover the environment of the oral cavity with a relatively large commensal flora and the possibility of trauma from mastication can be deleterious to oral wound healing (19). Therefore, drugs that can protect the wound area and accelerate the wound healing process are needed. Most synthetic drugs used for oral wound healing have many adverse effects (2). Hence, many researchers have examined the potential of medicinal plants which may have more healing effects and fewer adverse effects than other chemicals (20, 21).

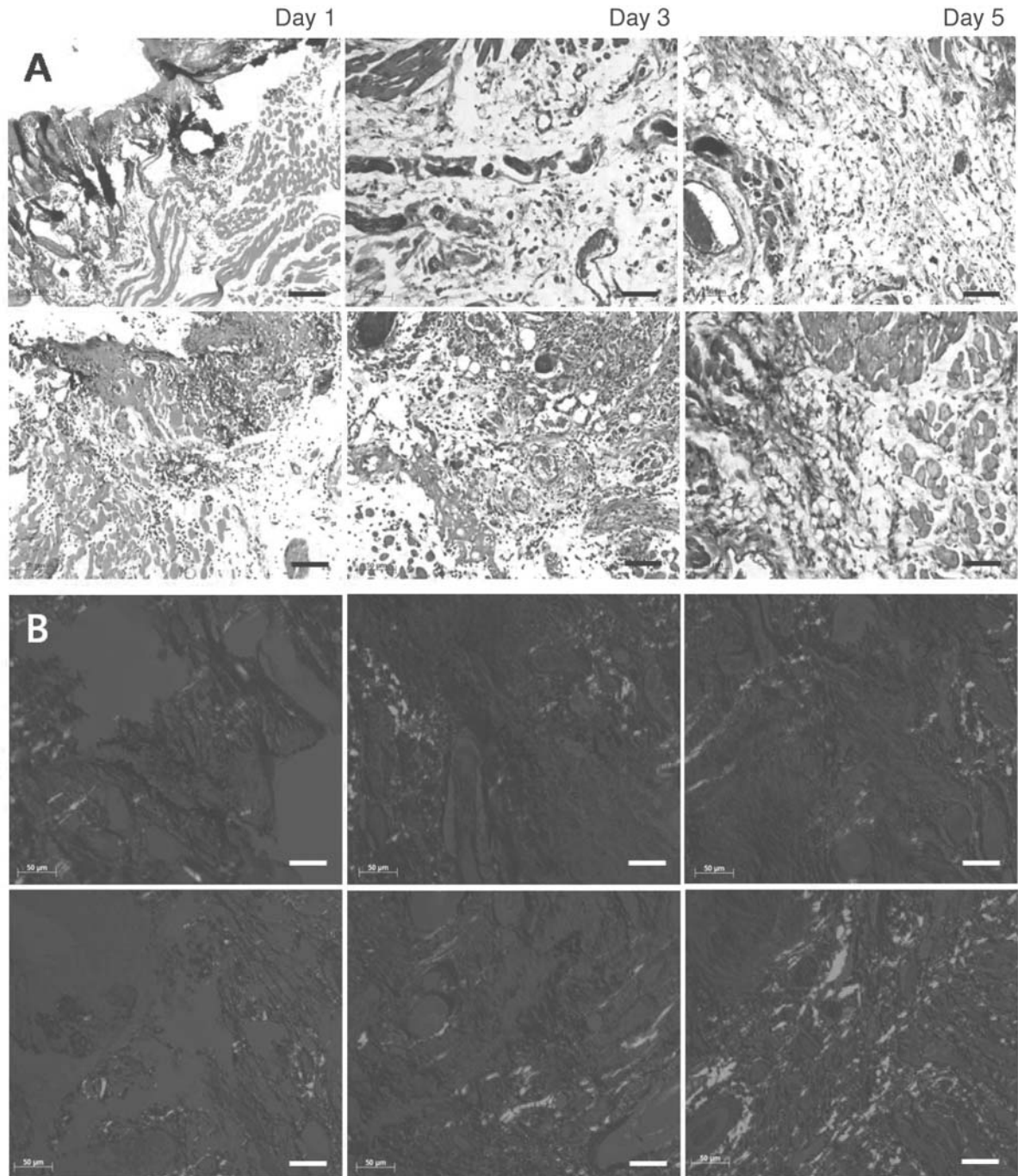


Figure 1. Difference in accumulated collagen as shown by staining with Masson's trichrome (A) and picrosirius (B) in the healing area of the control (upper panels) and aucubin-treated (lower panels) groups. The amount of collagen in the healing area into which aucubin was injected was significantly higher than that of the controls at day 3 and day 5. Scale bars: A 100 μ m, B 50 μ m.

Previous studies have reported that aucubin may exert its anti-inflammatory effects by inhibiting Ag-induced TNF- α and IL-6 production and expression by blocking NF- κ B activation in RBL-2H3 mast cells (22). Moreover, a topical application of a 0.1% aucubin solution showed

antimicrobial activity by inhibiting the RNA and protein biosynthesis of salivary microorganisms (23). Lee *et al.* reported that the application of a 0.1% aucubin solution accelerated re-epithelialization and fibrosis on a dermal artificial surgical wound and suggested the possibility of

using aucubin as a topical agent (13). In addition, Ho *et al.* reported that aucubin has photoprotective effects against oxidative stress by inhibiting UVB-induced free radical production in human skin fibroblasts (24). However, there are no reports on the effects of aucubin on oral wound healing.

In the study of the effect of aucubin on dermal wound healing, a difference between the control and aucubin-treated groups appeared on day 5 (13) whilst in the present study a difference was apparent to day 3; the difference between dermal and oral wound healing may be due to the numerous intrinsic healing factors present in the oral cavity.

There were fewer inflammatory cells in the aucubin-treated group than the control group on day 5, which might be due to the anti-inflammatory and antimicrobial activities of aucubin. As mentioned previously, aucubin inhibits RNA and protein biosynthesis of salivary microorganisms, and decreases the amount of IL-6 and TNF- α production in mast cells (22, 23). In addition, Bermejo *et al.* reported that aucubin inhibits the release of LTC4 and has a significant effect on release of TXB2 from calcium ionophore stimulated human platelets, with slightly lower inhibition percentages than those of the reference drug, ibuprofen (25).

The level of collagen matrix formation in the two groups appeared to be different on day 5. This is slightly different from that reported by Lee *et al.* who reported that the difference in collagen matrix formation on dermal wounds aucubin-treated and non-treated groups was significant on day 9 (13). This interval between dermal and oral wound healing may be accounted for by the growth and migration properties of the gingival fibroblasts, which are more conducive to healing than are dermal fibroblasts.

In conclusion, a 0.1% aucubin solution has an anti-inflammatory effect on oral mucosal wound healing, and promotes early re-epithelialization and collagen matrix formation. These results are similar to those of other studies comparing the extent of repair at the oral mucosal and cutaneous sites. It is believed that a 0.1% aucubin solution has potential use as a topical agent for oral wound healing. However, it is unclear why re-epithelialization and collagen matrix formation were accelerated. Further research will be needed to determine the mechanism for the effect of aucubin on oral wound healing and the optimal effective formulation.

Acknowledgements

This work was supported by the Korea Research Foundation Grant funded by the Korean Government (KRF-R05-2004-000-11343-0).

References

- Cleland WP: Opportunities and obstacles in veterinary dental drug delivery. *Advanced Drug Delivery Reviews* 50: 261-275, 2001.
- Gjermeo P: Chlorhexidine and related substances. *J Dent Res* 68: 1602-1608, 1989.
- Bae KH, Lee BJ, Jang YK, Lee BR, Lee WJ, Chang DS, Moon HS, Paik DI and Kim JB: The effect of mouthrinse products containing sodium fluoride, cetylpyridinium chloride (CPC), pine leaf extracts and green tea extracts on the plaque, gingivitis, dental caries. *J Korean Acad Dent Health* 25: 51-59, 2001.
- Chang IM, Park YC and Yun HS: Inhibition of ribonucleic acid biosynthesis in leukemia SN 36 cells *in vitro* by aucubin. *Korean Biochem J* 15: 200-204, 1982.
- Chang IM: Liver-protective activities of aucubin derived from traditional oriental medicine. *Res Common Mol Pathol Pharmacol* 102: 189-204, 1998.
- Miyagoshi M, Amagaya S and Ogihara R: Choleric actions iridoid compounds. *J Pharmacobio-Dyn* 11: 186-190, 1988.
- Circosta C, Occhiuto F, Ragusa S, Trovato A, Tumino G, Briguglio F and De Pasquale A: A drug used in traditional medicine: *Harpagophytum procumbens* DC. II. Cardiovascular activity. *J Ethnopharmacol* 11: 259-274, 1984.
- Fleer H and Verspohl EJ: Antispasmodic activity of an extract from *Plantago lanceolata* L. and some isolated compounds. *Phytomedicine* 14: 409-415, 2007.
- Ishiguro K, Yamaki M and Takagi S: Studies on the iridoid-related compound. I. On the antimicrobial activity of aucubigenin and certain iridoid aglycones. *Yakugaku Zasshi* 102: 755-759, 1982 (in Japanese).
- Kupeli E, Tatli II, Akdemir ZS, Yesilada E: Bioassay-guided isolation of anti-inflammatory and antinociceptive glycoterpenoids from the flowers of *Verbascum lasianthum* Boiss. ex Benth. *J Ethnopharmacol* 110: 444-450, 2007.
- Maria DCR, Rosa MG, Manez S and Rios JL: Structural considerations on the iridoids as anti-inflammatory agents. *Plant Med* 60: 232-234, 1994.
- Chang KS, Yun HS and Chang IM: Effects of aucubin on DNA and RNA biosyntheses in sarcoma 180 cells. *Korean Biochem J* 22: 322-326, 1989.
- Lee SW, Kho HS and Lee SG: The effects of iridoid compounds on wound healing. *J Korean Acad Oral Med* 24: 137-142, 1999.
- Norton JA, Bollinger RR, Chang AE, Lowry SF, Mulvihill SF, Pass HI, Thomson RW and Li M: Basic science and clinical evidence. *In: Essential Practice of Surgery*. New York, Springer-Verlag, pp. 77-88, 2003.
- Szpadarska AM, Zuckerman JD and DiPietro LA: Differential injury responses in oral mucosal and cutaneous wounds. *J Dent Res* 82: 621-626, 2003.
- Schor SL, Ellis I, Irwin CR, Banyard J, Seneviratne K, Dolman C, Gilbert AD and Chisholm DM: Subpopulations of fetal-like gingival fibroblasts: Characterization and potential significance for wound healing and the progression of periodontal disease. *Oral Dis* 2: 155-166, 1996.
- Mandel ID: The functions of saliva. *J Dent Res* 66: 623-627, 1987.

- 18 Zelles T, Purushotham KR, Macauley SP, Oxford GE and Humphreysbeher MG: Saliva and growth factors: the fountain of youth resides in us all. *J Dent Res* 74: 1826-1832, 1995.
- 19 Nooh N and Graves DT: Healing is delayed in oral compared to dermal excisional wounds. *J Periodontal* 74: 242-246, 2003.
- 20 Biswas TK and Mukherjee B: Plant medicines of Indian origin for wound healing activity: a review. *Int J Low Extrem Wounds* 2: 25-39, 2003.
- 21 Davis RH, Leitner MG, Russo JM and Byrne ME: Wound healing. Oral and topical activity of *Aloe vera*. *J Am Podiatr Med Assoc* 79: 559-562, 1989.
- 22 Jeong HJ, Koo HN, Na HJ, Kim MS, Hong SH, Eom JW, Kim KS, Shin TY and Kim HM: Inhibition of TNF- α and IL-6 production by aucubin through blockade of NF- κ B activation in RBL-2H3 mast cells. *Cytokine* 18: 252-259, 2002.
- 23 Lee ES, Ahn JW, Mar WC and Chang IM: Pharmacology of iridoid: Antimicrobial activities of aucubin. *Kor J Pharmacog* 17: 129-133, 1986.
- 24 Bermejo Benito P, Diaz Lanza AM, Silvan Sen AM, De Santos Galindez J, Fernandez Matellano L, Sanz Gomez A and Abad Martinez MJ: Effects of some iridoids from plant origin on arachidonic acid metabolism in cellular systems. *Planta Med* 66: 324-328, 2000.
- 25 Ho JN, Lee YH, Park JS, Jun WJ, Kim HK, Hong BS, Shin DH and Cho HY: Protective effects of aucubin isolated from *Eucommia ulmoides* against UVB-induced oxidative stress in human skin fibroblasts. *Biol Pharm Bull* 28: 1244-1248, 2005.

Received June 4, 2007

Revised August 21, 2007

Accepted August 30, 2007