

Ten Years Experience in the Treatment of *Pseudomyxoma peritonei* by Cytorreduction, Peritonectomy and Semi-closed Hyperthermic Antiblastic Peritoneal Perfusion

M. DE SIMONE¹, M. VAIRA¹, A. CAPONI¹, B. CIACCIO¹,
G. FIORENTINI², G. TURRISI², L. FERRI³ and G. BUTI³

¹General and Oncological Surgery Department and

³Intensive Care Unit, Osp. S. Giuseppe, V.le Boccaccio 12, 50053-Empoli, Florence;

²Medical Oncology Department, Osp. S. Giuseppe, V. Paladini 40, 50053-Empoli, Florence, Italy

Abstract. *Background:* In the literature good results have been reported for the treatment of *Pseudomyxoma peritonei* (PMP) by cytorreduction, peritonectomy and hyperthermic antiblastic peritoneal perfusion (H.A.P.P.). Forty-eight patients affected by PMP have been treated with this technique over the past ten years. *Patients and Methods:* Peritoneal perfusion has been performed with the original semiclosed technique after complete surgical cytorreduction in 188 patients affected by peritoneal carcinomatosis. In 48 of the cases the patients were affected from PMP. Aggressive surgical cytorreduction was performed with multiple visceral resections and peritonectomies. *Results:* Seventeen patients (38%) presented major perioperative complications, and in five cases the reoperation of the patient was required. In spite of this high complication rate, there was no perioperative mortality. The results of the Kaplan-Meier 5- and 10-year survival analysis, were 94% and 82%, respectively, with a disease-free survival of 80% at 5 years and 70% at 10 years. Thirty-nine patients (81.2%) had no evidence of disease at follow-up (range 1-120 months). *Discussion:* Up to date, the most effective treatment for PMP has been aggressive cytorreduction plus H.A.P.P.

In the literature, an improvement in overall survival and disease-free interval in the treatment of *pseudomyxoma peritonei* (PMP) has been reported by cytorreduction, peritonectomy and hyperthermic antiblastic peritoneal perfusion (H.A.P.P.) (1-3). PMP arises from an adenoma or

an adenocarcinoma of the appendix. Rarely, the origin could be a myxoid ovarian cancer. The peritoneal cavity could be considered as a "pharmacological sanctuary", because the presence of the peritoneal-plasmatic barrier prevents leakage to the systemic circulation of high molecular weight drugs. Therefore, a high concentration of cytostatic drugs can be administered into the tumor area, with mild side-effects. H.A.P.P. has maximal efficacy when all the macroscopic disease has been removed with cytorreduction and peritonectomy (4-8).

Patients and Methods

From October 1995 to June 2006, 288 operations for peritoneal carcinomatosis had been performed; 36 explorative laparotomies; 49 debulking without H.A.P.P.; 15 cytorreduction with E.P.I.C. (early post-operative intraperitoneal chemotherapy); and 188 H.A.P.P. in 180 patients. Sixty-four patients affected by PMP were operated on: six explorative laparotomies; nine debulking without H.A.P.P.; one cytorreduction associated with E.P.I.C.; and 48 peritonectomies, cytorreduction and H.A.P.P. For those 48 patients, the median age was 58 years (range 32-72), 23 were male (47.9%) and 25 female (52.1%). The primitive neoplasia was an appendicular adenocarcinoma in 36 patients (75%), an appendicular adenoma in 11 patients (23%) and an ovarian myxoid adenocarcinoma in one patient (2%). Forty-five patients (93.7%) had been operated previously in other centers (range 1-4 operations). Because of the massive involvement of the viscera and the peritoneum, in a selected group of patients, the treatment was performed in more steps (three patients were treated in 2 steps, and one patient in 3). An aggressive surgical cytorreduction was performed in all patients: 43 omental resections, 25 resections of the left colon and rectum, 30 right or transverse colon resections, 13 hysterectomies, 17 oophorectomies, 36 spleen resections, 30 cholecistectomies, 23 resections of the ileum, five total gastrectomies, three gastric resections, six pancreatic resections (body and tail), ten appendectomies, 41 right diaphragmatic peritonectomies, 33 left diaphragmatic peritonectomies, 37 pelvic peritonectomies, 32 Glisson's capsule removals and 30 less omentum resections. The reconstructive time requested: 53 bowel anastomoses,

Correspondence to: Dr. Michele De Simone, Oncological Surgery Department, V.le Boccaccio, 12, 50053, Empoli, Florence, Italy. Tel: +39 0571 705678 / +39 347 9203797, Fax: +39 0571 705286, e-mail: mdesi1@inrete.it / vairus72@hotmail.com

Key Words: *Pseudomyxoma peritonei*, peritonectomy, chemotherapy, hyperthermia.

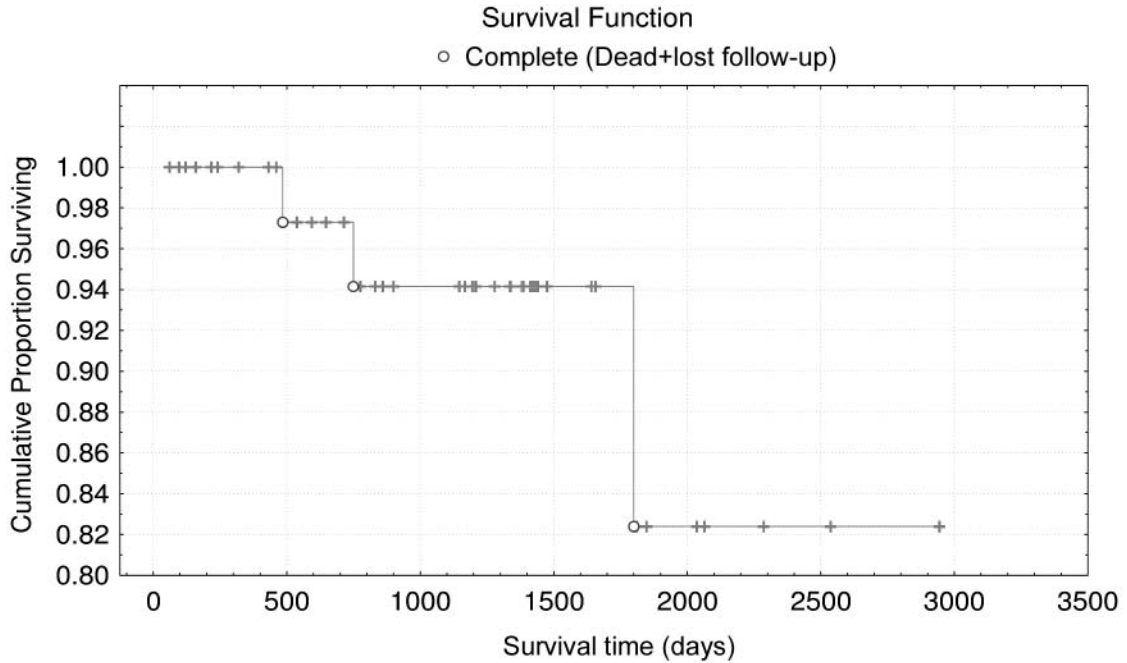


Figure 1. Kaplan-Meier cumulative survival analysis at five and ten years on 48 cases of PMP.

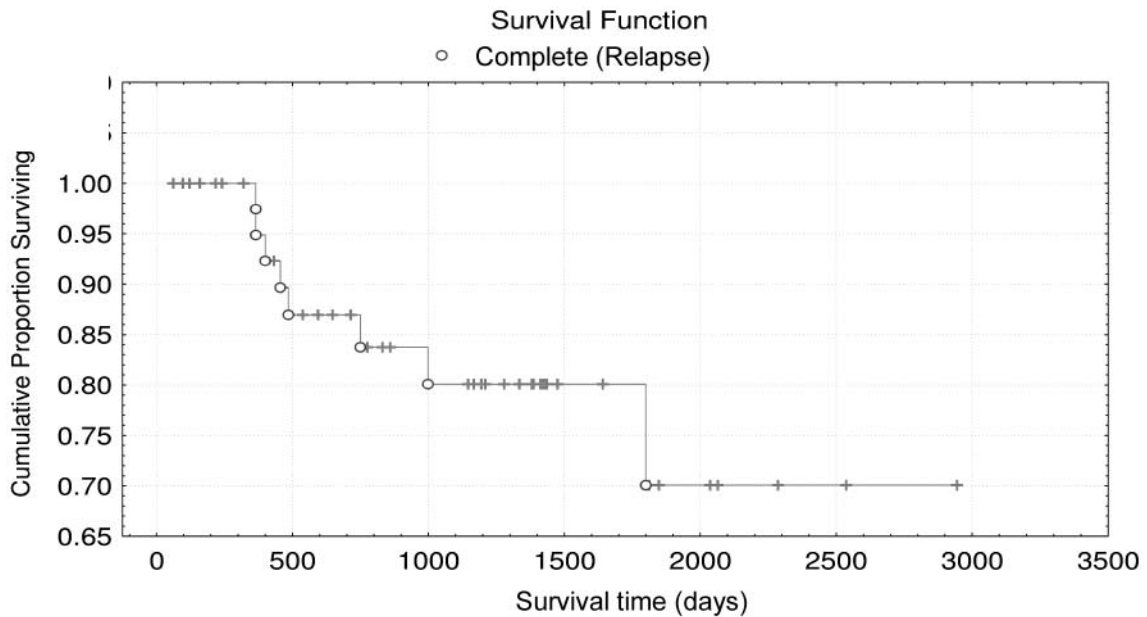


Figure 2. PMP disease free survival at five and ten years on 48 cases of PMP.

35 jejunostomies for temporary enteral feeding and 22 temporary ileostomies to protect the anastomoses. When complete cytoreduction had been achieved, the procedure has been completed by H.A.P.P.

The "semi-closed" technique (9) consists of placing five drainage tubes (two inflow and three outflow drains) into the abdominal cavity. The inflow ones present multiple stomata, are Y-shaped and present four diffusion lines for the homogeneous distribution of

drugs into the abdominal cavity (one subdiaphragmatic branch, one sovramesocolic branch, one among the ileal loops and one in the pelvis). The three outflow tubes are placed respectively in the pelvis and in the subdiaphragmatic spaces. Backaus forceps are used to close the cranial and caudal portions of the abdominal wound. The skin is then suspended to a self-retaining retractor, by plastic self-blocking strings. The central portion of the wound is suspended to the retractor too, and covered with a PVC sheet that presents a hole

in the middle. The drainage tubes are connected to a perfusion system formed by two pumps and a heat exchanger to heat the perfusion liquid. The pumps (inflow and outflow), are connected through a reservoir and are controlled by a computed system. The intraperitoneal temperature is checked by three probes; other three probes are used to check the inflow, the outflow, and the patient oesophageal temperature. When the ideal intraperitoneal temperature is reached, the drugs are added to the circuit and the H.A.P.P. is performed for 60 minutes.

Forty-six of the patients in our series were treated with a protocol based on the administration of Cisplatin 100 mg/sm plus C-Mitomycin 16 mg/sm for 60 minutes, with a peritoneal temperature of 41.7°C. Two of the patients have been treated with C-Mitomycin 35 mg/sm because of intolerance to platinum (10-11). The median duration of the operation was 12 hours (range: 8-16).

Results

Seventeen patients (38%) presented major peri-operative complications. The most common complications were: sepsis (twelve patients; in three cases sepsis was a consequence of reoperation for bowel perforation or hemorrhage); five bowel or urinary tract perforations that in two cases surgical repair was required, in the other cases the resolution of fistulas was obtained with conservative treatment (stenting of urinary tract in two cases, *i.v.* feeding for a gastric perforation); two cases of post-operative hemorrhage that required reintervention in one case; one case of abdominal wall dehiscence after 20 days from operation that required reintervention. In spite of this high complication rate, there was no peri-operative mortality. The results were very encouraging – the 5- and 10-year Kaplan-Meier survival analysis, were 94% and 82%, respectively. The disease-free survival was 80% at 5 years and 70% at 10 years (Figures 1 and 2). Thirty-nine patients (81.2%) were N.E.D. (no evidence of disease) at a follow-up of 1-120 months. Of the remainin patients: one has been lost at follow-up after 48 months and has been excluded from the analysis; one patient D.O.D. (died of disease) 6 months after the operation; three patients were A.W.D. (alive with disease) at a follow-up of 39-47 months; three patients, who presented intraperitoneal relapse and were treated with tumor resection and H.A.P.P. again, were N.E.D. at a follow-up of 2-15 months; one patient, who presented a single pelvic relapse that has been removed without performing a new H.A.P.P., was N.E.D. at a follow-up of 13 months.

Discussion

Until now, no other treatment seems to be as effective as aggressive cytoreduction plus H.A.P.P. for PMP (five-year survival: 94%, ten-year survival 82%). In fact, results from other studies report five- and ten-year survival after multiple debulking operations 54% and 18%, respectively (12). In our experience, a lot of patients observed, were treated only by

surgical debulking and were not eligible for H.A.P.P. because of ileum infiltration due to multiple previous non-radical operations. Moreover, in our series of 48 patients treated by H.A.P.P., the only location of relapse in two cases was a single neoplastic mass at the site of previous non-radical operations. Observing the data, we consider it mandatory to refer the patients with suspected or diagnosed PMP to a specialized center for the treatment of this rare neoplasia.

References

- 1 Sugarbaker PH, Ronnett BM, Archer A, Averbach AM *et al*: Pseudomyxoma peritonei syndrome. *Adv Surg* 30: 233-280, 1996.
- 2 Glehen O, Sugarbaker PH, Elias D, De Simone M *et al*: Cytoreductive surgery combined with perioperative intraperitoneal chemotherapy for the management of peritoneal carcinomatosis from colorectal cancer. A multi-institutional study for 506 patients. *J Clin Oncol* 22: 3284, 2004.
- 3 Sugarbaker PH and Chang D: Results of treatment of 385 patients with peritoneal surface spread of appendiceal malignancy. *Ann Surg Oncol* 6(8): 727-731, 1999.
- 4 Averbach AM and Sugarbaker PH: Methodologic considerations in treatment using intraperitoneal chemotherapy. *Cancer Treat Res* 82: 289-309, 1996.
- 5 Cavaliere F, Perri P, Di Filippo F, Giannarelli D *et al*: Treatment of peritoneal carcinomatosis with intent to cure. *J Surg Oncol* 74(1): 41-44, 2000.
- 6 Gilly FN, Carry PY, Sayag AC, Brachet A *et al*: Regional chemotherapy (with mitomycin C) and intra-operative hyperthermia for digestive cancers with peritoneal carcinomatosis. *Hepatogastroenterology* 41(2): 124-129, 1994.
- 7 Loggie BW, Fleming RA, McQuellon RP, Russell GB *et al*: Cytoreductive surgery with intraperitoneal hyperthermic chemotherapy for disseminated peritoneal cancer of gastrointestinal origin. *Am Surg* 66(6): 561-568, 2000.
- 8 De Simone M and Vaira M: Cytoreduction, peritonectomy and hyperthermic antitlastic peritoneal perfusion for the treatment of peritoneal carcinomatosis. *In: Hyperthermia in Cancer Treatment: A Primer*. Baronzio GF and Hager D (eds.). Eurekah.com and Springer Science+Business Media-U.S.A., 2006.
- 9 De Simone M, Barone R, Vaira M, Aghemo B *et al*: Semi-closed hyperthermic-antitlastic peritoneal perfusion (HAPP) in the treatment of peritoneal carcinosis. *J Surg Oncol* 82(2): 138-140, 2003.
- 10 Elias D, Antoun S, Raynard B, Puizillout JM *et al*: Treatment of peritoneal carcinomatosis using complete excision and intraperitoneal chemohyperthermia. A phase I-II study defining the best technical procedures. *Chirurgie* 124(4): 380-389, 1999.
- 11 Verwaal F *et al*: Treatment of peritoneal carcinomatosis from colorectal cancer with hyperthermic antitlastic peritoneal perfusion. *J Clin Oncol* 21: 3737, 2003.
- 12 Fernandez RN and Daly JM: Pseudomyxoma peri-tonei. *Arch Surg* 115: 409-414, 1980.

Received July 4, 2006
Revised October 31, 2006
Accepted November 1, 2006