

Errata

Volume 20 (2006), page 81:

Figures 5 and 6 should be printed in color:

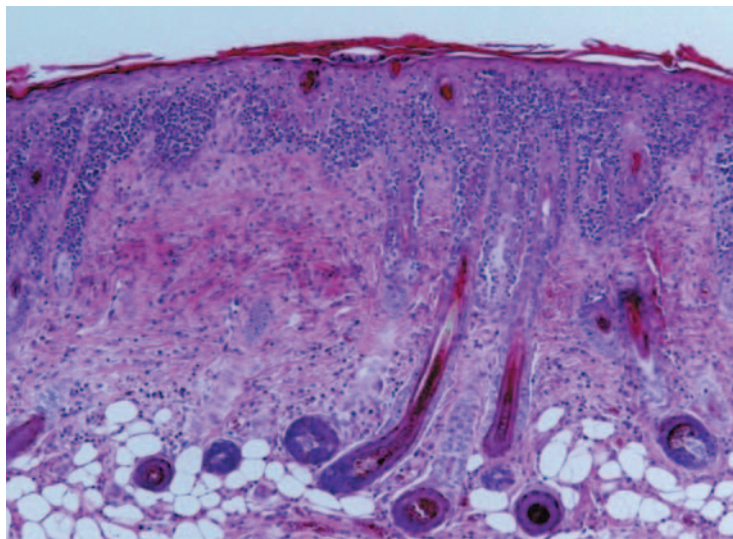


Figure 5. Histological features of skin lesions in control mice 56 days after PiCl sensitization. Marked hypertrophy of the epidermis and severe lymphocyte infiltration into the epidermis were observed. Extracellular edema of the epidermis and liquefaction degeneration of the basal layer were also observed. Hematoxylin & eosin-stained section (magnification x89).

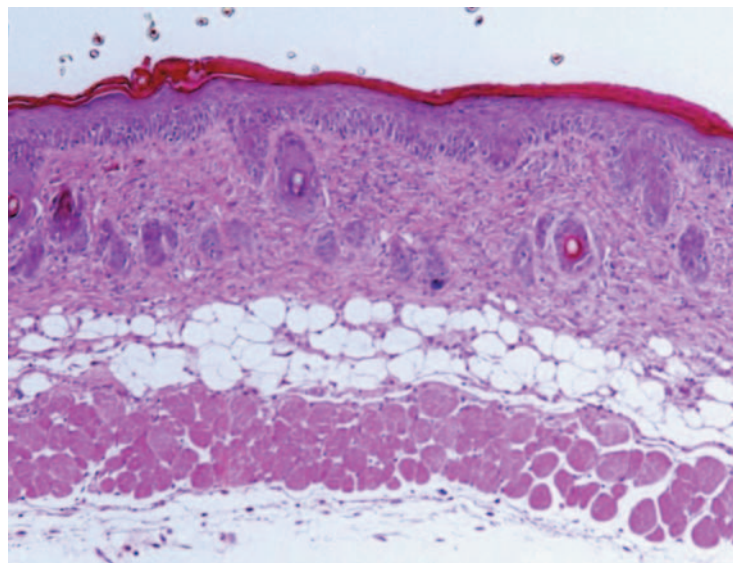


Figure 6. Histological features of skin lesions in mAgK114-treated mice 56 days after PiCl sensitization. Mild hypertrophy of the epidermis, hyperkeratinosis and only a trace of lymphocyte infiltration into the basal strata were observed. Hematoxylin & eosin-stained section (magnification x89).