

## The Effect of Alcohol and Gemfibrozil Co-administration in Wistar Rats

GENOVEFA D. KOLOVOU<sup>1</sup>, DIMITRI P. MIKHAILIDIS<sup>2</sup>, NIKOLAOS KAFALTIS<sup>1</sup>,  
EVDOKIA N. ADAMOPOULOU<sup>1</sup>, ELEFTERIOS YAZITSOGLU<sup>1</sup>, AGGELIKI HATZAKI<sup>1</sup>,  
NECTARIOS PILATIS<sup>1</sup>, ALEXANDRA P. MARGELI<sup>3</sup>, KLELIA D. SALPEA<sup>1</sup>,  
MICHAEL MYKONIATIS<sup>3</sup> and DENNIS V. COKKINOS<sup>1</sup>

<sup>1</sup>Cardiology Department, Onassis Cardiac Surgery Center, Athens, Greece;

<sup>2</sup>Department of Clinical Biochemistry, Vascular Disease Prevention Clinics, Royal Free Hospital, London, U.K.;

<sup>3</sup>Department of Experimental Pharmacology, Athens University Medical School, Athens, Greece

**Abstract.** *Introduction:* The ingestion of alcohol (Alc) as well as gemfibrozil (Gem), a fibrate drug used to treat hypertriglyceridaemia, may occur on a long-term basis in humans. Since both Alc and Gem can disturb liver function, we assessed the effects of administering Alc together with Gem in Wistar rats. *Materials and Methods:* Male Wistar rats were randomized and divided into 4 groups of 10 each. They were fed (once a day) via a stomach tube with: i) 2 ml of polyethylene glycol (Peg); group Peg, ii) 2 ml of Peg + 2 ml of 25% v/v pure Alc in water; group Alc+Peg, iii) 2 ml of Gem solution in Peg (3.4 mg/100g body weight); group Gem+Peg, iv) 2 ml of Gem solution in Peg 2 + 2 ml of Alc; group Gem+Alc+Peg. Another 13 male Wistar rats were only fed a standard laboratory diet (control group). After 8 weeks, blood samples were drawn and the livers removed. Alanine aminotransferase (ALT), aspartate aminotransferase (AST), alkaline phosphatase (AP), total cholesterol (TC) and triglycerides (TG) were measured. Liver histopathology was also assessed. *Results:* All tube-fed groups had higher body mass index compared to controls ( $p < 0.001$ ). The control group had lower AP compared to Gem+Peg and Gem+Alc+Peg groups ( $p = 0.005$  and  $p = 0.018$ , respectively). The Peg group had lower AP compared to G+Peg ( $p = 0.041$ ). All tube-fed groups had lower ALT compared to controls ( $p < 0.001$ ). The TC levels were lower in tube-fed groups with Gem (Gem+Peg and Gem+Alc+Peg) compared to controls ( $p = 0.002$  and  $p = 0.039$ , respectively). Among the tube-fed groups, the TC level was lower in Gem+Peg compared to Peg and Alc+Peg groups ( $p = 0.047$  and  $p = 0.01$ , respectively). No differences were found among tube-fed groups and control rats

in blood AST and TG. Liver histopathology was similar in all groups and within the normal range. *Conclusion:* A moderate amount of Alc daily together with Gem is safe in rats. Peg administration in Wistar rats protects from the Alc-induced TG and AST rises.

Gemfibrozil (Gem), a derivative of fibric acid, is used in the treatment of hypertriglyceridemia (1). Gem is effective in reducing plasma triglycerides (TG), yet the mechanism of action is not clearly understood (2,3). Although Gem can cause hepatotoxicity, hepatic peroxisome proliferation and cancer in rats, no Gem-induced hepatotoxicity has been reported in humans (4,5). Excessive alcohol (Alc; ethanol) use can cause a fatty liver and alcoholic liver cirrhosis, cardiomyopathy, hypertension, hemorrhagic stroke, cardiac arrhythmias or sudden death (6). On the other hand, there is evidence for an inverse association between light-to-moderate Alc use and the risk of vascular events (7-14).

The introduction of fibric acid derivatives has been an important step in the treatment of dyslipidemias (15,16). Treatment with hypolipidemic drugs should be continued for life in most patients. Therefore, an important question is whether Alc consumption affects the efficacy and safety of these drugs. In line with our previous study where we assessed the effect of simvastatin and Alc co-administration (17), the present study evaluated the effects of 8 weeks co-administration of Alc and Gem in male Wistar rats.

### Materials and Methods

*Animals.* All studies were conducted in accordance with federal guidelines for the care and use of laboratory animals. The Ethics Committee of the Department of Experimental Pharmacology, Athens University, Greece, approved our study protocol. Fifty-three normolipidemic male Wistar rats (8 weeks old at the start of the experiment) were purchased from the Hellenic Pasteur Institute, Athens, Greece. The animals were held on a light/darkness cycle of 12-h intervals in an air-conditioned room. The temperature was

Correspondence to: Genovefa D. Kolovou, Onassis Cardiac Surgery Center, 356 Sygrou Ave, 176 74 Athens, Greece. Tel: +30210 9493520, Fax: +30210 9493336, e-mail: Genkolovou@mail.gr

Key Words: Gemfibrozil, ethanol, liver, dyslipidaemia, transaminase.

Table I. Body weight (BW), alanine aminotransferase (ALT), aspartate aminotransferase (AST), alkaline phosphatase (AP), total cholesterol (TC) and triglycerides (TG) in all groups.

	Groups				
Variables:	Control	Peg	Alc+Peg	Gem+Peg	Gem+Alc+Peg
BW [g]	313 (10)	357 (16)	363 (12)	332 (15)	346 (23)
AP [mIU/ml]	65 (19)	69 (8)	75 (12)	90 (14)	88 (11)
ALT [mIU/ml]	60 (9)	36 (6)	44 (6)	38 (4)	40 (7)
AST [mIU/ml]	146 (21)	152 (18)	163 (39)	166 (26)	158 (57)
TC [mg/dl]	64 (13)	56 (9)	59 (7)	45 (3)	49 (8)
TG [mg/dl]	76 (14)	63 (23)	74 (15)	70 (15)	66 (12)

Variables are presented as means (SD).  
 $p < 0.001$  between controls and all other groups.

kept at 18-22°C. The animals were acclimatized for 10 days under these conditions before starting the study. All animals had free access to water and food. Their body weight was measured at the beginning and at the end of the study. In addition to the standard rat laboratory diet (10-15 g daily), 2 or 4 ml of liquid was administered by gastric intubation once a day, for 8 weeks, in 40 rats. Every time before tube feeding slight anaesthesia with halothane was administered. At the end of the study at 8.30 -10.00 the rats were anaesthetized and sacrificed by decapitation. Blood samples were collected and their livers were removed for histopathological examination. The rats were randomized and assigned to four groups of 10 each and to a control group of 13 rats. Every group except for the control group was stomach tube-fed at 17:00 every day.

Group Peg: These animals were tube-fed with 2 ml of polyethylene glycol 400 (Peg 400). Peg was chosen as a carrier for Gem. Peg 400 is a high molecular weight polymer of ethylene oxide, whose average molecular weight, at room temperature, is 400. Having a molecular weight below 600 allows it to be a clear viscous liquid. Additionally, Pegs are water soluble and do not hydrolyze or deteriorate. These properties along with its compatibility render Peg 400 appropriate for our use as a carrier for Gem (18).

Group Alc+Peg: tube-fed with 2 ml of Peg and 2 ml of 25% v/v pure Alc in water.

Group Gem+Peg: tube-fed with 2 ml of Gem solution in Peg. Gem tablets (Lopid 600 mg) were powdered and dissolved in Peg in order to achieve a final concentration of 3.4 mg/100g body weight. The Lopid tablets are produced by Parke Davis (Gödecke AG, Freiburg, Germany) and they include methylhydroxypropylcellulose, titanium dioxide, talc, polydimethylsiloxane and polyethylene glycol 6000.

Group Gem+Alc+Peg: tube-fed with 2 ml of Gem solution in Peg and 2 ml of 25% v/v pure Alc in water.

Control Group: These animals were fed the standard rat laboratory diet only.

**Dose preparation.** Oral dose formulation was prepared in 2 ml solution of 0.25 ml/kg body weight of Peg at a target Gem dose of 3.4 mg/100g body weight. The daily Peg dose per animal was 0.05ml.

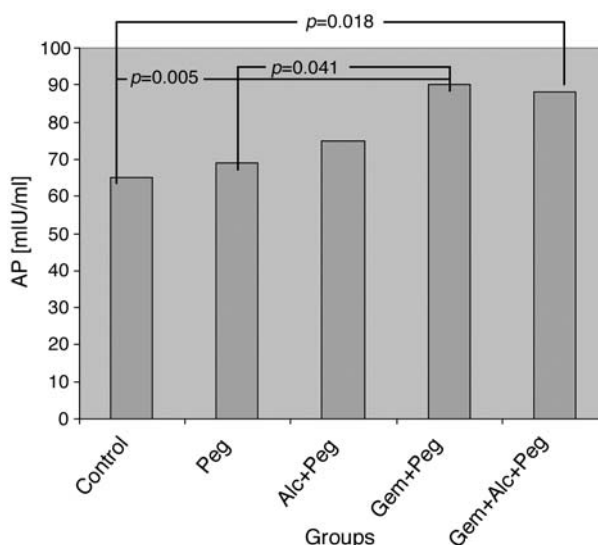


Figure 1. Alkaline phosphatase (AP) concentration in all groups.

**Blood samples.** Blood for lipid and liver function tests was collected at the end of the study from all animals. Blood total cholesterol (TC), triglycerides (TG), alkaline phosphatase (AP), alanine aminotransferase (ALT) and aspartate aminotransferase (AST) were measured (19).

Liver histopathology was examined after fixing in buffered formalin and embedding in paraffin wax, using conventional techniques (20,21). The possible Peg, Alc or Gem-induced morphological changes in the rat liver were assessed.

All animals were randomised and code numbers were given. Therefore, the examiner did not know the origin of the histology specimens or blood samples.

**Statistical analysis.** Continuous variables are presented as means (SD). The comparison between the five groups was performed with a one-way ANOVA test (the distribution of values was normal). *Post-hoc* analysis with a Bonferroni or Games-Howell (whichever appropriate) adjustment for between two group differences was performed to account for multiple group comparisons.

## Results

The body weight and the AP, ALT, AST, TC and TG levels of all groups are shown in Table I.

All the tube-fed groups had higher body weight compared to the controls ( $p < 0.001$ ). The control group had lower AP compared to the Gem+Peg ( $p = 0.005$ ) and the Gem+Alc+Peg ( $p = 0.018$ ) groups and the Peg group had lower AP compared to the Gem+Peg group ( $p = 0.041$ ) (Figure 1). All tube-fed groups had lower ALT compared to controls ( $p = 0.001$ ). No difference was found among tube-fed groups and control rats in blood AST. No difference was found among the tube-fed groups in blood ALT. The TG concentration was similar in all tube-fed groups and the

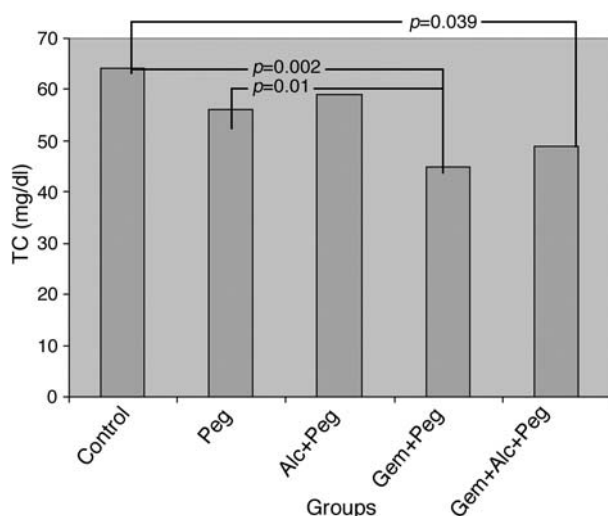


Figure 2. Total cholesterol (TC) concentration in all groups.

controls. TC levels were lower in the Gem+Peg and Gem+Alc+Peg groups compared to the control group ( $p=0.002$  and  $p=0.038$ , respectively). Additionally, TC levels were lower in the Gem+Peg group compared to the Peg group ( $p=0.01$ ) (Figure 2).

Examination of the liver specimens disclosed normal hepatic structure and cytology. However, there were moderate variations within the normal histology.

## Discussion

We evaluated the co-administration of Alc and Gem in rats. The absorption of Gem after oral administration is rapid and complete in humans, with peak plasma concentrations achieved in 1 to 2 h (22). In rats, the elimination half-life of Gem is 5-10 h after an oral dose (23). Rats excreted 25% of an oral dose of Gem in urine and 50% in faeces. Gem metabolites in urine include free and glucuronic acid conjugates of Gem, as well as metabenzoic acid, 2'-methylhydroxylated, 4'ring hydroxylated and meta-benzyl alcohol metabolites.

Peg was chosen as a carrier for Gem. Studies on toxicity of Peg in a dose of 2.5-5.0 ml/animal/day (0.25 ml/kg/daily) showed reversible kidney toxicity. However, no kidney toxicity of Peg was found at doses <2.5 ml/animal/day. We did not assess kidney function biochemically. However, in our study the Peg dose was 0.05 ml/animal/day, approximately 50x less than in other studies (18). This allowed us to conclude that Peg did not exert any toxic effect on kidney function in our animals.

Since the ingestion of Alc as well as Gem may occur on a long-term basis in man, and both can disturb the liver function, we focused on assessing liver function. Alc

consumption alters the liver redox state due to shortage of nicotinamide adenine dinucleotide ( $NAD^+$ ).  $NAD^+$  is the rate-limiting co-enzyme in the oxidation of ethanol by alcohol dehydrogenase (24-26). Another pathway for Alc oxidation is the cytochrome P450 system (27,28). The chronic consumption of Alc enhances the microsomal ethanol-oxidising system activity, which may lead to decreased drug metabolism (24,29). Alc consumption is a common cause of minor transaminase elevation which was seen by us (17) and others (30,31). A transient, minor and reversible elevation of the hepatic aminotransferase enzymes can also occur with Gem use but the reason is unknown (32,33). In our study, the rats fed Gem (Gem+Peg and Gem+Alc+Peg groups) had similar levels of AST compared to the rats fed with Alc (Alc+Peg group) or Peg (Peg group) and to the control group. The ALT levels in all tube-fed groups were significantly lower compared to controls. This may be due to a protective effect of Peg. Others (34) found that Peg decreased ALT levels by 80%. Independently of that fact, Gem studies in rats and hamsters demonstrated increase in ALT, accompanied by histological evidence of liver damage with doses never used in humans (4,5,32). It may be that Gem provokes hepatotoxicity and hepatic peroxisome proliferation, probably *via* its acyl glucuronide conjugate (4,23). The low urinary excretion and the enterohepatic recycling of the acyl glucuronide conjugate in rats may result in an increased exposure of the liver. This may be the cause of the observed hepatic peroxisome proliferation and/or hepatocarcinogenesis in rats, but not in humans (4,23). No histological changes in the liver were found in our animals treated with Gem, despite the relatively high Gem dose (equivalent to about 2380 mg/day for humans; the recommended dose for humans is 1200 mg/day). However, in another study (23), the Gem dose was much higher than ours (200 mg/100g compared to 34 mg/100g in our study) and yet no liver damage was seen. Furthermore, hepatotoxicity after short term exposure to Gem was observed in rats (4) at concentrations over 52 mg/100g, while concentrations of 33 mg/100g (approximately equal to ours) were shown to be safe. It is well known that Gem administration can raise AST activity, but this was not observed in our study. In contrast, AST activity was not elevated even in the rats fed with Alc and Peg (Alc+Peg group). This in contrast to our previous study (17) where raised AST activity was observed with simvastatin. We hypothesise that Peg had a protective effect on AST levels. Alc did not have any additional effect on AST levels, since the AST level in the Gem+Peg and Gem+Alc+Peg groups were identical.

TG levels were not raised in the groups administered Alc as would have been expected from our previous (17) and other studies (35,36). Additionally, the groups receiving Gem (Gem+Peg and Gem+Alc+Peg) had TG values similar to controls. The expected decrease in TG

levels after Gem administration was probably compensated by the action of Alc on TG, in the Gem+Alc+Peg group. Alc raises the TG levels by increased production and secretion of very low density lipoproteins (VLDL) (37,38). Alc can impair oxidation by the citric-acid cycle due to a shortage of NAD<sup>+</sup>. Instead, fatty acids are esterified with glycerol and secreted into the circulation as VLDL particles. We do not have a definite explanation of why there was no significant decrease in TG levels in the Gem+Peg group. This was probably due to the low baseline TG concentration.

TC and low density lipoprotein cholesterol (LDL-C) can either be increased by Alc intake, reflecting an increased turnover from VLDL cholesterol to LDL-C, or not be affected (23). In our study, we found lower plasma TC levels in the tube-fed rats with Gem (Gem+Peg and Gem+Alc+Peg) compared to controls and to those tube-fed without Gem (Peg and Alc+Peg) groups. Despite the low levels of baseline TC, Gem decreased TC levels.

There was no difference in liver histopathology despite the significantly different ALT and AP levels. Alc can cause hepatosteatosis, liver fibrosis and cirrhosis after chronic excessive consumption. The fact that our rats were exposed for 8 weeks to moderate Alc ingestion, compared to rats from studies that demonstrated liver histopathological alterations (39,40), may explain the lack of Alc-induced liver morphological changes. Dix *et al.* (23) found that repeated administration of low Gem doses did not alter the route of excretion and no new metabolites were detected in urine, meaning that no toxicity was provoked. In rats, a characteristic change produced by high dose Gem is hepatomegaly and hepatic peroxisome proliferation. In our study the Gem dose was low. This may explain why we did not find significant histopathological liver changes.

We have not found any study that evaluated the effects of co-administration of Gem and Alc. Our findings should stimulate further studies in humans, in order to obtain a definitive conclusion concerning the suitability of fibrate therapy in patients consuming Alc. Moderate alcohol consumption is probably acceptable in patients taking Gem, but further studies are required before any advice is given.

### Acknowledgements

We are grateful to Drs S. Theocharis and J. Malakos for their skilful assistance.

### References

1 Todd PA and Ward A: Gemfibrozil. A review of its pharmacodynamic and pharmacokinetic properties, and therapeutic use in dyslipidaemia. *Drugs* 36(3): 314-39, 1988.

2 Manninen V, Elo MO, Frick MH, Haapa K, Heinonen OP, Heinsalmi P, Helo P, Huttunen JK, Kaitaniemi P, Koskinen P *et al*: Lipid alterations and decline in the incidence of coronary heart disease in the Helsinki Heart Study. *JAMA* 260(5): 641-51, 1988.

3 Manninen V, Tenkanen L, Koskinen P, Huttunen JK, Manttari M, Heinonen OP and Frick MH: Joint effects of serum triglyceride and LDL cholesterol and HDL cholesterol concentrations on coronary heart disease risk in the Helsinki Heart Study. Implications for treatment. *Circulation* 85(1): 37-45, 1992.

4 Sausen PJ, Teets VJ, Voss KS, Miller RT and Cattley RC: Gemfibrozil-induced peroxisome proliferation and hepatomegaly in male F344 rats. *Cancer Lett* 97(2): 263-8, 1995.

5 Hofstra AH, King LM and Walker RM: Peroxisome proliferation and microsomal enzyme induction by the hypolipidemic CI-924 in rats and mice: relationship to tumorigenicity. *Fundam Appl Toxicol* 27: 277-286, 1995.

6 Goldberg IJ, Mosca L, Piano MR and Fisher EA: Nutrition Committee, Council on Epidemiology and Prevention, and Council on Cardiovascular Nursing of the American Heart Association. AHA Science Advisory: Wine and your heart: a science advisory for healthcare professionals from the Nutrition Committee, Council on Epidemiology and Prevention, and Council on Cardiovascular Nursing of the American Heart Association. *Circulation* 103: 472-475, 2001.

7 Orgogozo JM, Dartigues JF, Lafont S, Letenneur L, Commenges D, Salamon R, Renaud S and Breteler MB: Wine consumption and dementia in the elderly: a prospective community study in the Bordeaux area. *Rev Neurol (Paris)* 153: 185-192, 1997.

8 Ruitenberg A, van Swieten JC, Witteman JC, Mehta KM, van Duijn CM, Hofman A and Breteler MMB: Alcohol consumption and risk of dementia: The Rotterdam Study. *Lancet* 359: 281-286, 2002.

9 Mukamal KJ, Jadhav PP, D'Agostino RB, Massaro JM, Mittleman MA, Lipinska I, Sutherland PA, Matheny T, Levy D, Wilson PWF, Ellison RC, Silbershatz H, Muller JE and Tofler GH: Alcohol consumption and hemostatic factors: analysis of the Framingham Offspring Cohort. *Circulation* 104: 1367-1373, 2001.

10 Rimm EB, Klatsky A, Grobbee D and Stampfer MJ: Review of moderate alcohol consumption and reduced risk of coronary heart disease: is the effect due to beer, wine or spirits? *BMJ* 312: 731-736, 1996.

11 Feiman L and Lieber CS: Ethanol and lipid metabolism. *Am J Clin Nutr* 70: 791-792, 1999.

12 De Oliveira E Silva ER, Foster D, McGee Harper M, Seidman CE, Smith JD, Breslow JL and Brinton EA: Alcohol consumption raises HDL cholesterol levels by increasing the transport rate of apolipoproteins A-I and A-II. *Circulation* 102: 2347-2352, 2000.

13 Papadakis JA, Ganotakis ES and Mikhailidis DP: Beneficial effect of moderate alcohol consumption on vascular disease: myth or reality? *J R Soc Health* 120: 11-15, 2000.

14 Mikhailidis DP, Jeremy JY, Barradas MA, Green N and Dandona P: The effect of ethanol on vascular prostacyclin synthesis, platelet aggregation and platelet thromboxane release. *Br Med J* 287: 1495-1498, 1983.

15 Diabetes Atherosclerosis Intervention Study Investigators. Effect of fenofibrate on progression of coronary artery disease in type 2 diabetes: the Diabetes Atherosclerosis Intervention Study, a randomised study. *Lancet* 357(9260): 905-910, 2001.



- 16 Rubins HB, Robins SJ, Collins D, Fye CL, Anderson JW, Elam MB, Faas FH, Linares E, Schaefer EJ, Sechtman G, Wilt TJ and Wittes J: Gemfibrozil for the secondary prevention of coronary heart disease in men with low levels of high-density lipoprotein cholesterol. Veterans Affairs High-Density Lipoprotein Cholesterol Intervention Trial Study Group. *N Engl J Med* 341(6): 410-8, 1999.
- 17 Kolovou GD, Mikhailidis DP, Daskalova DC, Kafaltis N, Adamopoulou EN, Malakos J, Bilianou HG, Theocharis SE, Pilatis ND, Mykoniatis MG and Cokkinos DV: The effect of co-administration of simvastatin and alcohol in rats. *In Vivo* 2003 (in press).
- 18 Hermansky SJ, Neptun DA, Loughran KA and Leung HW: Effects of polyethylene glycol 400 (PEG 400) following 13 weeks of gavage treatment in Fisher-344 rats. *Fd Chem Toxic* 33(2): 139-149, 1995.
- 19 Margeli A, Theocharis S, Skaltsas S, Skopelitou A, Kittas C, Mykoniatis M and Varonos D: Effect of cadmium pretreatment on liver regeneration after partial hepatectomy in rats. *Arch Toxicol* 68: 85-90, 1994.
- 20 Margeli AP, Skaltsas SD, Spiliopoulou CA, Mykoniatis MG and Theocharis SE: Hepatic stimulator substance activity in the liver of thioacetamide-intoxicated rats. *Liver* 19: 519-525, 1999.
- 21 Theocharis SE, Margeli AP, Agapitos EV, Mykoniatis MG, Kittas CN and Davaris PS: Effect of hepatic stimulator substance administration on tissue regeneration due to thioacetamide-induced liver injury in rats. *Scand J Gastroenterol* 33: 656-663, 1998.
- 22 Nakagawa A, Shigetani A, Iwabuchi H, Horiguchi M, Nakamura K and Takahagi H: Simultaneous determination of gemfibrozil and its metabolites in plasma and urine by a fully automated high performance liquid chromatographic system. *Biomed Chromatogr* 5(2): 68-73, 1991.
- 23 Dix KJ, Coleman DP and Jeffcoat AR: Comparative metabolism and disposition of gemfibrozil in male and female Sprague-Dawley rats and Syrian golden hamsters. *Drug Metab Dispos* 27(1): 138-46, 1999.
- 24 Rubin E and Lieber CS: Alcohol-induced hepatic injury in nonalcoholic volunteers. *N Engl J Med* 278:869-876, 1968.
- 25 Lieber CS: Metabolic derangement induced by alcohol. *Ann Rev Med* 18: 35-54, 1967.
- 26 Smit JWA, Wijnne HJA, Schobben F, Sitsen A, de Bruin TWA and Erkelens DW: Effects of alcohol consumption on pharmacokinetics, efficacy, and safety of fluvastatin. *Am J Cardiol* 76: 89A-96A, 1995.
- 27 Makris TM, Davydov R, Denisov IG, Hoffman BM and Sligar SC: Mechanistic enzymology of oxygen activation by the cytochromes P450. *Drug Metab Rev* 34: 691-708, 2002.
- 28 Stickel F, Seitz HK, Hahn EC and Schuppan D: Alcoholic liver disease. *Z. Gastroenterol* 41: 333-342, 2003.
- 29 Conney AH: Pharmacological implications of microsomal enzyme induction. *Pharmacol Rev* 19: 317-366, 1967.
- 30 Sharpe PC, McBride R and Archbold GP: Biochemical markers of alcohol abuse. *QJM* 89(2): 137-144, 1996.
- 31 Kraemer KL, Mayo-Smith MF and Calkins DR: Independent clinical correlates of severe alcohol withdrawal. *Subst Abus* 24(4): 197-209, 2003.
- 32 Pispirigos K, Simopoulos K, Kouskoukis K, Kounis N and Avramopoulos A: Evaluation of kidney and liver subacute toxicity induced by Bezalip-Pravastatin-Lopid antihyperlipidaemic compounds in rats. *Biochem Mol Biol Int* 47(3): 519-28, 1999.
- 33 Wirebaugh SR, Shapiro ML, McIntyre TH and Whitney EJ: A retrospective review of the use of lipid-lowering agents in combination, specifically, gemfibrozil and lovastatin. *Pharmacotherapy* 12(6): 445-50, 1992.
- 34 Gunawardhana L, Mobley SA and Sipes IG: Modulation of 1,2-dichlorobenzene hepatotoxicity in the Fischer-344 rat by a scavenger of superoxide anions and an inhibitor of Kupffer cells. *Toxicol Appl Pharmacol* 119(2): 205-13, 1993.
- 35 Robinson SF and Quarfordt SH: The effect of ethanol on lipoprotein metabolism. *Alcohol Clin Exp Res* 5(1): 101-109, 1981.
- 36 Lieber CS and Savolainen M: Ethanol and lipids. *Alcohol Clin Exp Res* 8(4): 409-423, 1984.
- 37 Ginsberg H, Olefsky J, Farquhar JW and Reaven GM: Moderate ethanol ingestion and plasma triglyceride levels: a study in normal and hypertriglyceridemic persons. *Ann Intern Med* 80: 143-149, 1974.
- 38 MacDonald JS, Gerson RJ, Kornbrust DJ, Kloss MW, Prahalada S, Berry PH, Alberts AW and Bokelman DL: Preclinical evaluation of lovastatin. *Am J Cardiol* 62: 16J-27J, 1988.
- 39 Bosma A, Seifert WF, van Thiel-de Ruyter GC, van Leeuwen RE, Blauw B, Roholl P, Knook DL and Brouwer A: Alcohol in combination with malnutrition causes increased liver fibrosis in rats. *J Hepatol* 21: 394-402, 1994.
- 40 Gerson RJ, Mac Donald JS, Alberts AW, Kornbrust DJ, Majka JA, Stubbs RJ and Bokelman DL: Animal safety and toxicology of simvastatin and related hydroxyl-methylglutaryl-coenzyme A reductase inhibitors. *Am J Med* 87: 28S-38S, 1989.

Received November 19, 2003

Accepted December 23, 2003