

Laparoscopic Approach in Bladder Endometriosis, Intraoperative and Postoperative Outcomes

ELVIN PIRIYEV¹, SVEN SCHIERMEIER² and THOMAS RÖMER³

¹University Witten-Herdecke, Department of Obstetrics and Gynecology, Academic Hospital Cologne Weyertal University of Cologne, Cologne, Germany;

²Department of Obstetrics and Gynecology, University Witten-Herdecke, Marien-Hospital, Witten, Germany;

³Department of Obstetrics and Gynecology, Academic Hospital Cologne Weyertal University of Cologne, Cologne, Germany

Abstract. *Background/Aim:* Endometriosis is a benign condition affecting 10-20% of women at reproductive age. The urinary tract is affected in 0.3-12.0% of women with endometriosis and in 19.0-53.0% of women with deep infiltrating endometriosis. The bladder is the most commonly affected organ in the urinary tract with a prevalence of up to 80%. Bladder endometriosis is defined as the occurrence of endometrial glands and stroma in the detrusor muscle. The aim of the study was to present the detailed technique and intraoperative and postoperative outcomes of laparoscopic resection of bladder endometriosis. *Patients and Methods:* This was a retrospective study analyzing all surgical procedures, carried out at the Academic Hospital Cologne Weyertal between January 2014 and December 2022. In total 23,862 surgical reports were analyzed, and only patients (n=33 patients) with bladder endometriosis were included in the study. *Results:* Follow-up was performed in 25 patients by phone contact. Twenty-three patients (92%) reported an improvement of symptoms, especially of dysuria, and an increase of quality of life. Only two patients (8%) reported no change in symptoms (dysmenorrhea and dyspareunia). Two patients (8%) reported bladder dysfunction. Mild postoperative pollakiuria was reported by two patients (8%). Four patients (with mild bladder dysfunction and pollakiuria) were satisfied with

postoperative results owing significant improvement of symptoms and increasing the quality of life. *Conclusion:* Surgical treatment of bladder endometriosis can be performed by a gynecologist. In cases where a ureteroneocystostomy is required or the localization of endometriosis nodule is unfavorable, an intervention by a multidisciplinary team is recommended. Laparoscopic partial cystectomy and shaving seem to be an appropriate method for improving urinary symptoms. This surgical approach requires excellent laparoscopic skills.

Endometriosis is a common benign condition that affects 10-20% of women of reproductive age (1). There are three main forms of endometriosis: superficial peritoneal endometriosis, ovarian endometriosis and deep infiltrating endometriosis (DIE) (2). DIE is defined as infiltration of endometriotic lesions into the peritoneum >5 mm (3). DIE occurs in 1% of women of reproductive age and is the most severe form (2). The urinary tract is one of the most common extragenital organ systems affected by endometriosis. The prevalence ranges from 0.3-12% in all women affected by endometriosis and 19-53% in women with DIE (4-6). The bladder is the most commonly affected organ in the urinary tract with a prevalence of up to 80% of cases, followed by ureteral involvement with an occurrence of 9-23% (4, 7). Bladder endometriosis is defined as the occurrence of endometrial glands and stroma in the detrusor muscle. The most frequently affected parts of the bladder are the base and the dome (8). However, in the majority of cases, the mucosa of bladder is not affected (9). There are two theories regarding the origin of bladder endometriosis: primary or spontaneous development and secondary development. The primary development includes two theories: 1) implantation of endometrial cells due to retrograde menstruation and development of adhesions; 2) metaplasia of adenomyosis. The secondary theory explains the development of bladder endometriosis due to bladder injury after pelvic surgery (e.g.,

Correspondence to: Elvin Piriyeve, Weyertal 76, 50931 Cologne, Germany. Tel: +49 2214795300, Fax: +49 2214795304, e-mail: piriyeve.elvins@gmail.com

Key Words: Endometriosis, bladder endometriosis, laparoscopy, cystectomy, bladder shaving.



This article is an open access article distributed under the terms and conditions of the Creative Commons Attribution (CC BY-NC-ND) 4.0 international license (<https://creativecommons.org/licenses/by-nc-nd/4.0>).

caesarean section, hysterectomy etc.) and following a contamination of endometrial cells (8). The symptoms caused by bladder endometriosis include suprapubic pain accompanied by polyuria (41%), dysuria (21%), hematuria (19%), as well as repeated urinary tract infections (10). Bladder endometriosis is classified by the ENZIAN/#ENZIAN classification as “FB” (11). For the treatment of bladder endometriosis, several options, such as a hormonal therapy and surgery [laparoscopic/laparotomic partial bladder resection, “shaving” and transurethral resection (TUR)] are suggested (12). The aim of the study was to present the intraoperative and postoperative outcomes of laparoscopic management for bladder endometriosis.

Patients and Methods

This was a retrospective study that analyzed all surgeries, that were carried out at the Academic Hospital Cologne Weyertal between January 2014 and December 2022. Academic Hospital Cologne Weyertal is a level III endometriosis Center where 750-1,000 laparoscopic endometriosis surgeries are performed annually. In total 23,862 surgical reports were analyzed. In this study only patients (n=33) with bladder endometriosis were included. Preoperative assessment was performed by vaginal sonography. To assess the bladder mucosa, as well as the distance between the endometriosis nodule and the ureteral orifices, a cystoscopy was performed in all cases. Histological confirmation of the resected endometriosis nodules was mandatory. It was investigated in which cases a urological intervention was necessary. The surgical approach was divided into shaving and partial cystectomy. The follow-up was performed by phone contact. The patients were asked regarding improvement of symptoms, postoperative bladder dysfunction, as well as re-intervention. The size of endometriosis nodule was evaluated using the histological examination report. To classify peritoneal and ovarian endometriosis, the rASRM classification was used, and ENZIAN was used to classify DIE lesions.

Procedure. All surgeries were performed by experienced certificated laparoscopic surgeons [minimal invasive surgery (MIS) level II and III, certificated by the German society for gynecological endoscopy]. We divided the bladder endometriosis surgical procedure into sequential steps. The first step was the cystoscopy for evaluating the mucosa and ureteral orifices (Figure 1A and B). The second step was laparoscopic visualization. During the laparoscopy adenomyosis, adhesions and endometriosis in other localization were evaluated (Figure 2A and B). Step three: Complete adhesiolysis in case of any adhesions between the bladder and the uterus, as well as round ligament of the uterus, which enables a sufficient resection of endometriosis nodule.

The fourth step was resection of the endometriosis nodule. For this reason, either partial cystectomy or shaving can be used (Figure 3A and B). We defined shaving as the resection of the bladder layer without involvement of mucosa.

After successful endometriosis resection, the distance between ureters/ ureteral orifices and the resection edge should be evaluated (Figure 4): step five. The final step, step six, was the suture (Figure 5). Postoperatively all patients retained a bladder catheter for 10 days.

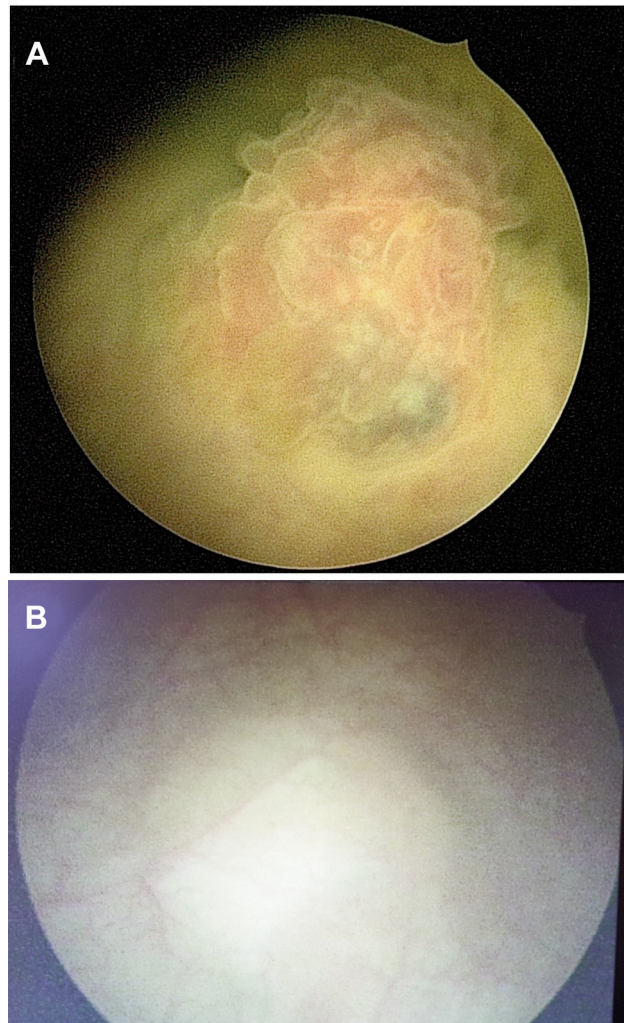


Figure 1. Cystoscopy for the determination of the endometriosis nodule and distance between nodule and ureteral orifices. (A) Active endometriosis, the entire bladder wall is affected by endometriosis. (B) Protrusion of mucosa by the endometriosis nodule without infiltration of mucosa.

Results

Patient characteristics. Thirty-three patients with bladder endometriosis, who underwent a laparoscopy, were included in this retrospective analysis. The age ranged from 25 to 48 years. All patients were symptomatic. The majority of patients had symptoms, such as dysmenorrhea and dysuria. Dyschezia and dyspareunia were less common. Only two patients had hematuria. Twelve patients had symptoms despite hormonal therapy. 23 patients had previous surgery, whereby 16 patients had one surgery and seven patients ≥ 2 surgeries. The main patient characteristics are presented in Table I.

Intraoperative outcomes. A cystoscopy for evaluating affected mucosa and the distance between the endometriosis

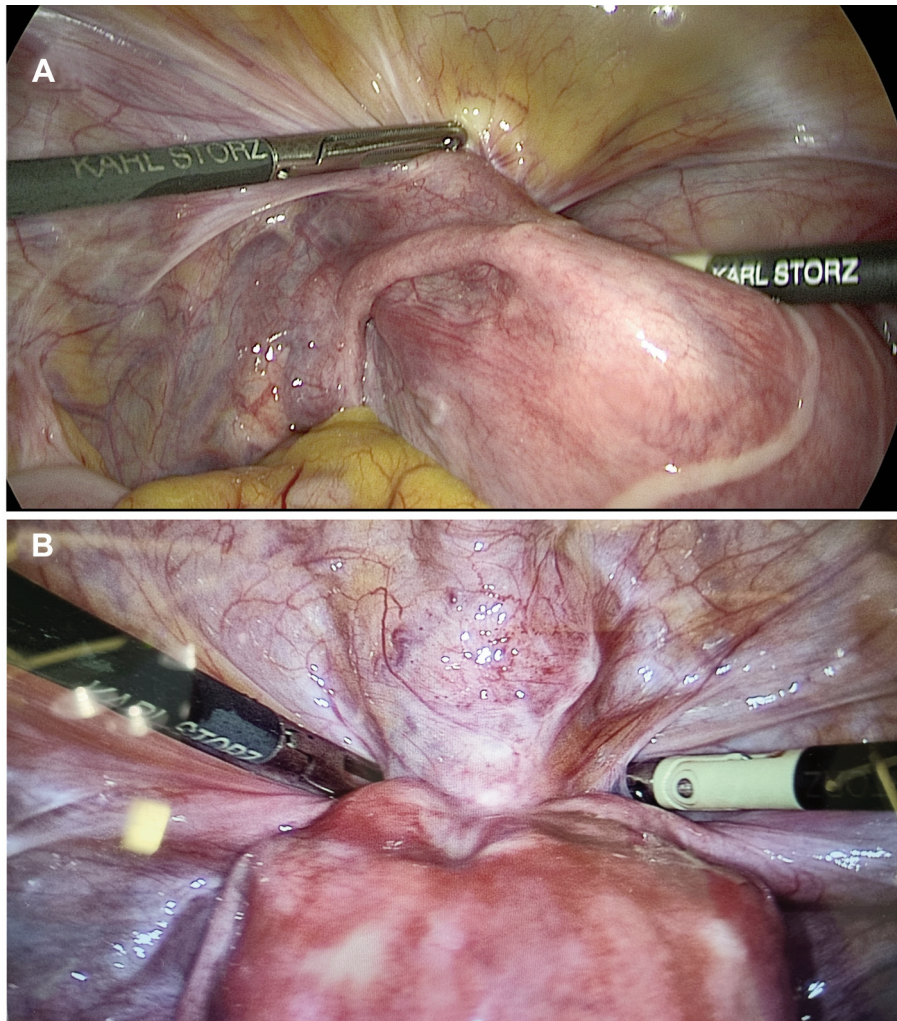


Figure 2. Laparoscopic visualization of the bladder endometriosis nodule. (A) Adhesion between the bladder, uterus, and the left round ligament of the uterus, (B) severe adenomyosis with bladder endometriosis.

nodule and “golden triangle” was performed. In the majority of cases, the endometriosis nodule bulged into or infiltrated the mucosa. The size of the endometriosis nodule ranged from 1 to 4.5 cm and was verified according to histopathological reports. The majority of patients had a nodule of 2-4 cm. Adenomyosis, adhesions and other endometriosis locations were determined by laparoscopy. The resection of bladder endometriosis took place in thirty cases. In 3 cases, patients did not require bladder surgery. However, these three cases were included, in order to evaluate other statistical data (symptoms, adhesions, other endometriosis *etc.*). Partial cystectomy was the procedure most commonly used in contrast to “shaving”, which was performed only in a few cases. A urologist involvement was necessary in three cases, whereby in two cases a ureteroneocystostomy was performed. For the bladder suture

Vicryl, V-Loc as well as polydioxanone suture (PDS) thread were used. The main intraoperative outcomes are presented in Table II and Figure 6.

Postoperative outcomes. In three out of 23 cases after partial cystectomy, postoperative bleeding occurred. Two of the patients had a 4-cm nodule and one patient a 2-cm nodule. In two cases a re-laparoscopy was necessary and in one case the bleeding stopped spontaneously. One patient had ureteral stenosis after partial cystectomy with a 3.5 cm endometriosis nodule, therefore a urological reintervention was necessary. No complications after shaving were observed.

Follow-up was performed in 25 patients by phone contact. Twenty-three patients (92%) reported an improvement of symptoms, especially of dysuria, and increase of quality of life. Only two patients (8%) reported no change in symptoms

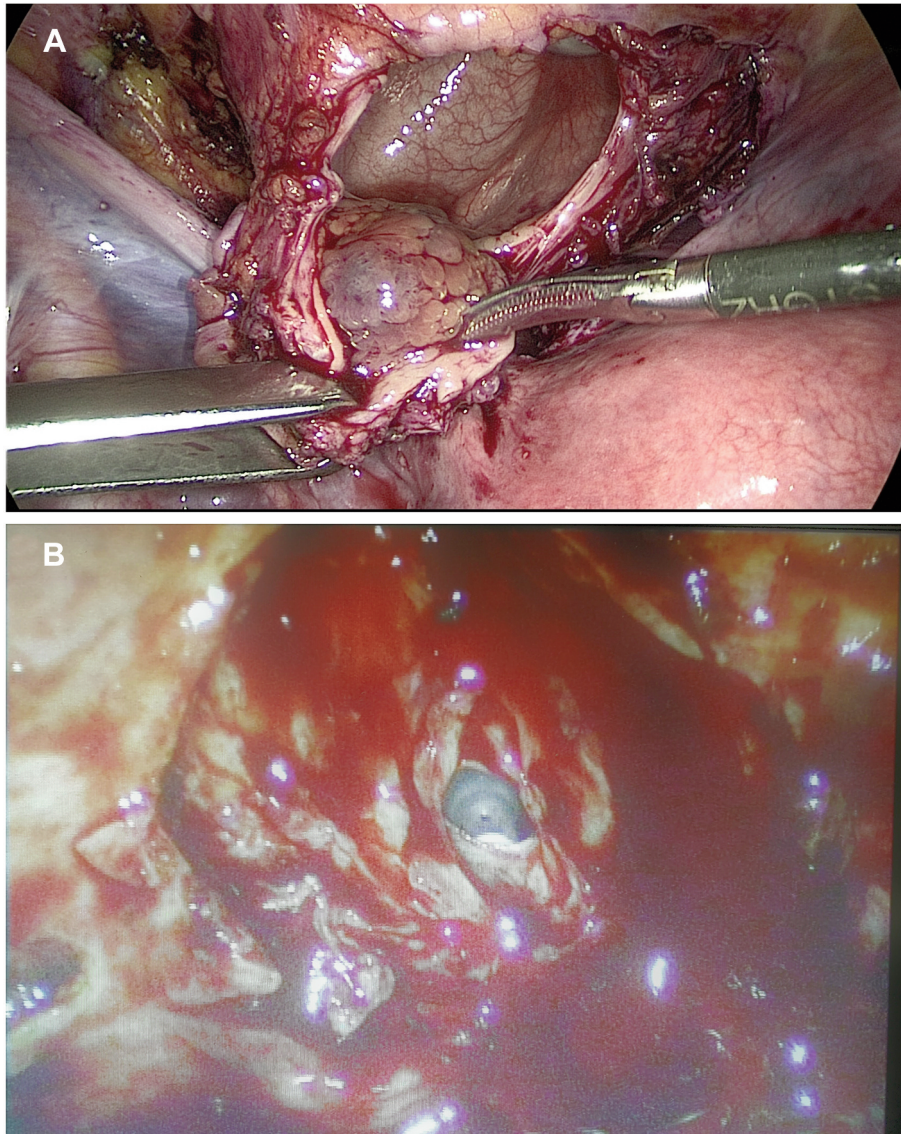


Figure 3. *Laparoscopic resection of bladder endometriosis. (A) Laparoscopic partial cystectomy, (B) laparoscopic bladder shaving.*

(dysmenorrhea and dyspareunia). Two patients (8%) reported bladder dysfunction. However, in one case, the patient reported mild bladder dysfunction and it did not affect her quality of life. In another case, the patient had had the bladder dysfunction already before the surgery and it did not increase after surgery. Mild postoperative pollakiuria was reported by two patients (8%). Four patients (with mild bladder dysfunction and pollakiuria) were satisfied with postoperative results owing significant improvement of symptoms and increasing the quality of life. No patient underwent reintervention because of endometriosis recurrence until follow-up.

Discussion

Bladder endometriosis is a rare condition, but it should be taken into account in patients with bladder symptoms and in the absence of urine infection (10). There are certain theories about the origin of bladder endometriosis. Some authors attribute the origin to retrograde menstrual bleeding and implantation of endometrial cells on the bladder peritoneum. After implantation, the inflammatory process facilitates the development of adhesions between the bladder and the uterus, and the formation of a fibrotic nodule, apparently of the vesicovaginal septum, that is buried under the peritoneum

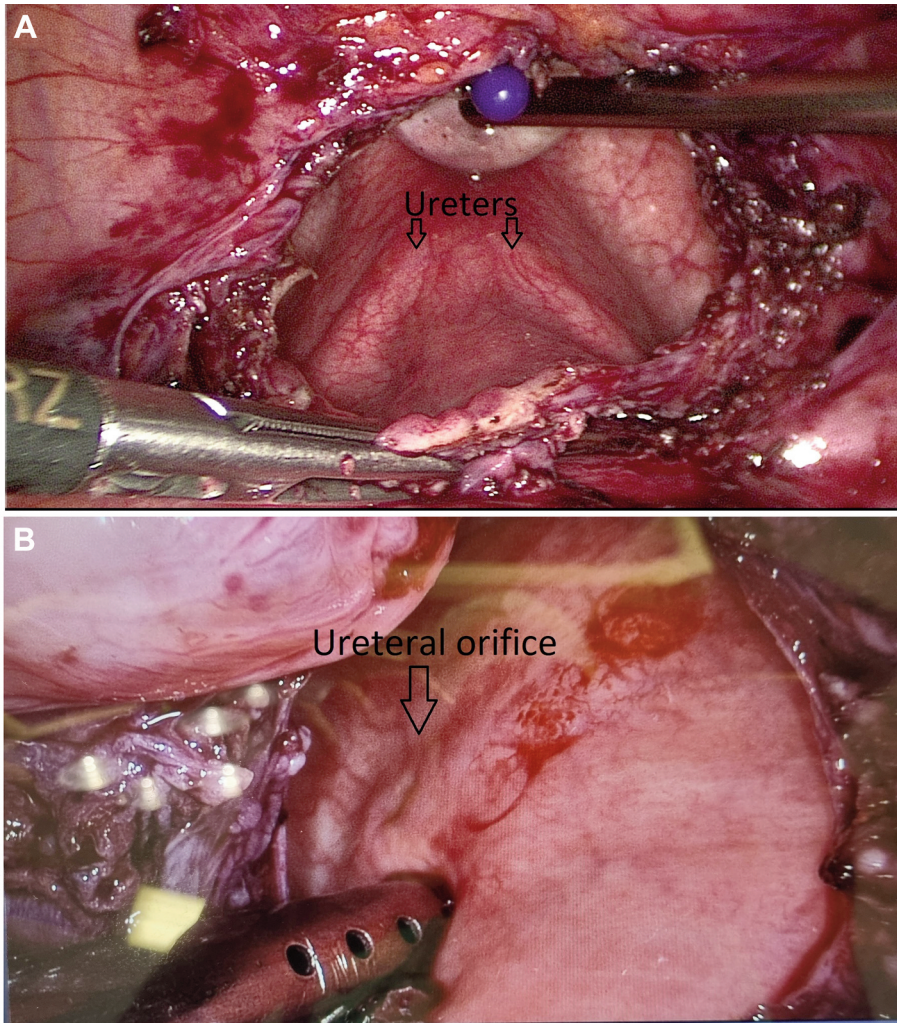


Figure 4. *Laparoscopic visualization of ureters (A) and ureteral orifices (B).*

(10, 13). Another theory is that the lesions are an extension of adenomyotic lesions arising from the myometrium (14, 15). The occurrence of adenomyosis, and adhesions between the bladder and uterus, in our case series, confirm these theories (Table II).

Bladder endometriosis can be treated both with hormonal therapy and surgery. For medical therapy, combined hormonal contraceptives and progestogens should be regarded as first-line therapy (16-18). However, it has been reported, that the bladder endometriosis nodule itself and associated symptoms may respond suboptimally to hormone therapy (19). The data of our case series are in line with this conclusion (Table I). Furthermore, the medical therapy is effective in temporarily suppressing, but not curing of bladder endometriosis. If hormone therapy is chosen, patients should be informed about long-term treatment and

that bladder endometriosis may progress under therapy, so a regular control is advisable (12, 17). For this reason, surgery may be required. For surgery, an accurate diagnosis using ultrasound and cystoscopy is mandatory. Depending on the size and location, an interdisciplinary procedure with a urologist may be required. The goal should be complete resection of the endometriosis nodule, which on the one hand facilitates significant improvements in pain and urinary symptoms and on the other minimizes the recurrence risk (20-25). Certain techniques are suggested for surgical treatment: transurethral resection (TUR), partial resection, as well as shaving (12, 26). However, there exist concerns about TUR. A complete resection with TUR is unachievable, since the nodule develops from the outer layer towards to the inner layer of the bladder wall. Furthermore, the data of this study show that an

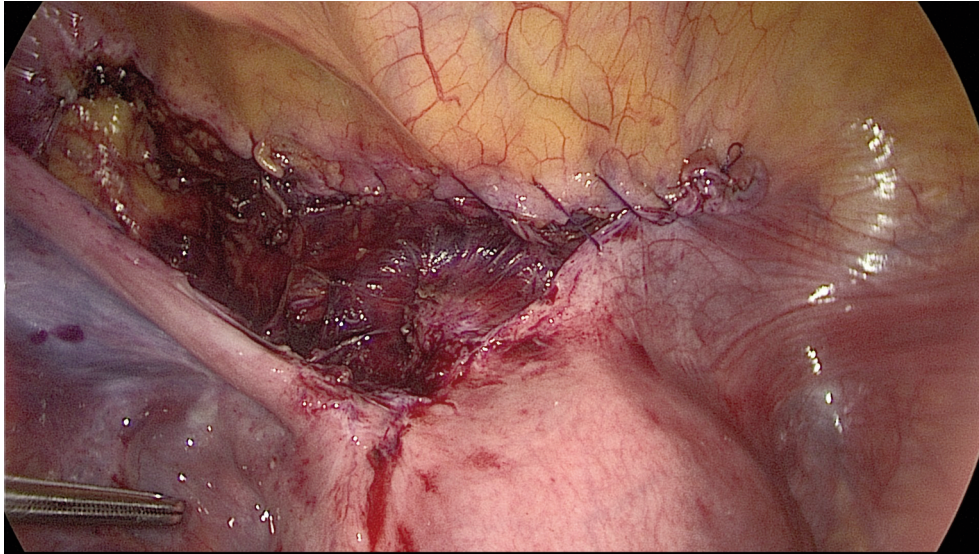


Figure 5. Suture of bladder incision after resection of the endometriosis nodule.

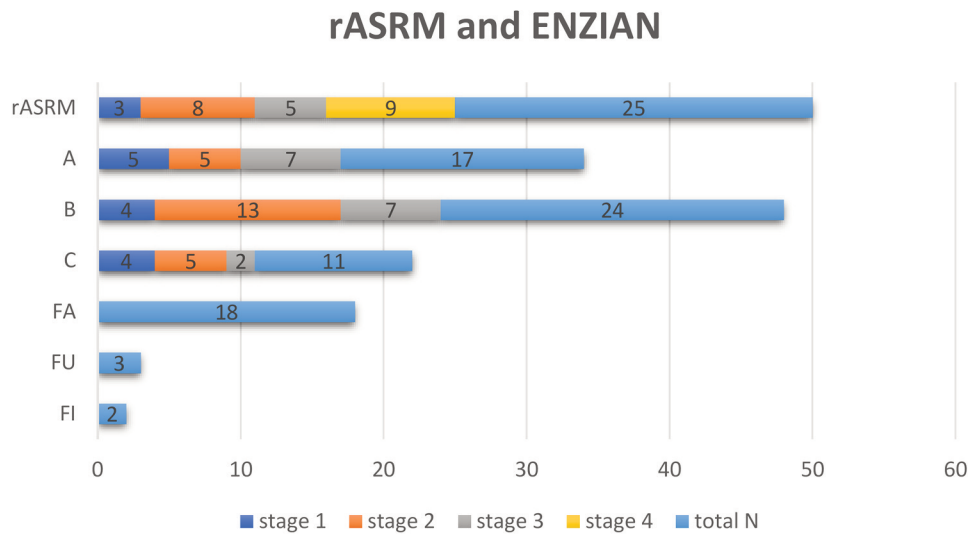


Figure 6. Number of patients according to rASRM and ENZIAN classification. rASRM, Revised American Society of Reproductive Medicine, classification of endometriosis; ENZIAN, classification of deep infiltrating endometriosis.

endometriosis nodule is not always detectable with cystoscopy (Table II). TUR has a high risk of bladder perforation and a recurrence of endometriosis (25, 27-29). For this reason, TUR cannot be considered as an efficient treatment of bladder endometriosis (12). In contrast, many authors reported that a partial cystectomy is an effective method with excellent long-term results in terms of symptom relief and recurrence (12).

In our case series, partial cystectomy was performed in 23 cases. The average nodule size was 2.5 cm. Many authors stated that partial cystectomy can be performed by a gynecologist if the distance between the endometriosis nodule and ureteral orifices is at least 2 cm (30). The authors of this study agree with this statement. In our study, in three cases the involvement of a urologist was necessary. However, in two cases, patients had ureter obliteration caused by

Table I. Patient characteristics.

	N
Total patients	33
Age (mean±SD)	35.03±6.31
BMI kg/m ² (mean±SD)	23.69±5.46
Symptoms	
Dysmenorrhea	28 patients (85%)
Dysuria	23 patients (70%)
Dyspareunia	14 patients (42%)
Dyschezia	7 patients (21%)
Low abdominal pain	4 patients (12%)
Hematuria	2 patients (6%)
Harmon therapy	12 patients (35%)
Dienogest 2 mg	5 patients (15%)
Dienogest 2 mg/ Ethinylestradiol 0.03 mg	5 Patients (15%)
Desogestrel 0.075 mg	1 patient (3%)
Levonorgestrel 0.15 mg/ 0.03 mg Ethinylestradiol	1 patient (3%)
Birth in history	6 patients (18%)
Caesarean section	2 patients (6%)
Vaginal delivery	4 patients (12%)
Previous surgery in history	23 patients (70%)
# of Laparoscopies per patient	20 patients (61%)
1× Laparoscopy	15 patient (45%)
2× Laparoscopies	3 patients (9%)
≥3× Laparoscopies	2 patients (6%)
Type of laparoscopy	
Endometriosis laparoscopy	16 patients (48%) - 20 laparoscopies
Appendectomy	3 patients (9%)
Hysterectomy	2 patients (6%)
Ovarian cystectomy	1 patient (3%) - 3 laparoscopies
Laparoscopy by ectopic pregnancy	1 patient (3%)
Other surgery	
Caesarean section	2 patients (6%)
Uterus curettage	2 patients (6%) - 3 curettages

BMI: Body mass index.

endometriosis and a ureteroneocystostomy was planned. In one case, the distance between nodule and ureteral orifices was less than 2cm.

Inserting D-J stents is optional for primary surgery of bladder endometriosis (12). We could not find any publication, showing an advantage of D-J stents in surgery of DIE. However, two studies reported no difference in terms of ureter injury in patients with and without D-J stents, who had undergone surgery for DIE. The risk of bladder infection, on other hand, is significantly higher in patients with D-J stents (31, 32).

Rich bladder vascularization and sterile content enable a good healing process after partial cystectomy. Another important point, which should be taken into account, is prolonged urine drainage (~10 d) (33). However, rich bladder vascularization can increase the risk of bleeding. Three out of 30 patients in our case series had postoperative bleeding.

Table II. Intraoperative outcomes

	N
Total number	33 patients (100%)
Bladder resection	30 patients (91%)
Partial cystectomy	23 patients (70%)
Shaving	7 patients (21%)
No resection	3 patients (9%)
Size of endometriosis nodule cm	
Average (mean±SD)	2.5±1
<2 cm	8 patients (24%)
2-4 cm	21 patients (64%)
>4 cm	1 patient (3%)
n.r.	3 patients (9%)
D-J stent	15 patients (45%)
Thread	26 patients (79%)
Vicryl (polyglactin)	18 patients (55%)
Barbed (V-Loc)	5 patients (15%)
PDS	3 patients (9%)
Adenomyose	18 patients (55%)
Adhesion uterus/bladder	24 patients (73%)
Cystoscopy	
Detected	22 patients (67%)
Not detected	11 patients (33%)
Involvement of urologist	3 patients (9%)
Ureteroneocystostomy	2 patients (6%)
Close to "gold triangle"	1 patient (3%)

n.r.: Not resected; D-J stent: double J stent; PDS: polydioxanone suture.

In two cases, a re-laparoscopy was necessary. In one case, the bleeding stopped spontaneously, and a bladder tamponade was treated using an irrigation catheter.

Shaving is defined as an extramucosal dissection of the bladder wall. Many authors reported good results after shaving in terms of improvement of symptoms and safety of the method (9, 34-36). In our case series, seven patients underwent shaving. In all cases the cystoscopy showed no mucosa infiltration. In three cases bladder suture after deep shaving was carried out, in order to prevent a fistula. There were neither intraoperative, nor postoperative complications.

In our case series, only resorbable thread was used (Table II). In 55% of cases polyglactin thread, in 15% barbed and in 9% PDS was used for bladder suture. No difference in suture time, postoperative complication in terms of bleeding and bladder dysfunction, as well as improvement of symptoms were observed in our analysis. The above thread materials have been used/suggested by several authors (26, 37). Follow-up revealed improvement of symptoms in 92% of cases.

The risk of endometriosis-associated malignancies of the urinary tract is very low. Only a few cases of endometriosis-associated malignancies in the urinary tract have been reported in the literature, and most of these involved the bladder (38).

Conclusion

This analysis showed that surgical treatment of bladder endometriosis can be performed by a gynecologist. In cases where a ureteroneocystostomy is required or the localization of endometriosis nodule is unfavorable, an intervention by multidisciplinary team, including a gynecologist and a urologist, is recommended. Laparoscopic partial cystectomy and shaving seem to be an appropriate method for improving urinary symptoms, with a low rate of intra- and postoperative complications even in patients with large endometriosis nodules. However, such complications as bleeding, pollakiuria, bladder dysfunction as well as incomplete healing of the bladder or suture leakage can occur and should be taken into account. This surgical approach requires excellent laparoscopic skills.

Conflicts of Interest

The Authors have no conflicts of interest regarding this study.

Authors' Contributions

EP: Manuscript writing, data management, data analysis. SS and TR: project development and administration.

References

- Vessey MP, Villard-Mackintosh L and Painter R: Epidemiology of endometriosis in women attending family planning clinics. *BMJ* 306(6871): 182-184, 1993. PMID: 8338516. DOI: 10.1136/bmj.306.6871.182
- Koninckx PR, Ussia A, Adamyan L, Wattiez A and Donnez J: Deep endometriosis: definition, diagnosis, and treatment. *Fertil Steril* 98(3): 564-571, 2012. PMID: 22938769. DOI: 10.1016/j.fertnstert.2012.07.1061
- Koninckx PR and Martin DC: Deep endometriosis: a consequence of infiltration or retraction or possibly adenomyosis externa? *Fertil Steril* 58(5): 924-928, 1992. PMID: 1426377. DOI: 10.1016/s0015-0282(16)55436-3
- Maccagnano C, Pellucchi F, Rocchini L, Ghezzi M, Scattoni V, Montorsi F, Rigatti P and Colombo R: Ureteral endometriosis: proposal for a diagnostic and therapeutic algorithm with a review of the literature. *Urol Int* 91(1): 1-9, 2013. PMID: 23689345. DOI: 10.1159/000345140
- Kołodziej A, Krajewski W, Dołowy Ł and Hirmler L: Urinary Tract Endometriosis. *Urol J* 12(4): 2213-2217, 2015. PMID: 26341760.
- Knabben L, Imboden S, Fellmann B, Nirgianakis K, Kuhn A and Mueller MD: Urinary tract endometriosis in patients with deep infiltrating endometriosis: prevalence, symptoms, management, and proposal for a new clinical classification. *Fertil Steril* 103(1): 147-152, 2015. PMID: 25439849. DOI: 10.1016/j.fertnstert.2014.09.028
- Gabriel B, Nassif J, Trompoukis P, Barata S and Wattiez A: Prevalence and management of urinary tract endometriosis: a clinical case series. *Urology* 78(6): 1269-1274, 2011. PMID: 21962747. DOI: 10.1016/j.urology.2011.07.1403
- Somigliana E, Vercellini P, Gattei U, Chopin N, Chiodo I and Chapron C: Bladder endometriosis: getting closer and closer to the unifying metastatic hypothesis. *Fertil Steril* 87(6): 1287-1290, 2007. PMID: 17336966. DOI: 10.1016/j.fertnstert.2006.11.090
- Kovoor E, Nassif J, Miranda-Mendoza I and Wattiez A: Endometriosis of bladder: outcomes after laparoscopic surgery. *J Minim Invasive Gynecol* 17(5): 600-604, 2010. PMID: 20656568. DOI: 10.1016/j.jmig.2010.05.008
- Vercellini P, Meschia M, De Giorgi O, Panazza S, Cortesi I and Crosignani PG: Bladder detrusor endometriosis: clinical and pathogenetic implications. *J Urol* 155(1): 84-86, 1996. PMID: 7490905. DOI: 10.1016/s0022-5347(01)66550-9
- Keckstein J, Saridogan E, Ulrich UA, Sillem M, Oppelt P, Schweppe KW, Krentel H, Janschek E, Exacoustos C, Malzoni M, Mueller M, Roman H, Condous G, Forman A, Jansen FW, Bokor A, Sirmedrea V and Hudelist G: The #Enzian classification: A comprehensive non-invasive and surgical description system for endometriosis. *Acta Obstet Gynecol Scand* 100(7): 1165-1175, 2021. PMID: 33483970. DOI: 10.1111/aogs.14099
- Leone Roberti Maggiore U, Ferrero S, Candiani M, Somigliana E, Viganò P and Vercellini P: Bladder endometriosis: a systematic review of pathogenesis, diagnosis, treatment, impact on fertility, and risk of malignant transformation. *Eur Urol* 71(5): 790-807, 2017. PMID: 28040358. DOI: 10.1016/j.eururo.2016.12.015
- Vercellini P, Frontino G, Pisacreta A, De Giorgi O, Cattaneo M and Crosignani PG: The pathogenesis of bladder detrusor endometriosis. *Am J Obstet Gynecol* 187(3): 538-542, 2002. PMID: 12237623. DOI: 10.1067/mob.2002.124286
- Fedele L, Piazzola E, Raffaelli R and Bianchi S: Bladder endometriosis: deep infiltrating endometriosis or adenomyosis? *Fertil Steril* 69(5): 972-975, 1998. PMID: 9591511. DOI: 10.1016/s0015-0282(98)00048-x
- Donnez J, Spada F, Squifflet J and Nisolle M: Bladder endometriosis must be considered as bladder adenomyosis. *Fertil Steril* 74(6): 1175-1181, 2000. PMID: 11119746. DOI: 10.1016/s0015-0282(00)01584-3
- Tafi E, Leone Roberti Maggiore U, Alessandri F, Bogliolo S, Gardella B, Vellone VG, Grillo F, Mastracci L and Ferrero S: Advances in pharmacotherapy for treating endometriosis. *Expert Opin Pharmacother* 16(16): 2465-2483, 2015. PMID: 26569155. DOI: 10.1517/14656566.2015.1085510
- Ferrero S, Alessandri F, Racca A and Leone Roberti Maggiore U: Treatment of pain associated with deep endometriosis: alternatives and evidence. *Fertil Steril* 104(4): 771-792, 2015. PMID: 26363387. DOI: 10.1016/j.fertnstert.2015.08.031
- Vercellini P, Buggio L, Berlanda N, Barbara G, Somigliana E and Bosari S: Estrogen-progestins and progestins for the management of endometriosis. *Fertil Steril* 106(7): 1552-1571.e2, 2016. PMID: 27817837. DOI: 10.1016/j.fertnstert.2016.10.022
- Maccagnano C, Pellucchi F, Rocchini L, Ghezzi M, Scattoni V, Montorsi F, Rigatti P and Colombo R: Diagnosis and treatment of bladder endometriosis: state of the art. *Urol Int* 89(3): 249-258, 2012. PMID: 22813980. DOI: 10.1159/000339519
- Nezhat CR, Nezhat F, Admon D, Seidman D and Nezhat CH: Laparoscopic Management of Genitourinary Endometriosis. *J Am Assoc Gynecol Laparosc* 1(4, Part 2): S25, 1994. PMID: 9073728.
- Chapron C and Dubuisson JB: Laparoscopic management of bladder endometriosis. *Acta Obstet Gynecol Scand* 78(10): 887-890, 1999. PMID: 10577619.

- 22 Seracchioli R, Mabrouk M, Montanari G, Manuzzi L, Concetti S and Venturoli S: Conservative laparoscopic management of urinary tract endometriosis (UTE): surgical outcome and long-term follow-up. *Fertil Steril* 94(3): 856-861, 2010. PMID: 19481740. DOI: 10.1016/j.fertnstert.2009.04.019
- 23 Chapron C, Bourret A, Chopin N, Dousset B, Leconte M, Amsellem-Ouazana D, de Ziegler D and Borghese B: Surgery for bladder endometriosis: long-term results and concomitant management of associated posterior deep lesions. *Hum Reprod* 25(4): 884-889, 2010. PMID: 20129993. DOI: 10.1093/humrep/deq017
- 24 Soriano D, Bouaziz J, Elizur S, Zolti M, Orvieto R, Seidman D, Goldenberg M and Eisenberg VH: Reproductive outcome is favorable after laparoscopic resection of bladder endometriosis. *J Minim Invasive Gynecol* 23(5): 781-786, 2016. PMID: 27016123. DOI: 10.1016/j.jmig.2016.03.015
- 25 Pérez-Utrilla Pérez M, Aguilera Bazán A, Alonso Dorrego JM, Hernández A, de Francisco MG, Martín Hernández M, de Santiago J and de la Peña Barthel J: Urinary tract endometriosis: clinical, diagnostic, and therapeutic aspects. *Urology* 73(1): 47-51, 2009. PMID: 18950841. DOI: 10.1016/j.urology.2008.08.470
- 26 Tomasi MC, Ribeiro PAA, Farah D, Vidoto Cervantes G, Nicola AL and Abdalla-Ribeiro HS: Symptoms and surgical technique of bladder endometriosis: a systematic review. *J Minim Invasive Gynecol* 29(12): 1294-1302, 2022. PMID: 36252916. DOI: 10.1016/j.jmig.2022.10.003
- 27 Fedele L, Bianchi S, Zanconato G, Bergamini V, Berlanda N and Carmignani L: Long-term follow-up after conservative surgery for bladder endometriosis. *Fertil Steril* 83(6): 1729-1733, 2005. PMID: 15950643. DOI: 10.1016/j.fertnstert.2004.12.047
- 28 Antonelli A, Simeone C, Zani D, Sacconi T, Minini G, Canossi E and Cunico SC: Clinical aspects and surgical treatment of urinary tract endometriosis: our experience with 31 cases. *Eur Urol* 49(6): 1093-7; discussion 1097-8, 2006. PMID: 16630689. DOI: 10.1016/j.eururo.2006.03.037
- 29 Fuentes Pastor J, Ballesteros Diego R, Correas Gómez MÁ, Torres Díez E, Fernández Flórez A, Ballesteros Olmos G and Gutierrez Baños JL: Bladder endometriosis and endocervicosis: presentation of 2 cases with endoscopic management and review of literature. *Case Rep Urol* 2014: 296908, 2014. PMID: 25184072. DOI: 10.1155/2014/296908
- 30 Vercellini P, Pisacreta A, De Giorgi O, Yaylayan L, Zaina B and Crosignani PG: Management of advanced endometriosis. In: *Fertility and reproductive medicine*. Kempers RD, Cohen J, Haney AF, Younger JB (eds). Amsterdam, the Netherlands, Elsevier Science, pp. 369-386, 1998.
- 31 Borghese G, Raimondo D, Esposti ED, Aru AC, Raffone A, Orsini B, Ambrosio M, Iodice R, Lenzi J, Del Forno S, Casadio P and Seracchioli R: Preoperative ureteral stenting in women with deep posterior endometriosis and ureteral involvement: Is it useful? *Int J Gynaecol Obstet* 158(1): 179-186, 2022. PMID: 34606100. DOI: 10.1002/ijgo.13959
- 32 Piriye E, Schiermeier S and Römer T: Are double-J stents in surgery for deep infiltrating endometriosis always necessary? A retrospective analysis. *Wideochir Inne Tech Maloinwazyjne* 17(3): 533-539, 2022. PMID: 36187054. DOI: 10.5114/wiitm.2022.116325
- 33 Vercellini P, Carmignani L, Rubino T, Barbara G, Abbiati A and Fedele L: Surgery for deep endometriosis: a pathogenesis-oriented approach. *Gynecol Obstet Invest* 68(2): 88-103, 2009. PMID: 19478525. DOI: 10.1159/000219946
- 34 Granese R, Candiani M, Perino A, Venezia R and Cucinella G: Bladder endometriosis: laparoscopic treatment and follow-up. *Eur J Obstet Gynecol Reprod Biol* 140(1): 114-117, 2008. PMID: 18462860. DOI: 10.1016/j.ejogrb.2008.03.011
- 35 Gonçalves DR, Galvão A, Moreira M, Morgado A, Ramos M and Ferreira H: Endometriosis of the bladder: Clinical and surgical outcomes after laparoscopic surgery. *Surg Technol Int* 34: 275-281, 2019. PMID: 30888677.
- 36 Villa G, Mabrouk M, Guerrini M, Mignemi G, Montanari G, Fabbri E, Venturoli S and Seracchioli R: Relationship between site and size of bladder endometriotic nodules and severity of dysuria. *J Minim Invasive Gynecol* 14(5): 628-632, 2007. PMID: 17848326. DOI: 10.1016/j.jmig.2007.04.015
- 37 Chamsy D, King C and Lee T: The use of barbed suture for bladder and bowel repair. *J Minim Invasive Gynecol* 22(4): 648-652, 2015. PMID: 25659867. DOI: 10.1016/j.jmig.2015.01.030
- 38 Gadducci A and Zannoni GF: Endometriosis-associated extraovarian malignancies: a challenging question for the clinician and the pathologist. *Anticancer Res* 40(5): 2429-2438, 2020. PMID: 32366386. DOI: 10.21873/anticancer.14212

Received November 30, 2022

Revised December 10, 2022

Accepted December 16, 2022