in vivo *35*: 239-248 (2021)
doi:10.21873/invivo.12252

Tumor Growth Suppression With Novel Intra-arterial Chemotherapy Using Epirubicin-entrapped Water-in-oil-in-water Emulsion *In Vivo*

HIRONOBU YANAGIE[1,2,3], TAKASHI FUJINO[4], MASASHI YANAGAWA[5], TOSHIMITSU TERAO[6], TAKASHI IMAGAWA[7], MITSUTERU FUJIHARA[8], YASUYUKI MORISHITA[9], RYOUJI MIZUMACHI[10], YUUJI MURATA[10], NOVRIANA DEWI[11], YUUYA ONO[8], ICHIRO IKUSHIMA[12,13], KOJI SEGUCHI[14], MASASHI NAGATA[15], YASUMASA NONAKA[16], YOSHITAKA FURUYA[17], TOMOYUKI HISA[18], TAKESHI NAGASAKI[19], KAZUHIKO ARIMORI[20], TADAO NAKASHIMA[13], TAKUMICHI SUGIHARA[11], KAZUHIRO KAKIMI[21], MINORU ONO[2,22], JUN NAKAJIMA[2,23], MASAZUMI ERIGUCHI[24], SHUSHI HIGASHI[13,14] and HIROYUKI TAKAHASHI[1,2]

[1]*Institute of Engineering Innovation, School of Engineering, The University of Tokyo, Tokyo, Japan;*
[2]*Cooperative Unit of Medicine and Engineering, The University of Tokyo Hospital, Tokyo, Japan;*
[3]*Research Institute of Healthy Living, Niigata University of Pharmacy and Applied Life Sciences, Niigata, Japan;*
[4]*Department of Pathology, Saitama Medical University International Medical Center, Hidaka, Japan;*
[5]*Veterinary Medical Center, Obihiro University of Agriculture and Veterinary Medicine, Hokkaido, Japan;*
[6]*Department of Pharmaceutical Technology, Otsuka Pharmaceutical Factory, Tokushima, Japan;*
[7]*Department of Chemical Science and Engineering, Graduate School of Engineering, Kobe University, Hyogo, Japan;*
[8]*SPG Techno Ltd. Co., Miyazaki Techno Research Park, Miyazaki, Japan;*
[9]*Department of Human and Molecular Pathology, Graduate School of Medicine, The University of Tokyo, Tokyo, Japan;*
[10]*Department of Pharmacology, Kumamoto Institute Branch, LSI Medience Ltd. Co., Kumamoto, Japan;*
[11]*Laboratory of Pharmaceutical Chemistry, Faculty of Pharmaceutical Sciences, Niigata University of Pharmacy and Applied Life Sciences, Niigata, Japan;*
[12]*Department of Radiology, Miyakonojo Shigun Ishikai Hospital, Miyazaki, Japan;*
[13]*Kyushu Medical Resource Foundation, Miyazaki, Japan;*
[14]*Department of Surgery, Kojin-kai Medical City East Hospital, Miyazaki, Japan;*
[15]*Department of Pharmacy, Medical Hospital, Tokyo Medical and Dental University, Tokyo, Japan;*
[16]*Department of Surgery, Keiai-kai Houyou Hospital, Iwate, Japan;*
[17]*Department of Surgery, Sodegaura Satukidai Hospital, Chiba, Japan;*
[18]*Tokyo Bunkyo Study Center, The Open University of Japan, Tokyo, Japan;*
[19]*Department of Bioengineering, Osaka City University Graduate school of Engineering, Osaka, Japan;*
[20]*Department of Pharmacy, Miyazaki Medical University Hospital, Miyazaki, Japan;*
[21]*Department of Immunotherapeutics,* [22]*Department of Cardiovascular Surgery, and*
[23]*Department of Thoracic Surgery, The University of Tokyo Hospital, Tokyo, Japan;*
[24]*Department of Surgery, Shin-Yamanote Hospital, Japan Anti-Tuberculosis Association, Tokyo, Japan*

This article is freely accessible online.

Correspondence to: Hironobu Yanagie, MD, Ph.D., Institute of Engineering Innovation, School of Engineering, The University of Tokyo, 2-11-16 Yayoi, Bunkyo-ku, Tokyo 113-8656, Japan. Tel: +81 358009194, Fax: +81 358009195, e-mail: h.yanagie@gmail.com

Key Words: Water-in-oil-in-water emulsion, hepatocellular carcinoma, intra-arterial chemotherapy, epirubicin.

Abstract. *Background/Aim: A mixture of anticancer agents and iodized poppy seed oil (IPSO) has been widely used for intra-arterial chemotherapy of hepatocellular carcinoma. However, the anticancer agents can easily separate from IPSO, so the therapeutic potential is limited. We developed epirubicin-entrapped water-in-oil-in-water emulsion (WOW-Epi) using a double-membrane emulsification technique. Materials and Methods: We delivered WOW-Epi through a hepatic arterial*

injection to VX2 hepatic tumor rabbit model (1.2 mg/kg). Results: VX2 tumor growth was selectively suppressed in the WOW-Epi-treated group compared with the control treated groups. The accumulation of WOW in nearby cancer cells was confirmed via electron-microscopy. Endocytosis seemed to be the mechanism underlying the uptake of WOW. Conclusion: WOW-Epi led to tumour growth suppression in vivo. WOW does not cause toxicity to arterial vessels. WOW-Epi will be hopefully used for repeated intra-arterial chemotherapy to HCC patients in the near future.

Hepatocellular carcinoma (HCC) is one of the most hard-to-treat cancers. HCC is often associated with complications, including liver cirrhosis or multiple intrahepatic tumors; consequently, only 30% of the patients with HCC can be operated. Nakakuma *et al*. first reported that iodized poppy seed oil (IPSO) can accumulate within HCC cells; anticancer agents were mixed with IPSO and administered *via* an intra-arterial injection (1). Kanematsu *et al*. reported a method of mixing a water-soluble anti-cancer agent with IPSO for intra-arterial injection (2). Konno *et al*. also reported targeted chemotherapy with styrene maleic acid neocarzinostatin dispersed in IPSO (3). Many modifications of this method in intra-arterial chemotherapy have been reported (4-6). However, anticancer agents are easily separated from IPSO within the first few hours; consequently, the anticancer agents may fail to accumulate within the tumor to produce the desired cytotoxic effect.

Higashi *et al*. reported epirubicin-entrapped water-in-oil-in-water emulsion (WOW) for intra-arterial chemotherapy for HCC patients (7, 8). The WOW was prepared with a membrane emulsification technique (9, 10). Emulsification using a fine glass membrane of equal pore size can prepare equal sized lipid microdroplets. In WOW emulsion, fine vesicles of the aqueous solution of an anti-cancer drug are dispersed in IPSO, which is also dispersed as fine vesicles of a particular size in the external aqueous phase. Higashi *et al*. reported the tumor growth suppression and the decrease in serum alpha-fetoprotein (AFP) levels in HCC patients (11).

In this non-clinical laboratory study, we prepared epirubicin-entrapped WOW (WOW-Epi) as per the good laboratory practice (GLP) guidelines. We employed the double-membrane emulsification technique and performed intra-arterial injections to reach the hypervascular tumor. Our results showed that the WOW-Epi exhibited selective accumulation in the tumor and demonstrated tumor growth suppression. The WOW technique for intra-arterial chemotherapy could be applied to treat patients with hypervascular tumors.

Materials and Methods

Chemicals. IPSO (Lipiodol Ultrafluid, Kodama, Co., Ltd., Tokyo, Japan) is composed of iodized ethyl esters of the fatty acids obtained from poppy seed oil and contains 37% iodine. Epirubicin hydrochloride was purchased from Kyowa Hakko Co., Ltd. (Tokyo, Japan). Polyglycerol esters of polycondensed fatty acids from castor oil were purchased from Sakamoto Yakuhin Kogyo Co., Ltd. (Osaka, Japan). Purified polyoxyethylene sorbitan monooleate (polysorbate80) was purchased from NOF Corporation (Tokyo, Japan).

Preparation of epirubicin-entrapped WOW. The WOW was prepared *via* the double-membrane emulsification technique (7). The controlled-pore glass membrane was prepared with a pore size of 5 μm or 20 μm. Sixty mg of epirubicin was dissolved in 3 ml of a 5.8% (w/v) glucose solution and mixed with 5 ml of IPSO and 500 μg of polyglycerol esters obtained from the polycondensed fatty acids of castor oil to form the water-in-oil (WO) emulsion; this was achieved by filtration with a hydrophobic-controlled, emulsifying pore glass membrane (7). The WO emulsion was injected through a hydrophilic controlled pore glass membrane at a rate of 10 ml/h into 7.5 ml of physiological saline containing 1% (w/v) polysorbate 80 to prepare WOW-Epi. The final volume of WOW-Epi was 15 ml, which was achieved using a double-membrane emulsifying machine (SPG Techno Ltd., Miyazaki, Japan) (7, 10). The WOW-Epi consisted of numerous IPSO microdroplets containing vesicles of the aqueous solution of epirubicin. The controlled pore glass membrane module was placed on a magnetic stirrer, and the agitation rotor was spun in the double-membrane emulsifying machine (1,200 rotations/min). These procedures were performed at room temperature (7, 10).

Microscopic characterization of WOW and the measurement of particle size distribution. Microscopic observation of the prepared WOW was performed using an optical microscope (BHS-323; Olympus Optics Co., Tokyo, Japan). The particle size distributions of the WOW and IPSO microdroplets were determined by a laser-diffraction particle-size analyzer (SALD-2000; Shimadzu Corp., Kyoto, Japan).

Targeting tumor cells in rabbit models. Male New Zealand White rabbits were purchased from KITAYAMA LABES Co. Ltd. (Nagano, Japan). VX2 tumor-bearing Male New Zealand White rabbits were purchased from Japan SLC Ltd. (Hamamatsu, Japan). VX2 tumor tissues from the original tumor-bearing rabbit were transferred to healthy rabbits. The rabbits were inoculated in the left lobe of the liver and, subsequently prepared as hepatic cancer models; their mean body weight was 2 kg. In each experiment, rabbits of similar age and weight were selected. After 2 weeks of tumor inoculation, WOW-Epi was administrated with intra-arterial injections *via* the proper hepatic artery and compared with the tumor size by injection of WOW-Epi or epirubicin solutions (1.2 mg/kg) in VX2 rabbit hepatic tumor models. Plasma epirubicin concentrations were measured at 6, 12, and 24 h after arterial injection. One day after the arterial injections, the epirubicin concentration of the tumor nodules and normal liver tissues was measured. Tumor size was measured *via* abdominal echogram 3 days, 7 days, and 14 days after treatment. Histological and electron microscopic observations were also performed 14 days after treatment. The procedures for tumor implantation and sacrifice of the animals were conducted according to the approved guidelines of the Institution's Animal Ethics Committee and the Declaration of Helsinki.

In vivo experiments. Before tumor implantation, the rabbits were anesthetized by isoflurane (inhaled concentration; induction: 2-4%, and mainrain: 2-3%) (anesthetic adjunct: dinitrogen monoxide; concentration: 50-70% in Oxygen). VX2 tumor fragments of approximately 1 mm^3 were injected intraparenchymally into the left lobes of the liver after laparotomy (12). To investigate the efficacy

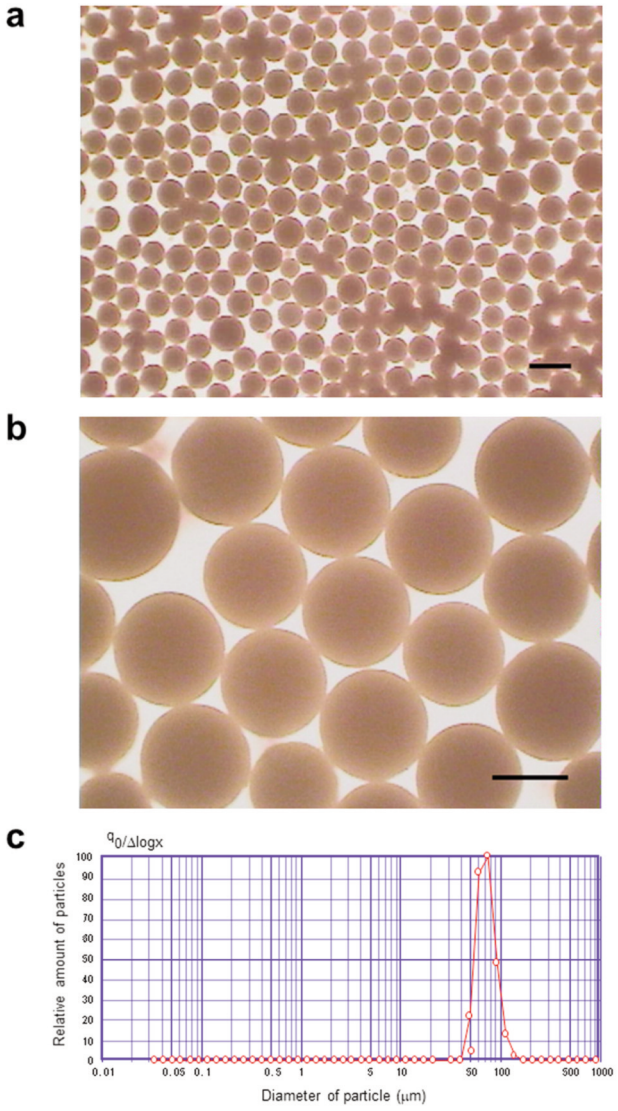

Figure 1. *Characterization of WOW-epi. (a) A representative photomicrograph of WOW (Black bar=100 μm). (b) Higher magnification (Black bar=50 μm). Note the almost equal-sized monodispersed lipid microdroplets. Each lipid droplet contains aqueous fine microdroplets including epirubicin. (c) The distribution of the particle size of WOW measured by a laser-diffraction particle-size analyzer (the median particle size of IPSO microdroplets in WOW: about 70 μm).*

of WOW-Epi (1.2 mg/kg) in tumor growth suppression, the animals were divided into four groups injected with WOW-Epi (n=3), WOW-entrapped 5% glucose (WOW-Bare; n=3), epirubicin solution (n=3), or saline (n=3). Animals in all four groups received interventional therapy at 2 weeks after tumor inoculation. A polyethylene catheter (inner diameter, 0.3 mm; outer diameter, 0.5 mm) was retrogradely inserted into the proper hepatic artery and WOW-Epi, WOW-Bare, epirubicin solution, or saline was manually injected. The groups other than the WOW-Epi injected group are control groups.

Measurement of the concentration of epirubicin accumulated in each organ in vivo. To detect the efficiency of the delivery of WOW, the epirubicin concentration in the tumor or normal liver tissue was measured. Animals were divided into two groups: those injected with WOW-Epi (n=2) and those injected with epirubicin solution (n=3). The animals in these groups received interventional therapy 14 days after inoculation of the tumor. The animals were sacrificed 1 day after injection; tumors and normal liver tissues were removed and epirubicin concentration was determined by liquid chromatography at Miyazaki University. The tissues were weighed immediately after dissection.

Evaluation of anti-tumor effects. Tumor size was measured with an abdominal echogram (Aplio SSA-700A, Toshiba, Japan) on days 3, 7, and 14 after treatment. We evaluated the anti-tumor effects by measuring the tumor volume with the calipers. The calculation was performed as follows: tumor volume (mm^3)=$0.5\times a\times b^2$, where a is the length of the major axis and b is the length of the minor axis (13).

Pathological findings in tumors following intra-arterial injection of WOW-Epi. Histological analysis and electron microscopy were also performed. The rabbits were sacrificed 14 days after the injection of WOW-Epi; the livers were resected and stored in optimal cutting temperature compounds frozen at –80˚C. Each section was stained with hematoxylin and eosin (HE) stain and with Oil Red O (fat-soluble dye) for light microscopy.

Statistics. Mean values and standard deviations were calculated. Statistical analysis was performed with a computer system (Provantis®) in LSI Medience Ltd. Co. Bartlett's test was used to compare the variances between the group data. The levels of 1% and 5% were considered to be significant, and the two-sided test was adopted.

Results

Characterization of WOW-Epi. The microscopic examination of WOW revealed numerous IPSO microdroplets suspended in the physiological saline containing polysolvate 80. The IPSO microdroplets contained many vesicles of the epirubicin solution (Figure 1a-b). The mean epirubicin concentration in WOW-Epi was 4 mg/ml. The median particle size of WOW was controlled to 70 μm (mean±SD, n=3) (Figure 1c). The median particle size of the vesicle of the solution of epirubicin in WO emulsion was measured to be 500 nm (mean±SD, n=3). The separation of the WOW emulsion into oil and water did not occur for ≥120 days when kept at a 4˚C.

Distribution of WOW-Epi after intra-arterial injection. VX2-rabbits were injected intraarterially with 2.4 mg/kg body weight of WOW-Epi (Figure 2). The accumulation of epirubicin in the tumor of animals injected with WOW-Epi was greater than that in the tumor of those injected with epirubicin alone.

Tumor growth suppression by an intra-arterial injection of WOW-Epi. The hepatic echogram showed tumor growth suppression and fibrosis on day 14 following the intra-

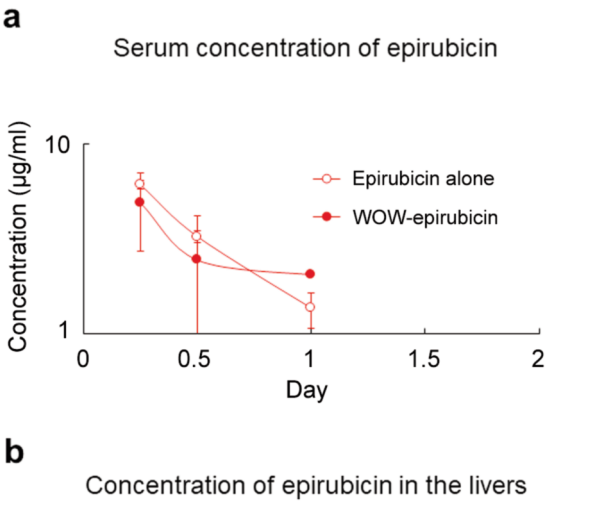

Figure 2. *Measurement of epirubicin concentration in the liver in vivo. (a) Serum concentration of epirubicin after injection. The serum concentration of epirubicin was measured 6 h, 12 h, and 24 h after intra-arterial injection of WOW-epi, or epirubicin solution (2.4 mg/kg of epirubicin). (b) Concentration of epirubicin in the liver. The concentrations of epirubicin in VX2 tumor, tumor border site, and normal liver were measured 24 h after intra-arterial injection using the same procedures. Tissues were weighed immediately after dissection and recorded as "wet weights".*

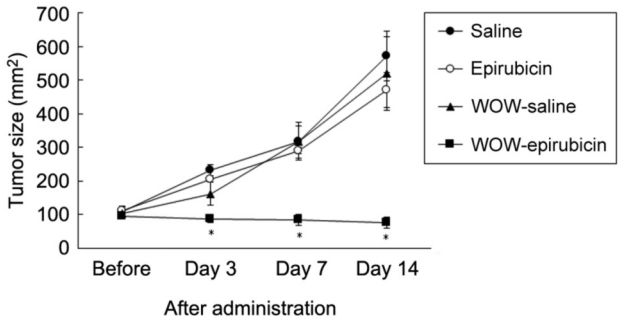

Figure 3. *Tumor growth suppression by intra-arterial injection of WOW-Epi in VX2 hepatic tumor bearing model. The tumor growth suppression was recognized by intra-arterial injection of WOW-Epi. Emulsion compared to control groups. Statistical analysis was performed using the Dunnett's multiple test (each value represents the mean±S.E. *p<0.01).*

arterial injection of WOW-Epi. Tumor growth suppression was confirmed by regression analyses that compared the WOW-Epi group with the group that received the epirubicin injection alone; conversely, no tumor growth suppression was evident in the WOW-Bare and saline control groups (Figure 3). Tumor growth suppression was obvious following the intra-arterial injection of WOW-Epi compared with that in the control groups. The control groups (saline, epirubicin, and WOW-Bare) were accompanied by peritoneal dissemination, but the WOW-Epi group was not (Figure 4a). In the WOW-Epi group, the tumor was significantly suppressed after the intra-arterial injection when compared with that in the control groups (epirubicin, WOW-Bare) ($p<0.01$). Complete suppression of the growth of VX-2 tumor tissues was obtained, caused by fibrosis and necrosis of cancer cells, so no disseminations were observed in the abdominal cavities of the WOW-Epi-treated group. Serum levels of serum glutamic oxaloacetic transaminase (sGOT), serum glutamic pyruvic transaminase (sGPT), lactate dehydrogenase (LDH), and total bilirubin were almost within normal range before and 14 days after treatment in all experimental groups (Tables I, II, III and IV).

When we tried to inject the IPSO-Epi conventional emulsion intraarterially, epirubicin separated, and IPSO easily accumulated in the hepatic artery. Consequently, we could not perform the injection using the same volume (1.2 mg/kg) of epirubicin and IPSO in the rabbit model and thus, we decided to exclude this treatment strategy (data not shown).

Pathological findings of a VX2 tumor after intra-arterial injection of WOW-Epi. The VX2 tumor tissues showed marked necrosis with reactive changes, and no remarkable damage was observed in the background hepatocytes after injection with WOW-Epi, as shown *via* H&E staining (Figure 4b). Accumulation of WOW in the VX2 tumor on day 3 following the intra-arterial injection, demonstrated that the WOW was drained from the normal liver on the same day. Oil Red O staining demonstrated the accumulation of lipiodol in the tumor tissues accompanied by accumulation in the cytoplasm of VX2 tumor cells (data not shown). Droplets of lipiodol were flushed out of the hepatocytes 7 days after injection.

Under the electron microscope, mitochondrial degradation and severe destruction of the cytoplasm and nucleus of the VX2 cancer cells was observed 14 days after the intra-arterial injection of WOW-Epi. Many small droplets of WOW were seen in the cytoplasm of the cancer cells; these droplets conjugated into large droplets; the small droplets fused to the cell membrane in some cancer cells. Tumor cells treated with epirubicin solution exhibited mitochondrial degradation and cell destruction at the margin of the tumor

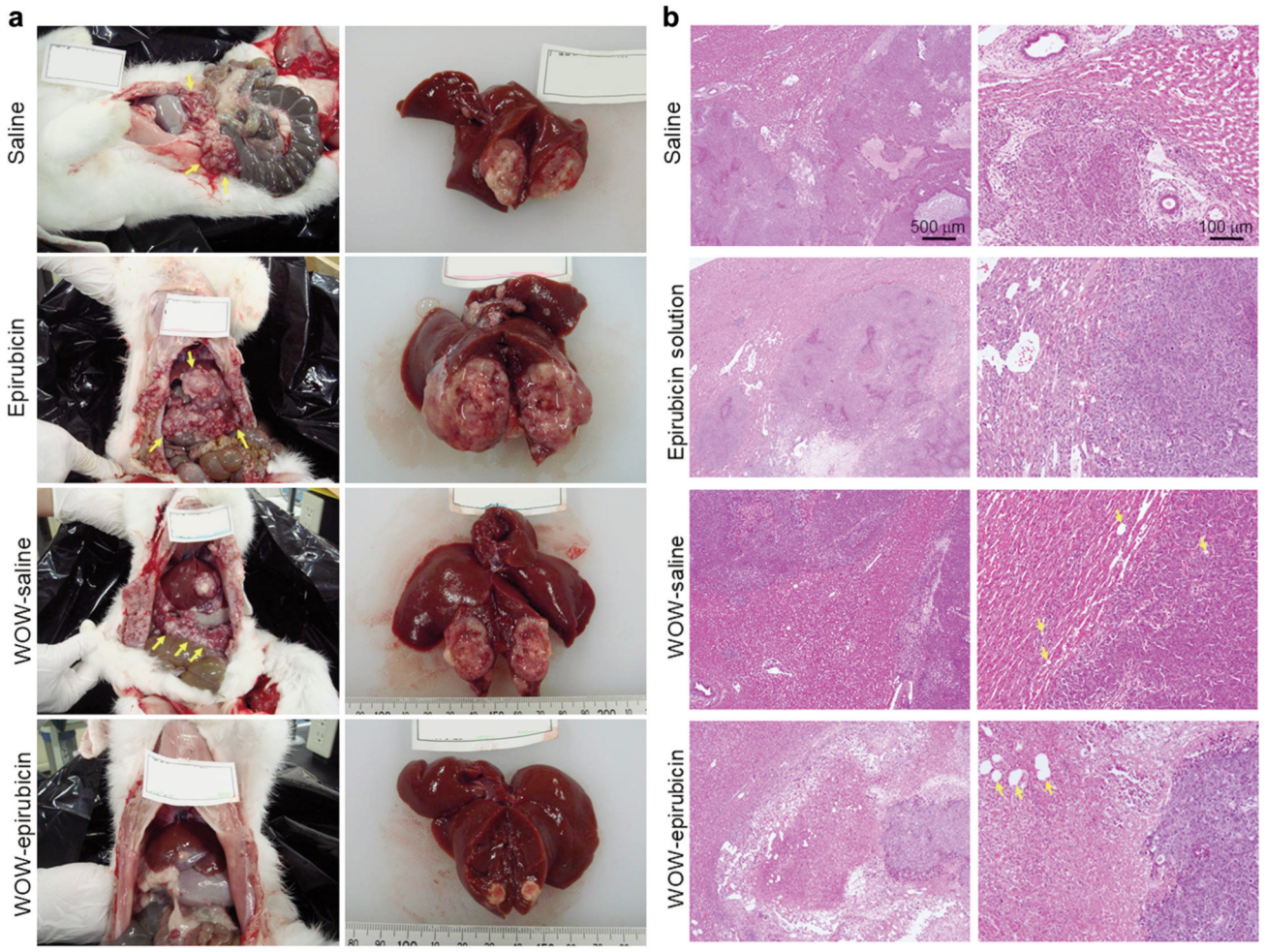

Figure 4. *Gross and pathological findings of VX2 tumors after intra-arterial injection of WOW-Epi. (a) Gross findings of VX2 tumors at 14 days after intra-arterial injection of WOW-Epi, WOW-Bare, epirubicin solution, or saline control (left: laparotomic findings, right: cut surface of the hepatic tumors). Yellow arrows indicate peritoneal disseminations. (b) Representative microphotographs of H&E staining, after intra-arterial injection of WOW-epi in VX2 tumor. Note vacuolation suggesting the accumulation of emulsion (yellow arrows; left, objective 4×; right, objective 20×).*

and normal tissues. In the control groups (saline, epirubicin, and WOW-Bare), there were no small droplets of WOW; however, there were irregularly shaped nuclei and increased number of mitochondria in the cancer cells when compared with normal hepatocytes (Figure 5). These results show that WOW-Epi can be used to deliver and reserve epirubicin within cancer cells in tumor tissues.

Detection of the cellular uptake mechanisms of epirubicin by WOW. Ten µl of WOW-Epi (7.6 mg/ml) or epirubicin solution (7.4 mg/ml) was added to the Hep G2 cells (3×10^4 cells), cultured in 800 µl of medium supplemented with 2.0 µg/ml of FITC-Dextran in a 14 mm diameter glass-bottom dish (Matsunami Ltd., Tokyo, Japan), and incubated at 37˚C or 4˚C for 90 min. The cells were observed under the fluorescence microscope (Research inverted system microscope; Olympus IX-71).

From the *in vitro* fluorescent observations, we observed the spots of FITC-Dextran in the cytoplasm of cancer cells. The accumulation of epirubicin delivered by WOW-Epi demonstrated remarkably strong fluorescent intensity of rhodamine at 37˚C, but it was suppressed at 4˚C, due to endocytosis, one of the mechanisms responsible for delivering WOW-Epi into the cancer cells (Figure 6).

Discussion

Intra-arterial chemotherapy and transcatheter arterial chemo-embolization (TACE) have been widely used as one of the effective, first-line treatments for HCC (4, 14). Oil-in-water

Table I. *Effect of Epi-WOW emulsion on biochemical findings in rabbits (before administration).*

Groups	Number of animal	TP (g/dl)	ALB (g/dl)	A/G	T-BIL (mg/dl)	AST (IU/l)	ALT (IU/l)	ALP (IU/l)	T-CHO (mg/dl)	TG (mg/dl)	PL (mg/dl)	GLU (mg/dl)
Saline	3	5.4±0.1	4.4±0.1	4.40±0.12	0.0±0.0	18±2	41±11	410±86	44±2	45±11	92±2	133±2
Epirubicin	3	5.6±0.1	4.7±0.1	5.11±0.59	0.0±0.0	16±2	41±8	352±48	47±8	56±24	94±14	133±6
WOW-saline	3	5.4±0.1	4.3±0.1	4.04±0.11	0.0±0.0	16±2	29±3	387±43	50±5	61±20	97±4	121±2
WOW-epirubicin	3	5.5±0.0	4.5±0.0	4.57±0.30	0.0±0.0	19±1	28±2	457±73	48±3	60±14	95±3	115±5

Groups	Number of animal	BUN (mg/dl)	CRE (mg/dl)	Ca (mg/dl)	IP (mg/dl)	Na (mEq/l)	K (mEq/l)	Cl (mEq/l)
Saline	3	20.3±0.7	1.1±0.0	12.4±0.3	7.3±0.0	141.6±1.4	3.34±0.26	101.8±0.7
Epirubicin	3	19.5±0.8	1.2±0.0	12.9±0.3	6.7±0.2	144.0±0.4	3.38±0.13	104.2±1.2
WOW-saline	3	21.0±1.4	1.0±0.0	12.6±0.1	7.6±0.2	143.0±0.5	3.15±0.07	105.5±2.4
WOW-epirubicin	3	23.2±0.9	1.1±0.1	13.0±0.1	7.6±0.3	143.1±0.7	3.18±0.09	98.4±1.0

Each value represents the mean±S.E.

Table II. *Effect of Epi-WOW emulsion on biochemical findings in rabbits (after administration).*

Groups	Number of animal	TP (g/dl)	ALB (g/dl)	A/G	T-BIL (mg/dl)	AST (IU/l)	ALT (IU/l)	ALP (IU/l)	T-CHO (mg/dl)	TG (mg/dl)	PL (mg/dl)	GLU (mg/dl)
Saline	3	5.5±0.2	3.9±0.3	2.37±0.32	0.0±0.0	26±6	23±1	154±39	70±14	246±113	146±26	117±6
Epirubicin	3	5.89±0.3	3.9±0.3	2.09±0.42	0.0±0.0	25±5	23±2	121±32	75±17	203±93	139±31	112±6
WOW-saline	3	5.7±0.1	4.0±0.2	2.40±0.23	0.0±0.0	28±6	23±2	213±61	67±8	206±48	139±13	121±5
WOW-epirubicin	3	5.7±0.1	4.3±0.2	3.06±0.34	0.0±0.0	23±5	52±27	330±2*	101±44	114±40	132±25	108±4

Groups	Number of animal	BUN (mg/dl)	CRE (mg/dl)	Ca (mg/dl)	IP (mg/dl)	Na (mEq/l)	K (mEq/l)	Cl (mEq/l)
Saline	3	28.1±10.7	1.1±0.0	13.0±0.3	7.6±0.9	143.0±1.8	4.13±0.43	100.6±2.1
Epirubicin	3	19.4±2.0	1.2±0.1	13.1±0.2	6.9±0.4	143.0±1.2	3.76±0.03	100.2±1.0
WOW-saline	3	23.1±0.4	1.2±0.0	13.2±0.2	7.0±0.2	144.7±1.1	3.58±0.13	101.2±1.5
WOW-epirubicin	3	20.3±1.0	1.2±0.1	13.7±0.5	6.9±0.3	142.6±0.6	3.98±0.26	99.7±1.0

Each value represents the mean±S.E. *$p<0.05$; Significant difference from Vehicle (Dunnett's multiple test).

Table III. *Effect of Epi-WOW emulsion on hematological findings in rabbits (before administration).*

Groups	Number of animal	WBC (10^3/μl)	RBC (10^4/μl)	HGB (g/dl)	HCT (%)	MCV (fL)	MCH (pg)	MCHC (g/dl)	PLT (10^4/μl)
Saline	3	7.55±1.18	618±4	13.5±0.2	38.1±0.4	61.8±0.7	21.8±0.2	35.4±0.5	37.6±6.7
Epirubicin	3	9.50±0.57	650±23	14.1±0.4	40.2±1.0	61.9±0.7	21.7±0.5	35.1±0.5	24.0±6.0
WOW-saline	3	8.48±0.21	610±4	13.3±0.2	38.4±0.9	62.9±1.3	21.8±0.3	34.7±0.2	49.0±14.1
WOW-epirubicin	3	9.17±0.21	671±5	14.2±0.1	40.1±0.8	59.9±1.2	21.1±0.2	35.3±0.4	35.4±0.5

Groups	Number of animal	NEUT (%)	LYMP (%)	MONO (%)	EOS (%)	BASO (%)	LUC (%)	RET (%)
Saline	3	30.1±1.0	58.4±1.4	3.8±0.3	1.1±0.3	6.2±1.5	0.4±0.1	2.7±0.2
Epirubicin	3	39.8±12.6	47.8±12.5	5.4±0.7	0.9±0.1	5.7±0.7	0.4±0.1	3.8±0.6
WOW-saline	3	32.3±5.8	55.8±6.3	6.0±0.5	1.2±0.1	4.4±0.1	0.4±0.0	3.4±0.1
WOW-epirubicin	3	27.6±2.3	60.9±2.6	4.1±1.0	1.6±0.2	5.3±0.7	0.6±0.3	2.5±0.3

Each value represents the mean±S.E. *$p<0.05$; Significant difference from Vehicle (Dunnett's multiple test).

Table IV. *Effect of Epi-WOW emulsion on hematological findings in rabbits (after administration).*

Groups	Number of animal	WBC (10^3/μl)	RBC (10^4/μl)	HGB (g/dl)	HCT (%)	MCV (fL)	MCH (pg)	MCHC (g/dl)	PLT (10^4/μl)
Saline	3	17.58±2.56	591±22	12.6±0.7	37.3±1.9	63.1±1.0	21.3±0.4	33.8±0.2	57.8±16.3
Epirubicin	3	21.08±4.59	636±21	13.6±0.5	39.4±0.8	61.9±1.3	21.3±0.4	34.4±0.7	50.3±8.2
WOW-saline	3	14.42±1.90	623±13	13.5±0.4	39.5±1.6	63.3±1.3	21.7±0.3	34.3±0.3	59.8±12.0
WOW-epirubicin	3	14.02±2.46	683±31*	14.3±0.3	40.9±1.5	59.9±0.9	20.9±0.5	34.9±0.5	45.3±2.5

Groups	Number of animal	NEUT (%)	LYMP (%)	MONO (%)	EOS (%)	BASO (%)	LUC (%)	RET (%)
Saline	3	56.1±8.8	32.4±9.0	6.7±0.8	0.8±0.2	3.5±1.7	0.6±0.1	3.4±0.5
Epirubicin	3	57.9±6.3	26.4±6.0	9.1±0.5	1.3±0.3	4.2±0.7	1.2±0.3	4.0±0.7
WOW-saline	3	46.4±7.2	41.9±8.2	7.4±1.2	0.6±0.1	2.9±0.2	0.9±0.3	3.6±0.4
WOW-epirubicin	3	38.8±5.3	49.9±7.2	5.1±1.1	2.1±0.5*	3.9±0.6	0.3±0.1	2.6±0.5

Each value represents the mean±S.E. *p<0.05; Significant difference from Vehicle (Dunnett's multiple test).

(OW) emulsion prepared by mixing IPSO with a solution of an anticancer drug is a conventional intra-arterial chemotherapy. The range of particle size distribution of IPSO droplets in a conventional OW emulsion is a few μm to 1,000 μm. It is difficult to produce lipiodol microdroplets of uniform size. The solution of anticancer drug is easily separated from the IPSO and the anticancer drug is flowed away from the liver, retaining IPSO in the tumors (2, 7). If IPSO microdroplets are too small for the inner diameter of the tumor vasculature, they may pass through the tumor tissues and normal tissues; if the microdroplets are too large, they are trapped proximal to the tumor vasculature (15, 16).

Drug-eluting beads (DEBs) have been developed for transcatheter treatment of HCC because DEBs can deliver higher dose of the anticancer agents and prolong the contact time with the tumor (17-21). Treatment with DEBs reduces the amount of anticancer agent reaching the systemic circulation (18). TACE with DEBs for patients with HCC has reported either equal or surpassing results compared with conventional TACE using lipiodol (22). However, several side effects have also been reported in TACE with DEBs. There are risks of gall bladder ischemia, acute cholecystitis, hepatic abscess formation, delayed intra-tumoral hemorrhage, post-embolization syndrome, and biliobronchial fistula, resulting in the development of adult respiratory distress syndrome after TACE (23-26).

Higashi *et al*. reported that microdroplets sized 70 μm were adopted for use with the WOW (15). The WOW has an embolic effect on the peripheral hepatic artery, and also WOW shows rapid washout from the normal hepatic parenchyma (15). The slow release of anticancer drugs from the WOW can minimize cytotoxic damage to the normal hepatic parenchyma. Ikushima *et al*. reported that the 3-year survival rate of patients with HCC following intra-arterial chemotherapy with WOW was 76% (27, 28). The WOW can deliver higher dose of the anticancer drugs and prolong the contact time of drugs with the tumor. The WOW does not contain embolic substances, so temporal ischemic change occurs after intra-arterial chemotherapy. Thereafter, WOW is easily flushed out through the venous and lymphatic drainage systems in normal hepatic tissues (7, 27, 28).

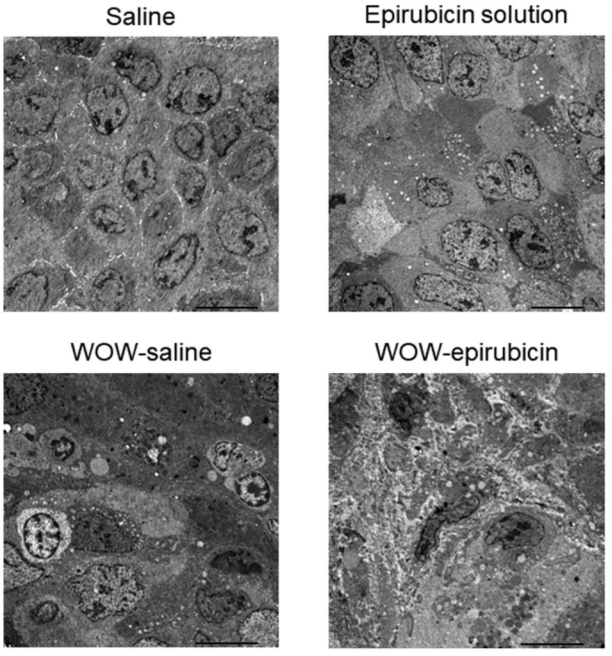

Figure 5. *Electron microphotographs of WOW-epi 14 days after the intra-arterial injection (×5,000). Note the emergence of nuclear irregularity and degenerated mitochondria in the VX2 cancer cells treated with WOW-epi.*

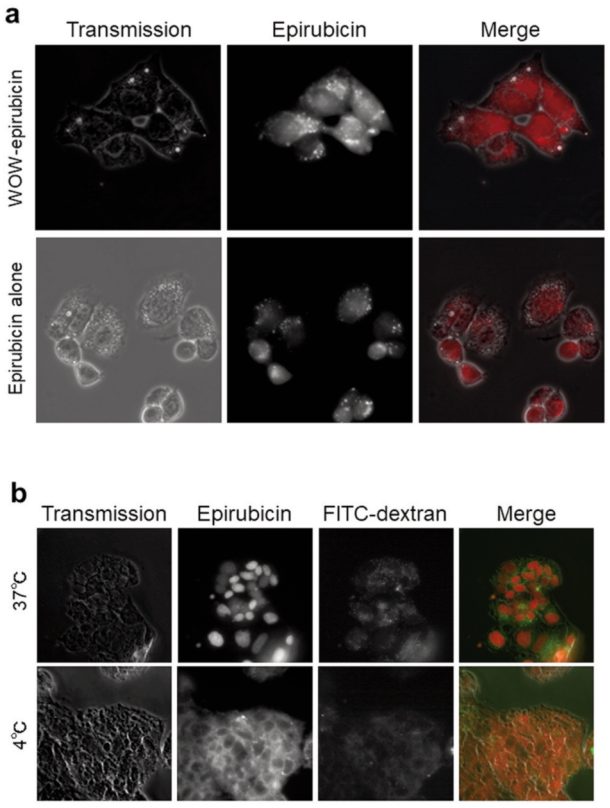

Figure 6. *Fluorescence microscopic analysis of intracellular uptake of WOW-Epi in Hep-G2 cells. (a) Treatment with WOW-Epi at 37°C (3 h incubation). (b) Uptake of WOW-Epi with FITC-dextran at 37°C or 4°C (90 min incubation).*

We realized that our WOW sized 70 μm was stable 10 months after preparation. The accumulation of WOW was shown by soft X-ray imaging. The radiosensitive component, lipiodol, showed selective accumulation in the VX2 tumor. The accumulation of the WOW was diffuse compared with the lipiodol mix solution. The IPSO deposits, a component of the WOW, in the tumor tissues, was recognized by Oil Red O staining; accumulation of the WOW in the cytoplasm of cancer cells was observed under electron microscopy. The accumulation of lipid capsules that occurred with the WOW in the VX2 cancer cells was recognized by electron microscopy. Detection of the uptake mechanism of the WOW into the cancer cells is important. It is thought, that the WOW can easily accumulate in cancer tissues due to the poor drainage through the lymph tissues around the tumour.

The mechanisms underlying uptake from the cancer cells are thought to be (I) endocytosis, (II) cell membrane fusion with a surfactant of the WOW, (III) lipid uptake using a transporter protein in the cell membrane, and (IV) physical fusion that causes attachment between the WOW and cancer cell membrane. The uptake of FITC-dextran and epirubicin from Hep-G2 cancer cells was controlled in a temperature-dependent manner, so the mechanism of uptake of WOW from cancer cells is thought to be endocytosis. It is also thought that the fusion between lipid components in the cell membrane and the surfactant in the WOW easily occurs, and that lipid components of the WOW are transported into the cytoplasm of cancer cells. Using electron microscopy, we aim to assess the uptake of the WOW in cancer tissues in the early stages following intra-arterial injection using electron microscopy.

The accumulation of epirubicin in the cancer cells increased after using the WOW; this is thought to be caused by endocytosis. We hope that the WOW will be applied to standard therapies for HCC. The use of the WOW decreases the damages that occur to the normal liver parenchyma by the minimal embolic effects on the peripheral artery and the slow release of the anticancer agent.

According to these advantages, we are able to use the WOW emulsion safely in patients with recurrent HCC after surgical resection. These results showed that an epirubicin-entrapped WOW is capable of delivering and reserving the anticancer agent to the tumor, thus the WOW is most useful for intra-arterial delivery as a carrier of intra-arterial chemotherapy in cases of HCC.

Tumor growth suppression was observed using the intra-arterial injection of WOW-Epi to hypervascular tumors. We hope to prepare a boron-compound-entrapped WOW (WOW-Boron) and would like to apply intra-arterial chemotherapy techniques using WOW-Boron for boron neutron-capture therapy for hypervascular tumors in the liver in the near future (29-32).

Conclusion

Anticancer agent-entrapped WOW led to tumor growth suppression *in vivo*. Our results provide evidence for feasible further evaluation of intra-arterial chemotherapy using WOW in the treatment against HCC. As WOW does not produce toxicity within the arterial vessels, repetitive trans-arterial chemotherapy could be performed to improve the therapeutic strategy for targeting HCC.

Conflicts of Interest

The Authors declare no competing financial interests regarding this study.

Authors' Contributions

Conceived and designed the experiments; HY, TT, TI, TN, ME, SH, and HT. Performed the experiments; HY, TF, MY, MF, YM, RM, YM, MN, TN, and KA. Analyzed and interpreted the data; HY, TF, TT, TI, YM, ND, II, KS, MN, YN, YF, TH, TN, KA, SH, and HT. Contributed reagents, materials, analysis tools or data; HY, TT, TI,

MF, YM, YO, MN, TN, KA, TS, KK, MO, JN, and HT. Wrote the paper; HY, TF, TT, TI, ND, MN, and YF.

Acknowledgements

This work was supported in part by a Grant-in-Aid from the Ministry of Education, Science and Culture of Japan (No. 11691202, No. 11557092, and No. 24390311 to Hironobu Yanagie), a Grant-in-Aid from Kyushu Bureau of the Ministry of Economy (No. 17G8009 to Hironobu Yanagie), Trade and Industry, a Grant of The Tokyo Biochemical Research Foundation, and a Grant from the Foundation for the Promotion of Cancer Research in Japan. The Authors appreciate Mrs. Yuriko Sakurai and Mrs.Kikue Mouri for thier help in the preparations of all pathological samples.

References

1 Nakakuma K, Tashiro S, Hiraoka T, Uemura K, Konno T, Miyauchi Y and Yokoyama I: Studies on anticancer treatment with an oily anticancer drug injected into the ligated feeding hepatic artery for liver cancer. Cancer *52*: 2193-2200, 1983. PMID: 6196102. DOI: 10.1002/1097-0142(19831215)52:12<2193::AID-CNCR2820521203>3.0.CO;2-R

2 Knematsu T, Inokuchi K, Sugimachi K, Furuta T, Sonoda T, Tamura S and Hasuo K: Selective effects of lipiodolized antitumor agents. J Surg Oncol *25*: 218-226, 1984. PMID: 6199624. DOI: 10.1002/jso.2930250317

3 Konno T, Maeda H, Iwai K, Tashiro S, Maki S, Morinaga T, Mochinaga M, Hiraoka T and Yokoyama I: Effect of arterial administration of high-molecular weight anticancer agent SMANCS with lipid lymphographic agent on hepatoma: A preliminary report. Eur J Cancer Clin Oncol *19*: 1053-1065, 1983. PMID: 6311559. DOI: 10.1016/0277-5379(83)90028-7

4 Miller DM, O'Leary TJ and Girton M: Distribution of iodized oil within the liver after hepatic arterial injection. Radiology *162*: 849-852, 1987. PMID: 3027747. DOI: 10.1148/radiology.162.3.3027747

5 Katagiri Y, Mabuchi K, Itakura T, Naora K, Iwamoto K, Nozu Y, Hirai S, Ikeda N and Kawai T: Adriamycin-lipiodol suspension for i.a. chemotherapy of hepatocellular carcinoma. Cancer Chemother Pharmacol *23*: 238-242, 1989. PMID: 2538250. DOI: 10.1007/BF00451648

6 Idée JM and Guiu B: Use of Lipiodol as a drug-delivery system for transcatheter arterial chemo- embolization of hepatocellular carcinoma: a review. Crit Rev Oncol Hematol *88*: 530-549, 2013. PMID: 23921081. DOI: 10.1016/j.critrevonc.2013.07.003

7 Higashi S, Shimizu M, Nakashima T, Iwata K, Uchiyama F, Tateno S, Tamura S and Setoguchi T: Arterial injection chemotherapy for hepatocellular carcinoma using monodispersed poppy-seed oil microdroplets containing fine aqueous vesicles of epirubicin. Cancer *75*: 1245-1254, 1995. PMID: 7882276. DOI: 10.1002/1097-0142(19950315)75:6<1245::aid-cncr2820750606>3.0.co;2-u

8 Higashi S, Maeda Y, Kai M, Kitamura T, Tsubouchi H, Tamura S and Setoguchi T: A case of hepatocellular carcinoma effectively treated with epirubicin aqueous vesicles in monodispersed iodized poppy-seed oil microdroplets. Hepatoagastroenterology *43*: 1427-1430, 1996. PMID: 8975943.

9 Nakashima T, Shimizu M and Kukizaki M: Membrane emulsification by microporous glass. Key Eng Mater *61-62*: 513-516, 1991.

10 Nakashima T, Shimizu M, and Kukizaki M: Particle control of emulsion by membrane emulsification and its applications. Adv Drug Deliv Rev *45*: 47-56, 2000. PMID: 11104896. DOI: 10.1016/s0169-409x(00)00099-5

11 Higashi S, Shimizu M, Nakashima T, Iwata K, Uchiyama F, Tateno S, Tamura S and Setoguchi T: Hepatic arterial injection chemotherapy for hepatocellular carcinoma with epirubicin aqueous solution as numerous vesicles in iodinated poppy-seed oil microdroplets: clinical application of water-in-oil-in-water emulsion prepared using a membrane emulsification technique. Adv Drug Deliv Rev *45*: 57-64, 2000. PMID: 11104897. DOI: 10.1016/s0169-409x(00)00100-9

12 Burgener FA: Peritoneal hepatic artery embolization in rabbits with VX2 carcinoma of the liver. Cancer *46*: 56-63, 1980. PMID: 7388767. DOI: 10.1002/1097-0142(19800701)46:1<56::aid-cncr2820460113>3.0.co;2-c

13 Dewi N, Mi P, Yanagie H, Sakurai Y, Morishita Y, Yanagawa M, Nakagawa T, Shinohara A, Matsukawa T, Yokoyama T, Cabral H, Suzuki M, Sakurai Y, Tanaka H, Ono K, Nishiyama N, Kataoka K and Takahashi H: *In vivo* evaluation of neutron capture therapy effectivity using calcium phosphate-based nanoparticles as Gd-DTPA delivery agent. J Cancer Res Clin Oncol *142*: 767-775, 2016. PMID: 26650198. DOI: 10.1007/s00432-015-2085-0

14 Furuse J, Ishii H, Satake M, Onaya H, Nose H, Mikami S, Sakai H, Mera K, Maru Y and Yoshino M: Pilot study of transcatheter arterial chemoembolization with degradable starch microspheres in patients with hepatocellular carcinoma. Am J Clin Oncol *26*: 159-164, 2003. PMID: 12714888. DOI: 10.1097/00000421-200304000-00012

15 Higashi S, Tabata N, Kondo K, Maeda Y, Shimizu M, Nakashima T and Setoguchi T: Size of lipid microdroplets effects results of hepatic arterial chemotherapy with an anticancer agent in water-in-oil-in-water emulsion to hepatocellular carcinoma. J Pharmacol Exp Ther *289*: 816-819, 1999. PMID: 10215657.

16 Belli L, Magistretti G, Puricelli GP, Damiani G, Colombo E and Cornalba GP: Arteritis following intra-arterial chemotherapy for liver tumors. Eur Radiol *7*: 323-326, 1997. PMID: 9087350. DOI: 10.1007/s003300050159

17 Bishay VL, Maglione K, Khanna R, Lee KM, Fischman AM, Lookstein RA and Kim E: Chemo-embolization with drug-eluting microspheres (DEM-TACE) for hepatocellular carcinoma: single-center review of safety and efficacy. J Hepatocel Carcinoma *1*: 187-193, 2014. PMID: 27508187. DOI: 10.2147/JHC.S71602

18 Nam HC, Jang B, Myeong SJ: Transarterial chemoembolization with drug-eluting beads in hepatocellular carcinoma. World J Gastroenterol *22*: 8853-8861, 2016. PMID: 27833376. DOI: 10.3748/wjg.v22.i40.8853

19 Xiang H, Long L, Yao Y, Fang Z, Zhang Z and Zhang Y: CalliSpheres drug-eluting bead transcatheter arterial chemoembolization presents with better efficacy and equal safety compared to conventional tace in treating patients with hepatocellular carcinoma. Technol Cancer Res Treat *18*: 1533033819830751, 2019. PMID: 30862264. DOI: 10.1177/1533033819830751

20 Zhang ZS, Li HZ, Ma C and Xiao YD: Conventional *versus* drug-eluting beads chemoembolization for infiltrative hepatocellular carcinoma: a comparison of efficacy and safety. BMC Cancer *19(1)*: 1162, 2019. PMID: 31783814. DOI: 10.1186/s12885-019-6386-6

21 Cao WZ, Zhou ZQ, Jiang S, Li H, Niu W, Gao P, Li GJ and Chen F: Efficacy and safety of drug-eluting beads for transarterial chemoembolization in patients with advanced hepatocellular carcinoma. Exp Ther Med *18(6)*: 4625-4630, 2019. PMID: 31798699. DOI: 10.3892/etm.2019.8163

22 Kloeckner R, Weinmann A, Prinz F, Pinto dos Santos D, Ruckes C, Dueber C and Pitton MB: Conventional transarterial chemoembolization *versus* drug-eluting bead transarterial chemoembolization for the treatment of hepatocellular carcinoma. BMC Cancer *15*: 465-474, 2015. PMID: 26059447. DOI: 10.1186/s12885-015- 1480-x

23 Lee S, Kim KM, Lee SJ, Lee KH, Lee DY, Kim MD, Kim DY, Kim SU and Won JY: Hepatic arterial damage after transarterial chemoembolization for the treatment of hepatocellular carcinoma: comparison of drug-eluting bead and conventional chemoembolization in a retrospective controlled study. Acta Radiol *58*: 131-139, 2017. PMID: 27217418. DOI: 10.1177/0284185116648501

24 Ma Y, Zhao C, Zhao H, Li H, Chen C, Xiang H, Zheng C, Ma C, Luo C, Qiu H, Yao Y, Hu H, Xiong B, Zhou J, Zhu H and Long Q: Comparison of treatment efficacy and safety between drug-eluting bead transarterial chemo-embolization with CalliSpheres® microspheres and conventional transarterial chemoembolization as first-line treatment in hepatocellular carcinoma patients. Am J Transl Res *11(12)*: 7456-7470, 2019. PMID: 31934293.

25 Kim YW, Kwon JH, Nam SW, Jang JW, Jung HS, Shin YR, Park ES and Shim DJ: Sustained multiple organ ischaemia after transarterial chemoembolization with drug-eluting beads for hepatocellular carcinoma. Exp Ther Med *15(2)*: 1479-1483, 2018. PMID: 29434732. DOI: 10.3892/etm.2017.5540

26 Elsayed AG, Martin JM and Pacioles T: Rash and subcutaneous fat necrosis after DEB-TACE with doxorubicin. BMJ Case Rep *2018*: bcr2017222394, 2018. PMID: 29305365. DOI: 10.1136/bcr-2017-222394

27 Ikushima I, Higashi S, Seguchi K, Ishii A, Ota Y, Shima M, Kanemaru M and Hidaka Y: Transarterial infusion chemotherapy with epirubicin in water-in-oil-in-water emulsion for recurrent hepatocellular carcinoma in the residual liver after hepatectomy. Eur J Radiol *69*: 114-119, 2009. PMID: 17935921. DOI: 10.1016/j.ejrad.2007.09.001

28 Ikushima I, Higashi S, Ishii A, Seguchi K, Iryo Y and Yamashita Y: Ultraselective transcatheter infusion of epirubicin in water-in-oil-in-water emulsion for small hepatocellular carcinoma. Br J Radiol *85*: 584-589, 2012. PMID: 22422389. DOI: 10.1259/bjr/16376960

29 Yanagie H, Tomita T, Kobayashi H, Fujii Y, Nonaka Y, Saegusa Y, Hasumi K, Eriguchi M, Kobayashi T and Ono K: Inhibition of human pancreatic cancer growth in nude mice by boron neutron-capture therapy. Br J Cancer *75*: 660-665, 1997. PMID: 9043021. DOI: 10.1038/bjc.1997.118

30 Yanagie H, Higashi S, Seguchi K, Ikushima I, Fujihara M, Nonaka Y, Oyama K, Maruyama S, Hatae R, Suzuki M, Masunaga S, Kinashi T, Sakurai Y, Tanaka H, Kondo N, Narabayashi M, Kajiyama T, Maruhashi A, Ono K, Nakajima J, Ono M, Takahashi H and Eriguchi M: Pilot clinical study of boron neutron capture therapy for recurrent hepatic cancer involving the intra-arterial injection of a (10)BSH-containing WOW emulsion, Appl Radiat Isot *88*: 32-37, 2014. PMID: 24559940. DOI: 10.1016/j.apradiso.2014.01.014

31 Yanagie H, Higashi S, Ikushima I, Seguchi K, Mizumachi R, Murata Y, Morishita Y, Shinohara A, Mikado S, Yasuda N, Fujihara M, Sakurai Y, Mouri K, Yanagawa M, Iizuka T, Suzuki M, Sakurai Y, Masunaga S, Tanaka H, Matsukawa T, Yokoyama K, Dewi N, Ogura K, Nonaka Y, Sugiyama H, Kajiyama T, Yui S, Nishimura R, Ono K, Takamoto S, Nakajima J, Ono M, Eriguchi M, Hasumi K and Takahashi H: Selective enhancement of boron accumulation in tumours with intra-arterial administration of boron-entrapped water-in-oil-in-water emulsion as a novel boron carrier in VX-2 rabbit hepatic cancer model for neutron capture therapy. Br J Radiol *13*: 20170004, 2017. PMID: 28406315. DOI: 10.1259/bjr.20170004

32 Yanagie H, Yanagawa M, Higuchi T, Mizumachi R, Fujihara M, Morishita Y, Sakurai Y, Mouri K, Dewi N, Nonaka Y, Shinohara A, Matsukawa T, Kubota A, Yokoyama K, Suzuki M, Masunaga S, Sakurai Y, Tanaka H, Ono K, Yamauchi H, Ono M, Nakajima J, Higashi S and Takahashi H: Single-dose toxicity study by intra-arterial injection of 10BSH entrapped water-in-oil-in-water emulsion for boron neutron capture therapy to hepatocellular carcinoma. Appl Radiat Isot *163*: 1-8, 2020. PMID: 32561043. DOI: 10.1016/j.apradiso.2020.109202

Received September 20, 2020
Revised October 18, 2020
Accepted October 19, 2020