

# Normal Size Ovary Carcinoma Syndrome with Inguinal Ovarian Cancer Lymph Node Metastases – A Case Report and Literature Review

NICOLAE BACALBASA<sup>1</sup>, IRINA BALESCU<sup>2</sup>, CRISTIAN BALALAU<sup>1,3</sup>,  
OLIVIA IONESCU<sup>4</sup> and CLAUDIA STOICA<sup>5</sup>

<sup>1</sup>Department of Obstetrics and Gynecology “Carol Davila” University of Medicine and Pharmacy, Bucharest, Romania;

<sup>2</sup>Department of General Surgery “Ponderas” Academic Hospital, Bucharest, Romania;

<sup>3</sup>Department of General Surgery, “Sf. Pantelimon” Clinical Hospital, Bucharest, Romania;

<sup>4</sup>Department of Obstetrics and Gynecology “Fichtelgebirge”, Clinic, Marktredwitz, Germany;

<sup>5</sup>Department of General Surgery “Ilfov” Clinical County Hospital, Bucharest, Romania

**Abstract.** *Inguinal lymph node mass as the first sign in patients with ovarian cancer represents a rare situation, with only few cases being reported so far. We present the case of a 46-year-old patient who presented for the apparition of bilateral inguinal tumoral masses in the absence of any other pathological signs. The biopsy revealed the presence of an adenocarcinoma with probable genital origin; however, neither the gynaecological examination nor the computed tomography demonstrated the presence of any suspect lesion. The patient was submitted to a positron emission computed tomography which revealed a high capitation in both adnexal areas as well as at the level of the inguinal lymph nodes. The patient was submitted to surgery, the frozen section of the adnexas confirming the ovarian origin of the tumor. Complete cytoreduction to no residual disease was successfully performed. At one-year follow-up the patient is free of any recurrent disease.*

Ovarian cancer remains an aggressive gynaecological malignancy associated with poor survival rates especially if complete cytoreductive surgery cannot be achieved. Most commonly it metastasises *via* peritoneal, haematogenous or lymphatic route, leading to the apparition of disseminated lesion from the moment of the initial diagnosis. However,

even in cases presenting systemic disease, it seems that performing a maximal cytoreductive surgical procedure remains the only therapeutic chance to improve the overall survival (1-8). Most commonly patients diagnosed with ovarian cancer complain of weight loss, abdominal discomfort or distension, constipation or early satiety. In a very small number of cases all these signs might be missing, the only complain of the patient being related to the apparition of a unilateral or bilateral inguinal mass. This represents less than 3% of cases and consists of cases in which the lymphatic spread is directed mainly to the groin lymph node stations (9).

## Case Report

A 46-year-old patient with no significant medical history presented for the apparition of bilateral inguinal tumoral masses; the patient denied other signs or symptoms such as weight loss, fever, abdominal pain or constipation. A biopsy of the inguinal masses was performed, the histopathological studies revealing the presence of tumoral cells mimicking an adenocarcinoma probably originating from the gynaecological tract. The patient was submitted to vaginal ultrasound, cervical and endometrial biopsies; however no pathological results were found. She was also submitted to a full body computed tomography which revealed the presence of a few pelvic adenopathies, without any other modifications, so she was also submitted to a PET CT which revealed the presence of a high fixation area at the level of the both adnexal areas as well as in the inguinal areas; however, it should be mentioned that although both adnexas presented an increased fixation at PET CT none of the two ovaries were modified in volume at the standard computed tomography (Figure 1). The laboratory analyses revealed an

This article is freely accessible online.

*Correspondence to:* Irina Balescu, Department of General Surgery “Ponderas” Academic Hospital, Bucharest, Romania. Tel: +40 724077709, e-mail: irina.balescu@ponderas-ah.ro

*Key Words:* Normal size ovarian cancer, lymphatic spread, inguinal lymph node metastases.

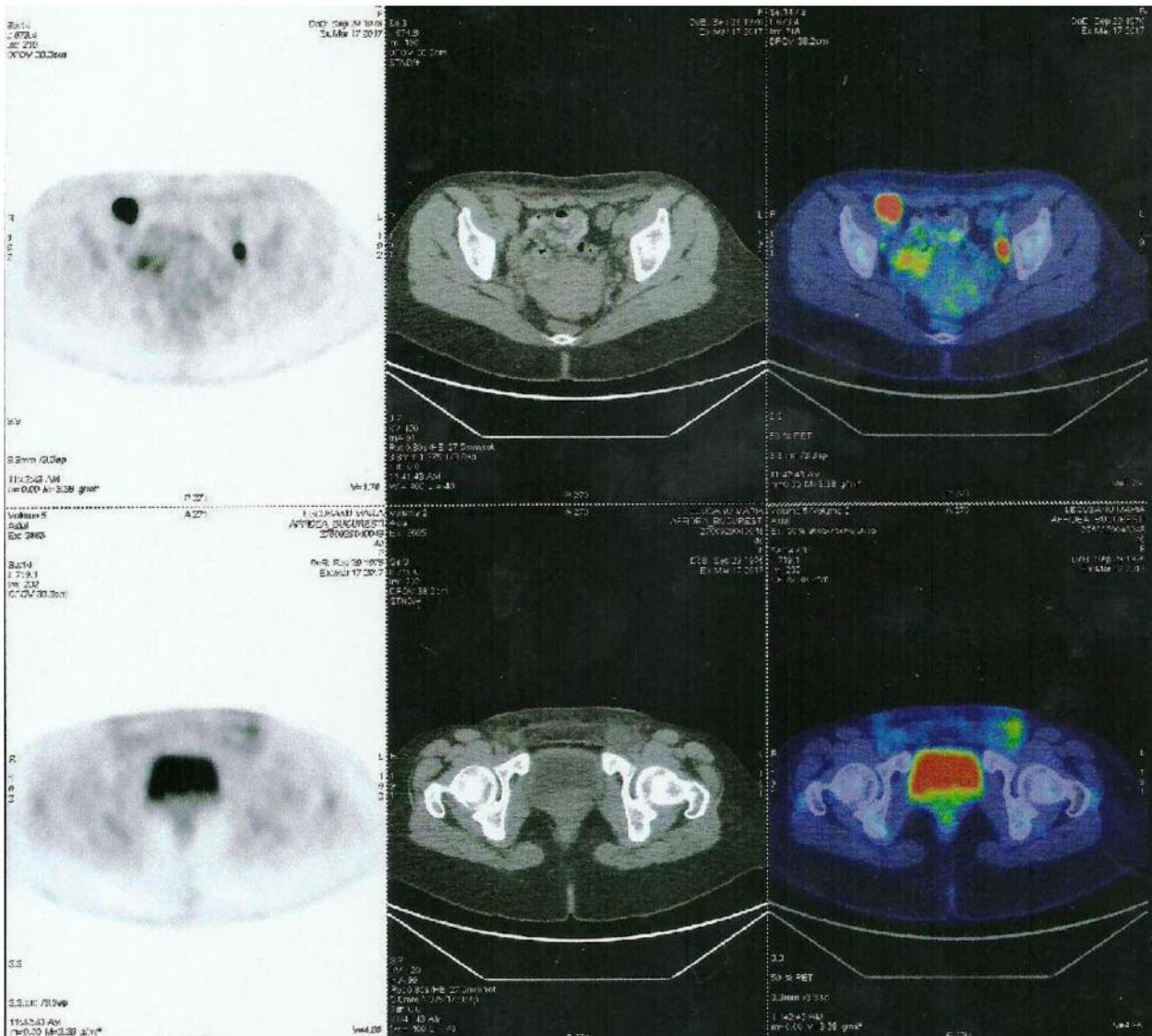


Figure 1. Increased areas of fixation in the adnexal areas and in the areas of the inguinal lymph nodes.

increased level of CA 125 (of 67 UI/ml) without any other modifications. We submitted the patient to surgery, a bilateral adnexectomy being performed. The frozen section confirmed the origin of the tumoral process at the level of the both ovaries, so the patient was submitted to debulking surgery consisting of total hysterectomy, bilateral adnexectomy, omentectomy, peritoneal biopsies, pelvic and para-aortic lymph node dissection, as well as bilateral inguinal lymph node dissection (Figures 2-6). The histopathological studies revealed the presence of lymph node metastases in one pelvic lymph node while all the 18 lymph nodes removed from the inguinal areas presented tumoral deposits. At one-

month follow-up, the CA 125 levels dropped at 28 UI/ml. However, the patient was submitted to six cycles of taxanes and platinum based chemotherapy. At one-year follow-up the patient is free of any recurrent disease.

### Discussion

Ovarian cancer has a high propensity of developing lymph node metastases, the most commonly involved groups being located in the pelvic and para-aortic region, the estimated incidence of such lesions ranging between 14% and 70% (10). Anatomical studies demonstrated that ovarian lymphatic

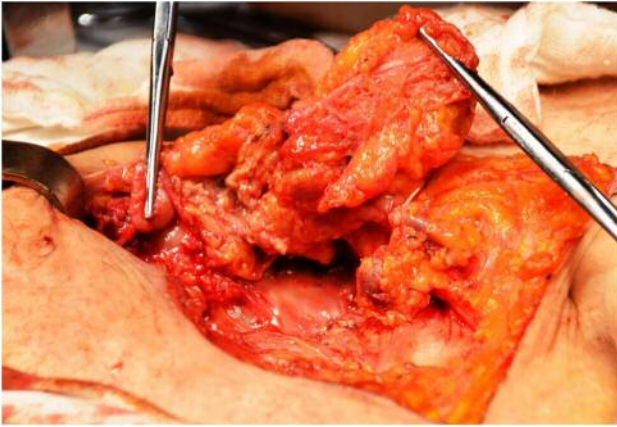


Figure 2. Intraoperative aspect – removal of an inguinal tumoral mass.

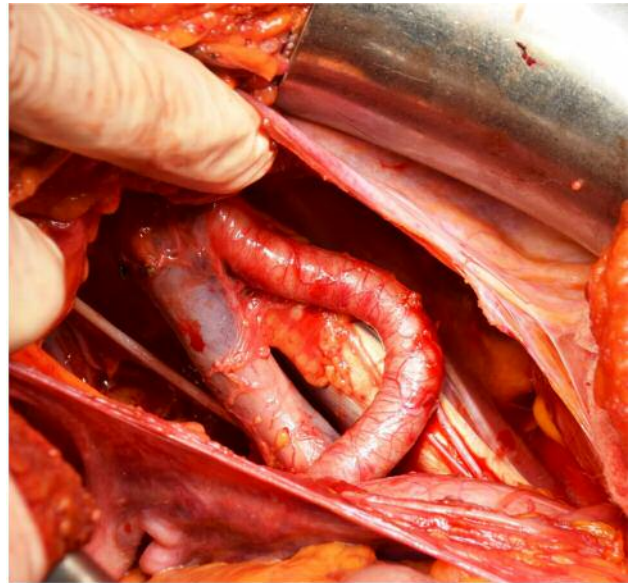


Figure 4. The final aspect of pelvic lymph node dissection.

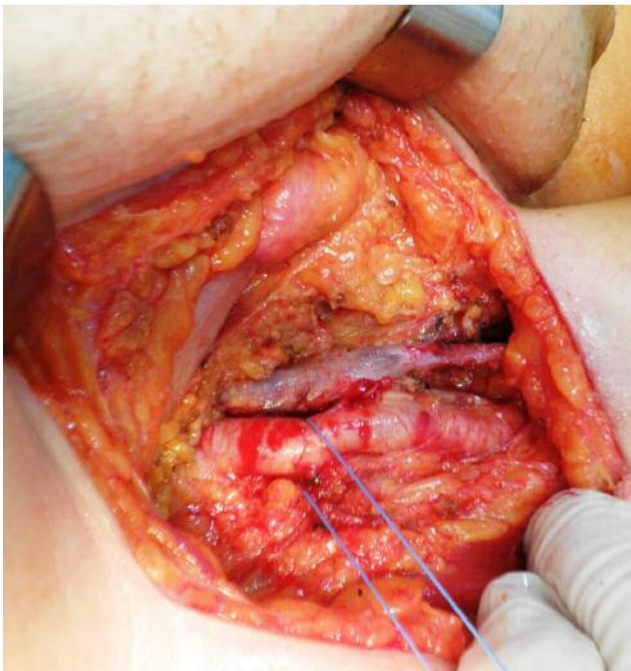


Figure 3. The final aspect after inguinal lymph node dissection.

drainage usually occurs via the infundibulo-pelvic ligament to the para-aortic lymph nodes, and only after blocking these stations occur a retrograde drainage to the inguinal lymph nodes develop (1, 2, 11). However, in our case both the preoperative PET CT and the histological findings demonstrated the presence of a single pelvic lymph node metastasis, this finding couldn't support the theory of lymphatic drainage blocking followed by the retrograde dissemination.

When it comes to the issue of inguinal lymph node metastases with ovarian cancer origin, the reported incidence is less than 3% (9). Therefore, inguinal lymph node dissection is not routinely recommended in ovarian cancer patients even if an advanced stage of the disease is expected.

The main mechanisms of spread of the ovarian tumoral cells in the inguinal lymph nodes involve tumoral dissemination through the round ligaments (12).

As for the preoperative workup which might establish the involvement of the inguinal lymph nodes, it seems that positron emission computed tomography (PET CT) plays a central role. In a similar case which was reported by Mancini *et al.*, a 58-year-old patient who had been initially diagnosed with bilateral groin lymph node metastases, all the performed investigations (including colonoscopy, upper digestive endoscopy, transvaginal ultrasound, endometrial and cervical biopsies and full body computed tomography) failed to demonstrate the origin of these malignant elements; however, the only preoperative investigation which orientated the initial diagnosis was a PET CT study which demonstrated the presence of a high metabolic uptake in the both adnexal and inguinal areas. The patient was submitted to bilateral adnexectomy, the frozen sections confirming the presence of a serous papilliferous bilateral ovarian adenocarcinoma and therefore the intervention was completed by performing a total hysterectomy, omentectomy, pelvic and para-aortic lymph node dissection as well as bilateral inguinal lymph node dissection. Surprisingly, only the inguinal lymph nodes presented tumoral involvement, all the other retrieved lymph



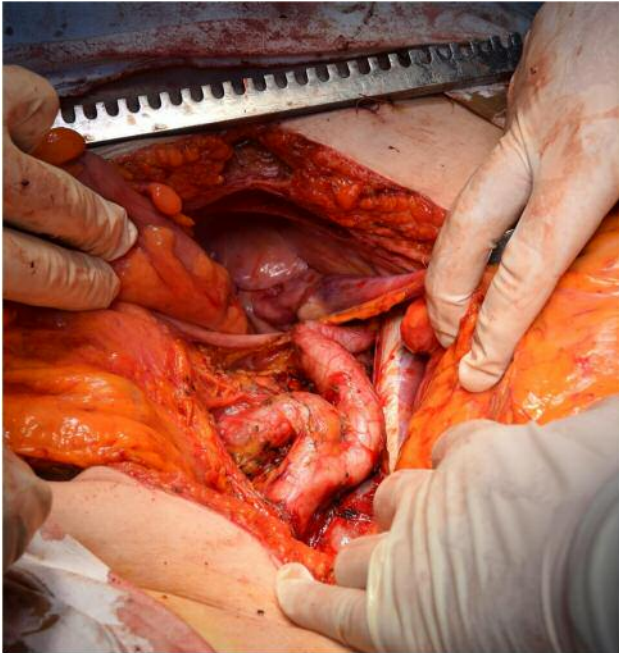


Figure 5. The final aspect – para-aortic lymph node dissection.

nodes (from the pelvic and para-aortic areas) presenting no signs of disease. These data come to demonstrate that in certain cases ovarian cancer can metastasize directly in the inguinal lymph nodes even in the absence of other distant lesions (13).

Another similar finding comes from the Indian authors, who reported the case of a 35-year-old patient who presented for the apparition of an ulcerated tumoral mass in the left inguinal region in the absence of any other modification. However, due to the presence of high levels of CA 125 (of 412 IU/ml) the patient was treated as an ovarian cancer, three cycles of paclitaxel and carboplatin being administrated. This regimen induced a complete regression of the groin mass; however, the patient was submitted to total hysterectomy, bilateral adnexectomy, omentectomy and groin lymph node dissection, the histopathological studies confirming the presence of tumoral cells at the level of the left ovary and left inguinal nodes (14).

In a study conducted in Istanbul, Turkey, Ulker *et al.* investigated the lymphatic pattern of spread on 62 consecutive patients submitted to surgery for epithelial ovarian cancer between January 2003 and February 2013. According to the authors of the study, staging procedures included peritoneal washing, multiple peritoneal biopsies, total hysterectomy with bilateral adnexectomy, appendectomy, omentectomy as well as pelvic and para-aortic lymph node dissection; in this study pelvic lymph node dissection included the common, external, internal

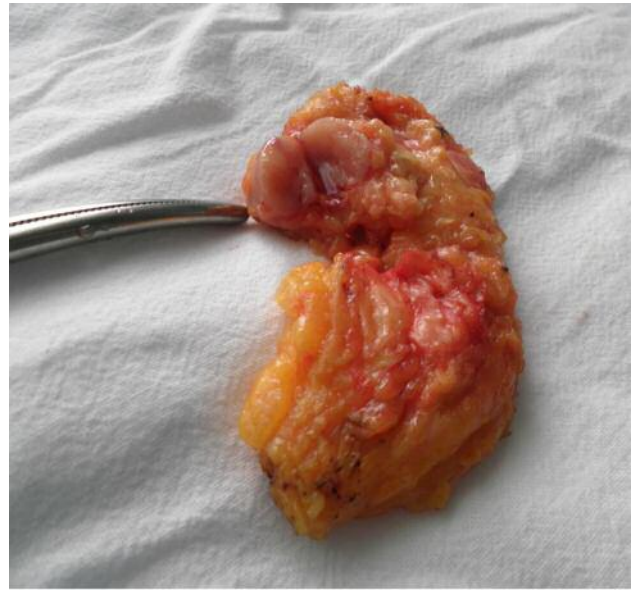

Figure 6. The specimen of inguinal lymph node dissection.

groups but also the lymph nodes at the level of the inguinal ligament, while para-aortic lymph node dissection included the ganglia groups at the level of the great vessels, up to the level of the renal vessels on the both sides. The authors failed to demonstrate the presence of any correlation between the laterality of the ovarian tumor and the involved pelvic and inguinal lymph nodes. However, a significant correlation was established between the positivity of the peritoneal fluid cytology and the presence of lymph node metastases. Moreover, a higher FIGO stage was significantly associated with the risk of lymph node metastases (11).

In a more recent study which was conducted this time in India, the authors reviewed data originating from 324 patients and reported seven cases of ovarian cancer patients presenting inguinal lymph node metastases. In four of the seven cases the presence of groin swelling represented the only symptom at the time of presentation. When it comes to the extent of the disease, only three of the 324 cases presented no adnexal masses and no other distant tumoral masses. Due to the extent of the disease, only two patients were submitted to per-primam cytoreductive surgery while in all other cases neoadjuvant chemotherapy was needed in order to increase the resectability rate. However, the histopathological studies of the two patients submitted to surgery as the first intention therapeutic procedure demonstrated the presence of disseminated metastatic lesions at the level of the peritoneal biopsies as well as at the level of the pelvic, inguinal and para-aortic removed lymph nodes,

demonstrating in this way that the contamination of the inguinal lymph nodes usually occur as part of the systemic development of this malignancy (15).

Another interesting aspect of the case that we present is the fact that both ovaries were normal sized and presented no macroscopic signs of tumoral development, only the PET-CT demonstrating the presence of bilateral fixation. This phenomenon is called “normal size ovary carcinoma syndrome” and has been reported in only 1% of all patients diagnosed with ovarian cancer (16-18).

## Conclusion

The presence of isolated lymph node metastases in patients with ovarian cancer is a rare event, only few cases being reported so far. Most often tumoral invasion at this level occurs via the round ligament in a retrograde route which is induced by the tumoral occlusion of the pelvic and para-aortic lymph nodes. Moreover, the development of isolated inguinal lymph node metastases in a patient with normal size ovaries is even scarcer. However, ovarian cancer should not be omitted from the list of the differential diagnosis in patients with isolated inguinal tumoral masses especially if these are associated with higher preoperative levels of CA 125.

## References

- Bacalbasa N, Balescu I, Dima S and Popescu I: Long-term Survivors After Liver Resection for Ovarian Cancer Liver Metastases. *Anticancer Res* 35: 6919-6923, 2015.
- Bristow RE, Tomacruz RS, Armstrong DK, Trimble EL and Montz FJ: Survival effect of maximal cytoreductive surgery for advanced ovarian carcinoma during the platinum era: a meta-analysis. *J Clin Oncol* 20: 1248-1259, 2002.
- Bacalbasa N, Balescu I, Dima S, Brasoveanu V and Popescu I: Splenectomy as part of cytoreductive surgery in recurrent epithelial ovarian cancer. *Anticancer Res* 35: 5097-5101, 2015.
- Bacalbasa N, Balescu I, Dima S, Brasoveanu V and Popescu I: Pancreatic resection as part of cytoreductive surgery in advanced-stage and recurrent epithelial ovarian cancer – A single-center experience. *Anticancer Res* 35: 4125-4129, 2015.
- Bacalbasa N, Dima S, Balescu I, David L, Brasoveanu V and Popescu I: Results of primary cytoreductive surgery in advanced-stage epithelial ovarian cancer: A single-center experience. *Anticancer Res* 35: 4099-4104, 2015.
- Bacalbasa N, Balescu I, Dima S, Herlea V, David L, Brasoveanu V and Popescu I: Initial incomplete surgery modifies prognosis in advanced ovarian cancer regardless of subsequent management. *Anticancer Res* 35: 2315-2320, 2015.
- Bacalbasa N, Dima S, Brasoveanu V, David L, Balescu I, Purnichescu-Purtan R and Popescu I: Liver resection for ovarian cancer liver metastases as part of cytoreductive surgery is safe and may bring survival benefit. *World J Surg Oncol* 13: 235, 2015.
- Bacalbasa N, Balescu I, Dima S, Brasoveanu V and Popescu I: Hematogenous splenic metastases as an independent negative prognosis factor at the moment of primary cytoreduction in advanced stage epithelial ovarian cancer – a single center experience. *Anticancer Res* 35: 5649-5654, 2015.
- Rose PG, Piver MS, Tsukada Y and Lau TS: Metastatic patterns in histologic variants of ovarian cancer. An autopsy study. *Cancer* 64: 1508-1513, 1989.
- Panici PB and Angioli R: Role of lymphadenectomy in ovarian cancer. *Best Pract Res Clin Obstet Gynaecol* 16: 529-551, 2002.
- Ulker V, Kuru O, Numanoglu C, Akbayir O, Polat I and Uhri M: Lymph node metastasis in patients with epithelial ovarian cancer macroscopically confined to the ovary: review of a single-institution experience. *Arch Gynecol Obstet* 289: 1087-1092, 2014.
- Metwally IH, Zuhdy M, Hassan A, Alghandour R and Megahed N: Ovarian cancer with metastatic inguinal lymphadenopathy: A case series and literature review. *J Egypt Natl Canc Inst* 29: 109-114, 2017.
- Manci N, Bellati F, Graziano M, Pernice M, Muzii L, Angioli R and Benedetti PP: Ovarian cancer, diagnosed with PET, with bilateral inguinal lymphadenopathy as primary presenting sign. *Gynecol Oncol* 100: 621-622, 2006.
- Deka P, Shrivastava S, Barmon D, Katakaki AC and Sarma A: Ovarian carcinoma in normal size ovaries with inguinal lymph node metastasis: a case report. *Cancer Ther Res* 2: 3, 2013.
- Giri S, Shah SH, Batra K, Anu B, Jain V, Shukla H, Sekhon R and Rawal S: Presentation and management of inguinal lymphadenopathy in ovarian cancer. *Indian J Surg Oncol* 7: 436-440, 2016.
- Scholz HS, Lax S, Tamussino KF and Petru E: Inguinal lymph node metastasis as the only manifestation of lymphatic spread in ovarian cancer: A case report. *Gynecol Oncol* 75: 517-518, 1999.
- Feuer GA, Shevchuk M and Calanog A: Normal-sized ovary carcinoma syndrome. *Obstet Gynecol* 73: 786-792, 1989.
- Berek JS and Hacker NF: *Practical Gynecologic Oncology*. Lippincott Williams and Wilkins (3rd ed.), Philadelphia, pp. 466-467, 1994.

*Received November 27, 2017*

*Revised December 13, 2017*

*Accepted December 14, 2017*