

Surgical Solutions for the Reconstruction of the Lower Eyelid: Canthotomy and Lateral Cantholysis for Full-thickness Reconstruction of the Lower Eyelid

GIAN MARCO TOMASSINI¹, ANGELA LUISA RICCI², PIERO COVARELLI³, FRANCESCA CENCETTI¹, VINCENZO ANSIDEI¹, ANTONIO RULLI³ and STEFANO SIMONETTI¹

Section of ¹Dermatology, ²Ophthalmology and ³Department of Surgery, Perugia General Hospital, University of Perugia, Perugia, Italy

Abstract. *The lower eyelid is the most common site of tumors of the orbital region, usually of basocellular skin carcinoma, whose incidence is increasing with population aging in Western countries. The treatment must achieve the complete removal of the neoplasm in order to prevent recurrences, thus requiring eyelid and periocular reconstruction. Several techniques are described for eyelid defect reconstruction, aiming for direct suture eased by flaps, or considering the use of grafts. We report our experience with 22 patients operated on for basocellular carcinoma of the lower eyelid, for which defects were repaired by means of a full-thickness reconstruction using a canthotomy and lateral cantholysis; in 13 patients the canthotomy was combined with a lateral-canthal flap. We achieved good results in terms of orbital function and aesthetic outcome, as long as radical removal of the tumor without local recurrences was attainable.*

The lower eyelid is the most common site of tumors of the orbital region, both for direct involvement, and for extension of the tumor from the surrounding areas, cheeks and zygomatic bone.

The basic rule in tumor surgery of the eyelids is to ensure radical excision, even when such treatment involves the sacrifice of several components of the eyelid and neighboring structures, since inadequate excision could lead to a high rate of recurrence (1).

The reconstruction comprises a variety of techniques including direct suture, grafts (skin and compounds), skin flaps and muscular or multitissular flaps (2). The choice of one

technique alone, or the simultaneous use of different techniques, depends on the extension, localization and infiltration of the tumor. The objectives of eyelid reconstruction are to restore the eyelid structure and function with an acceptable cosmetic result (3). To achieve these goals, a thorough understanding of eyelid anatomy and a good knowledge of the different reconstructive options are necessary.

We present our single-center experience, based on a multidisciplinary cooperation between different specialists working at the Perugia General Hospital.

Patients and Methods

Patients. From January 1997 to March 2012, we treated 28 patients affected by lower eyelid neoplasms. We excluded from this study six cases where complete eyelid restoration was obtained with a venous graft, as described in another article (4). Therefore we selected 22 cases (Table I), whose age ranged from 67 to 92 years (average 77.5 years), 13 women and 9 men. They all were affected by basocellular skin neoplasms of the lower eyelid.

Methods. We always removed the tumor with a radical intent, but also with a functional aim to the reconstructive project; the lines of incision and suture were conducted along the Langer's lines to reduce tension and to improve the aesthetic result (5). Another point to be considered is that the shape, contour, height and mobility of the eyelid tissue, that define the palpebral fissure, must provide adequate eye protection (1): the widest horizontal interpalpebral distance usually ranges from 28 to 30 mm, and the maximum vertical interpalpebral distance ranges from 9 to 12 mm.

If the tumor, even if small, infiltrates and extends to the free margin, we usually perform a full-thickness excision. In these cases, when the loss of substance is centrally located and it is equal or inferior to one quarter of the eyelid width, we affix thin silk stitches in the tarsal margin to attempt, when possible, a tension-free closure for direct approximation. When the loss of substance is greater (more than 10 mm), in order to obtain tension-free sutures, we medially mobilize the eyelid by the means of an external canthotomy.

Surgical technique. The procedure is performed through an incision in the lateral palpebral fissure with a horizontal cut extending from the lateral canthus to the orbital margin, wide enough to expose the

This article is freely accessible online.

Correspondence to: Dr. Piero Covarelli, Via degli Olivi 18, 06123, Perugia, Italy. Tel: +39 075 5783485, Fax: +39 0755783258, e-mail: piero.covarelli@med.unipg.it

Key Words: Eyelid reconstruction, eyelid tumor, periocular flap, canthotomy.

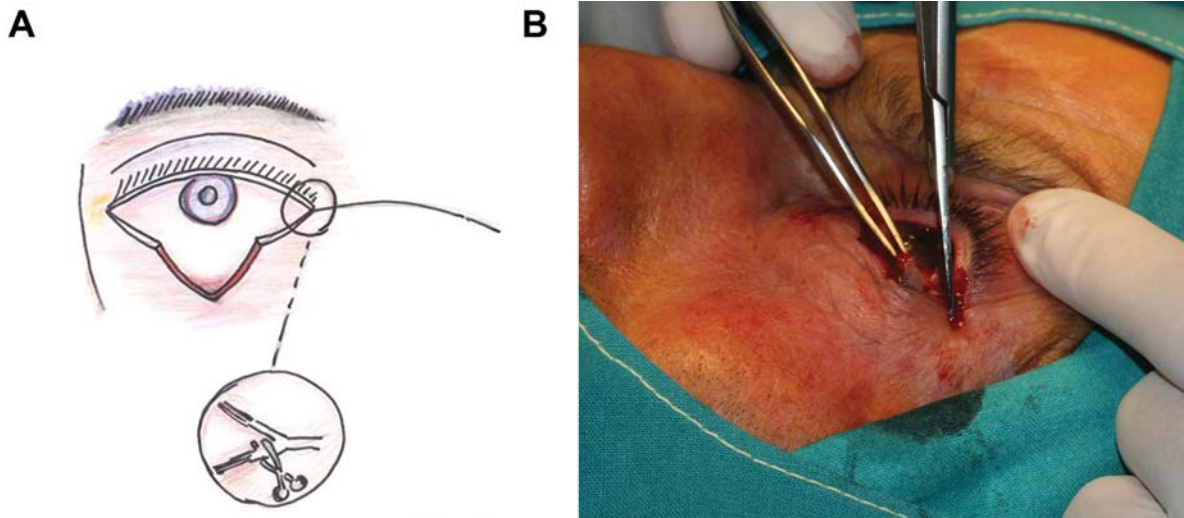


Figure 1. A: The surgical operation layout. B: Performance of the canthotomy.

Table I. Basic patient characteristics.

Gender	Age (years)	Eye	Follow-up (months)
Female	67	R	180
Male	80	R	143
Female	75	L	137
Female	71	R	125
Female	68	R	120
Female	80	L	102
Male	77	R	97
Male	72	L	84
Female	85	L	66
Male	88	R	54
Male	74	R	49
Female	79	L	48
Male	73	R	44
Male	80	L	40
Female	78	L	37
Female	73	L	27
Female	67	R	24
Male	77	L	20
Female	87	R	14
Male	91	L	8
Female	92	R	8
Female	71	L	6

R: Right; L: left.

upper and the lower limbs of the lateral canthal tendon (6). With gentle medial traction of the lid, the inferior limb can be recognized as a band located posteriorly to the orbicularis muscle. The skin and the orbicularis muscle can be isolated from the lower limb by spreading scissors; the conjunctiva is also separated from the limb and the branch is finally divided, obtaining cantholysis of the infero-lateral tendon of the canthus, thus releasing the lateral part of the

eyelid in order to directly close the defect (Figure 1). This procedure allows full-thickness defect covering since the lateral fornical conjunctiva rotates together with the lower eyelid when it moves medially to close.

When lateral canthotomy with cantholysis does not allow the closure, it may be necessary to mobilize larger flaps, such as the so-called Mc Gregor temporal flap (6, 7). This is created by a curved incision which extends beyond the canthal region to the edge of the tail of the eyebrow leading to the auricle. The flap can be anchored in the deep layers and then sutured to the margins of the loss of substance; it is associated with Z-shaped plastic at the lateral edge of the flap to reduce the tension and is also frequently used for upper eyelid reconstruction; a clinical case is shown in Figure 2.

The procedure is somewhat an extension into the temporal area using an older reconstructive technique, that is the semicircular flap, described in 1975 by Tenzel (6, 8, 9); this is a semicircular advancement flap on the lateral canthal region combined with an infero-lateral canthotomy to reconstruct defects of the central lower eyelid, involving up to 50% of the length of the lid. The flap is designed in such a way that the incision begins at the lateral canthus and the curves proceed superiorly and temporally in a semicircular shape. The actual incision is not exactly semi-circular, but usually extends more horizontally than vertically. The incision extends to the lateral canthal ligament to create a flap of skin and muscle that can be advanced medially to directly close the defect. The lateral canthus is reconstructed using a direct suture; a clinical case is shown in Figure 3.

We decided to perform reconstruction based on a venous and cutaneous graft in six patients presenting a full-thickness wider defect of the lower eyelid following a tumoral removal, as described elsewhere (4).

Results

We treated 22 patients in 15 years; they all were elderly patients, with an average age of 77.5 years. None of our patients had an orbital involvement requiring an exenteration; we never used radiotherapy, nor adjuvant or neo-adjuvant therapy.

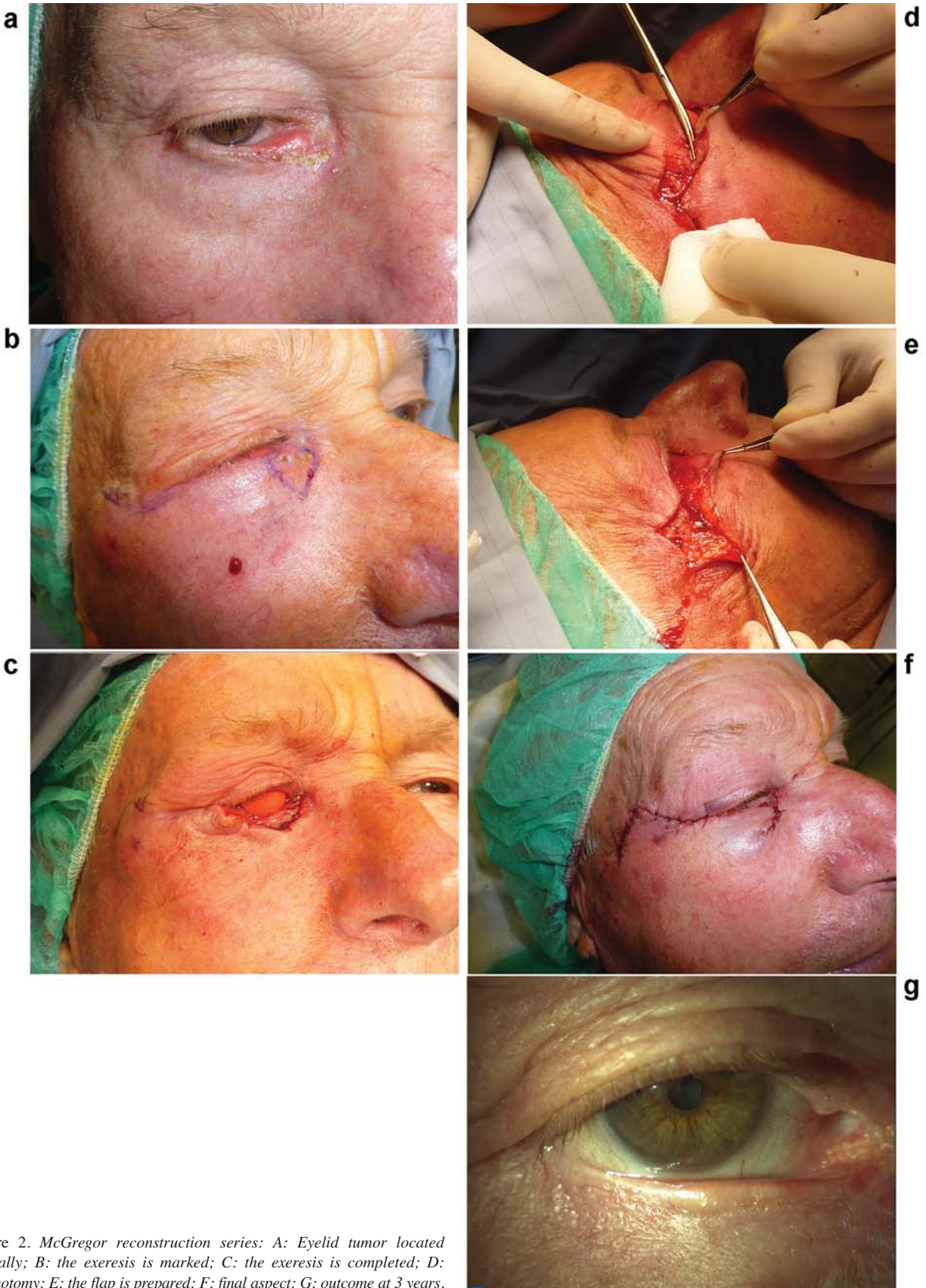

Figure 2. McGregor reconstruction series: A: Eyelid tumor located medially; B: the exeresis is marked; C: the exeresis is completed; D: canthotomy; E: the flap is prepared; F: final aspect; G: outcome at 3 years.

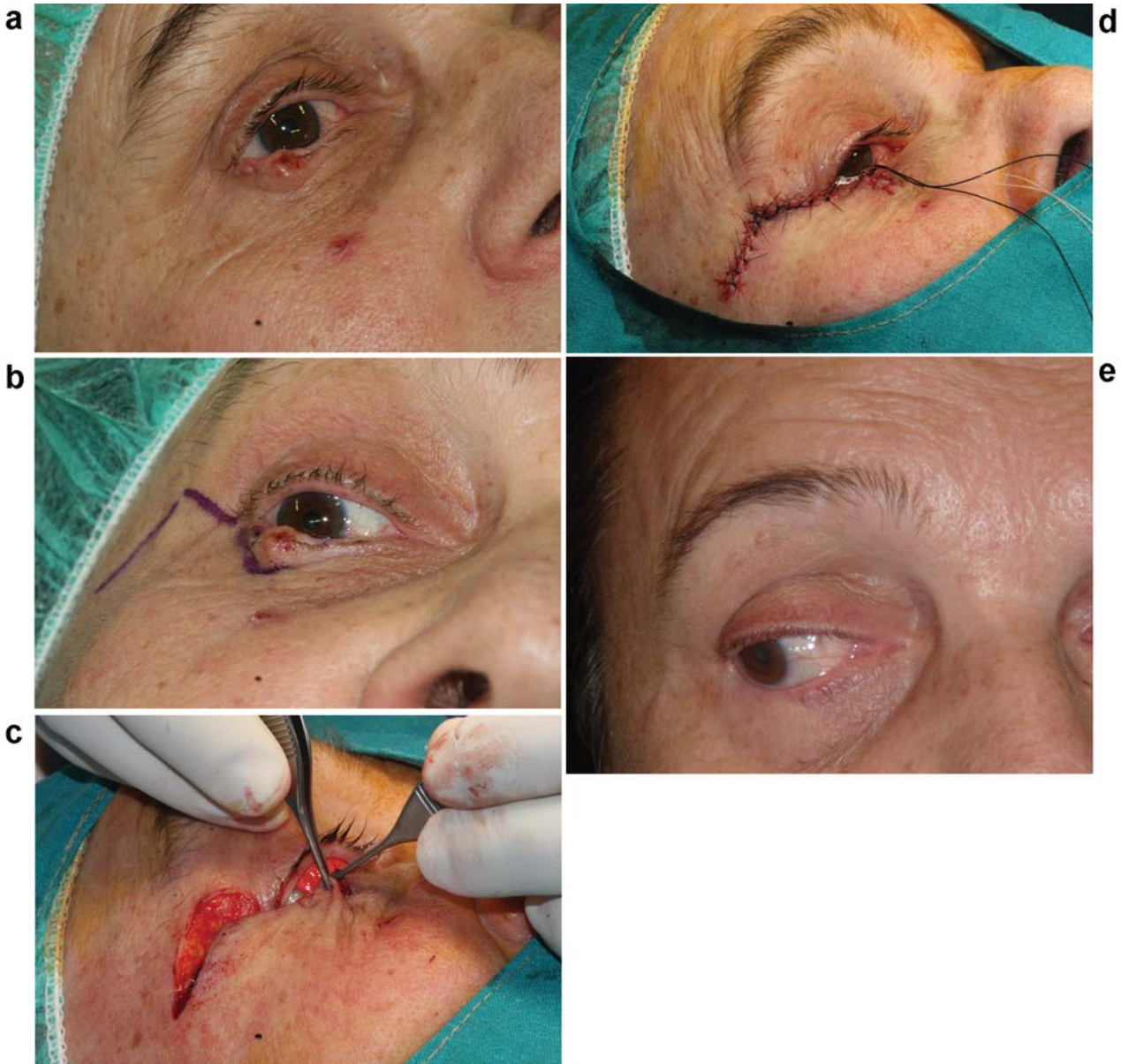

Figure 3. Tenzel reconstruction series: A: Eyelid tumor centrally located; B: incision lines are marked; C: flap advancement with suture of defect; D: final aspect; E: outcome at 3 years.

We were able to reconstruct the defect with the sole canthotomy in nine cases, where the loss of substance then allowed a tension-free closure, moving the mobile full-thickness eyelid flap created by the tendon branch division medially.

In 13 patients, the canthotomy alone was not enough to repair the loss of substance; therefore we also accomplished a Tenzel procedure in six cases, while in the remaining seven patients a McGregor flap was used.

We did not record any tumoral recurrence or cancer-related mortality, with a follow-up ranging from 6 to 180 months.

Good bulbar covering was always obtained; thus a second operation was never required, both considering the ocular protection and the patient's degree of satisfaction with the aesthetic result.

Discussion

Basocellular skin carcinoma is the most common skin cancer of the eyelid, whose incidence is increasing in Western countries, according to population aging (10). Although tumor-related mortality is low (11), the treatment must obtain the

complete removal of the neoplasm in order to prevent recurrences (1); this aggressive approach can lead to significant morbidity (1, 11).

The management of the tumor requires a multidisciplinary approach, especially when dealing with large tumors with or without orbital invasion. Orbital invasion usually demands an exenteration, followed in some cases by radiotherapy (10), the latter being an appropriate option for patients with residual inoperable tumors or when surgical margins are not disease-free. In our selected series, no patient underwent exenteration, nor received adjuvant radiation therapy.

The need for a radical excision of the tumor can frequently cause wide defects, requiring eyelid and periocular reconstructions (1); thus reconstruction procedures have evolved and good results can be expected with the combined use of different techniques (12).

In eyelid reconstruction, surgeons should be aware of some basic rules now codified, as for example placing the suture knots on the cutaneous side in order to reduce corneal irritation. The postoperative irritation in these patients is however frequent, given the rich vascularization of the area (12, 13); however the rich vascular supply usually grants good postoperative healing (3).

The full thickness loss of tissue not exceeding one quarter of the length of the eyelid, can sometimes be closed for direct approximation by juxtaposition of layers (mucosa, mucular layer, skin), while losses of substance greater than 25% of the eyelid length usually require a tissular graft and/or a flap. We believe that flaps have a greater and faster possibility of healing than grafts, given their own blood supply; skin flaps, for example, are usually less restrictive postoperatively than skin grafts (5).

The full-thickness reconstruction of the eyelid demands the restoration of two distinct layers having different anatomy and function, namely the external musculocutaneous layer and the internal tarsal and conjunctival layer. Other than the functional restoration, in eyelid reconstruction, the cosmetic results must be considered. For a better aesthetic outcome, it is important to make the incisions along Langer's skin lines whenever possible, and to consider the optical symmetry (3).

In selected cases with wide eyelid defects, we chose a full-thickness reconstruction with a graft of a wall segment of a propulsive vein (saphenous vein), combined with skin covering (4, 14); this procedure does not present major technical difficulties and can lead to excellent aesthetic and functional outcomes, but it can lead to a few complications, it is also time-consuming and the patient cannot expect fast healing.

For this reason, in the majority of our patients, whenever the local tension did not allow a direct approximation, we performed a lateral canthotomy through a 5-mm skin incision and cross section of the lower branch of the lateral canthal ligament, thus creating a mobile full-thickness eyelid flap which we were able to move medially enough to repair the loss of substance. Whenever presented with defects equal to or greater

than half of the eyelid width, larger flaps need to be mobilized; in our experience, the Mc Gregor flap and the Tenzel semicircular flap are the best solutions to adopt.

Conclusion

Several surgical techniques have been used for the reconstruction of the lower eyelid when presented with full-thickness defects due to the removal of infiltrating tumors. According to our experience, a satisfactory local mobilization can be obtained by the means of canthotomy, frequently combined with advancement flaps; this represents a one-step and elegant procedure, combining excellent oncological radicality with good aesthetic and functional results.

References

- 1 Nemet AY, Deckel Y, Martin PA, Kourt G, Chilov M, Sharma V and Benger R: Management of periocular basal and squamous cell carcinoma: A series of 485 cases. *Am J Ophthalmol* 142(2): 293-297, 2006.
- 2 Harris GJ and Garcia GH: Advancement flaps for large defects of the eyebrow, glabella, forehead and temple. *Ophthalm Plast Reconstr Surg* 18: 138-145, 2002.
- 3 Sharma V, Benger R and Martin PA: Techniques of periocular reconstruction. *Indian J Ophthalmol* 54: 149-158, 2006.
- 4 Tomassini GM, Ansidei V, Ricci AL, Cagini C, Cencetti F, Simonetti S and Covarelli P: Venous graft for reconstruction of neoplastic and post-traumatic eyelid defects. *In Vivo* 26(3): 447-451, 2012.
- 5 Patrinely JR, Marines HM and Anderson RL: Skin flaps in periorbital reconstruction. *Surv Ophthalmol* 31: 249-261, 1987.
- 6 Tyers AG, Collin JRO: *Colour Atlas of Ophthalmic Plastic Surgery*. Butterworth Heinemann, Boston, Ma, USA, 2008.
- 7 Khan JA and Garden VS: Combined flap repair of moderate lower eyelid defects. *Ophthalm Plast Reconstr Surg* 18: 202-204, 2002.
- 8 Tenzel RR: Reconstruction of the central one half of an eyelid. *Arch Ophthalmol* 93(2): 125-126, 1975.
- 9 Tenzel RR and Stewart WB: Eyelid reconstruction by the semicircle flap technique. *Ophthalmology* 85: 1164-1169, 1978.
- 10 Iuliano A, Strianese D, Uccello G, Diplomato A, Tebaldi S and Bonavolontà G: Risk factors for orbital exenteration in periocular basal cell carcinoma. *Am J Ophthalmol* 153(2): 238-241, 2012.
- 11 Cook BE Jr. and Bartley GB: Epidemiologic characteristics and clinical course of patients with malignant eyelid tumors in an incidence cohort in Olmsted County, Minnesota. *Ophthalmology* 106(4): 746-750, 1999.
- 12 Codner MA, McCord CD, Mejia JD and Lalonde D: Upper and lower eyelid reconstruction. *Plast Reconstr Surg* 126(5): 231e-245e, 2010.
- 13 Subramanian N: Reconstructions of eyelid defects. *Indian J Plast Surg* 44(1): 5-13, 2011.
- 14 Barbera C, Manzoni R, Dodaro L, Ferraro M and Pella P: Reconstruction of the tarsus-conjunctival layer using a venous wall graft. *Ophthalm Plast Reconstr Surg* 24(5): 352-356, 2008.

Received September 29, 2012

Revised October 24, 2012

Accepted October 26, 2012