

# Absence of Cytomegalovirus from the Gastrointestinal Tract of Patients with Active Crohn's Disease

MARKKU T. AARNIO<sup>1</sup>, JAN P. BÖHM<sup>2</sup>, KYÖSTI P. NUORVA<sup>2</sup>, REINO I. PITKÄNEN<sup>2</sup>,  
TEIJO H. KUOPIO<sup>2</sup> and MARKKU E. VOUTILAINEN<sup>3</sup>

Departments of <sup>1</sup>Gastroenterological Surgery, <sup>2</sup>Pathology and  
<sup>3</sup>Internal Medicine, Jyväskylä Central Hospital, Finland

**Abstract.** *Background:* Cytomegalovirus (CMV) infection reportedly is detectable in the gastrointestinal mucosa of patients with chronic inflammatory bowel disease. One view is that CMV infection is of clinical significance in patients with Crohn's disease with severe colitis not responding to steroid therapy. In this study, we evaluated the prevalence of CMV infection in our own patients with Crohn's disease treated with colon resection. *Patients and Methods:* The study included 16 consecutive patients with Crohn's disease with colitis who underwent surgery for colonic disease. *Histology and immunohistochemistry* were used to examine the CMV infection in their surgical specimens by means of enzymatic antigen retrieval, mouse monoclonal antibody, clone CMV01, and a sensitive polymer detection system. *Results:* All 16 patients underwent colon resection, three of them undergoing emergency surgery. No CMV infection was found in their surgical specimens. *Conclusion:* CMV infection seems not to play a major role in the pathogenesis of Crohn's colitis requiring surgery. However, further prospective studies with larger number of patients are needed to determine the role of CMV in active Crohn's colitis.

Cytomegalovirus (CMV), belonging to the herpesvirus family, infects 40% to 100% of the adult population worldwide (1). CMV infection may be latent, but its diagnosis requires the presence of clinical signs and symptoms of infectious disease (fever, leucopenia) and detection of end-organ involvement (1). CMV colitis is usually detected in recipients of allograft transplantation and AIDS patients, but it may reportedly also cause colitis in

previously healthy immunocompetent persons (2). Some studies suggest that CMV may also be involved in pathogenesis of refractory and complicated inflammatory bowel disease (IBD) (3-5). CMV has reportedly occurred in ileal and colonic mucosa of patients with active ileocolonic Crohn's disease (6, 7).

In the treatment of complicated Crohn's disease, surgery plays a significant role (8). About 30% of patients with Crohn's disease of our hospital referral area have undergone surgery (9). It has been suggested, however, that antiviral treatment of CMV infection in Crohn's colitis can diminish the need for surgery (10). At present, only a few studies of Crohn's colitis relate to CMV.

The aim of the present study was to determine the prevalence of CMV infection in the intestinal mucosa of patients with Crohn's disease who underwent colon resection.

## Patients and Methods

*Patients.* Representative samples of surgical resections came from 16 consecutive patients with Crohn's colitis treated and followed up between 1995 and 2009 in Jyväskylä Central Hospital.

*Histological specimens.* Tissue specimens from colon resections were fixed in 10% buffered formalin and processed to paraffin. Five-micrometre sections were deparaffinized and stained with haematoxylin-eosin for histological diagnosis. Two experienced histopathologists (J.B. and K.N.) re-examined all original tissue sections, blinded to all clinical data.

The activity of inflammation (proportion of neutrophils) was noted as no activity/weak, moderate, strong. Granulomas were also noted (Figure 1).

*Immunohistochemistry.* The presence or absence of CMV antigen was studied by immunohistochemistry. Each glass slide contained a 5-µm section of a colon specimen from a patient and a CMV-positive control section. Lung tissue of a CMV pneumonia in an immunocompromised patient was used as a positive control. Sections were deparaffinized, rehydrated with graded ethanol, and washed briefly in purified water. The sections were washed with phosphate-buffered saline (PBS) for 5 min at room temperature and for 5 min at 37°C. Antigen retrieval was performed by pepsin

*Correspondence to:* Markku Aarnio, Department of Gastroenterological Surgery, Jyväskylä Central Hospital, Keskussairaalanatie 19, FIN-40620 Jyväskylä, Finland. Tel: +358 142693075, e-mail: markku.aarnio@ksshp.fi

*Key Words:* Crohn's disease, cytomegalovirus infection, immunohistochemistry, surgery.

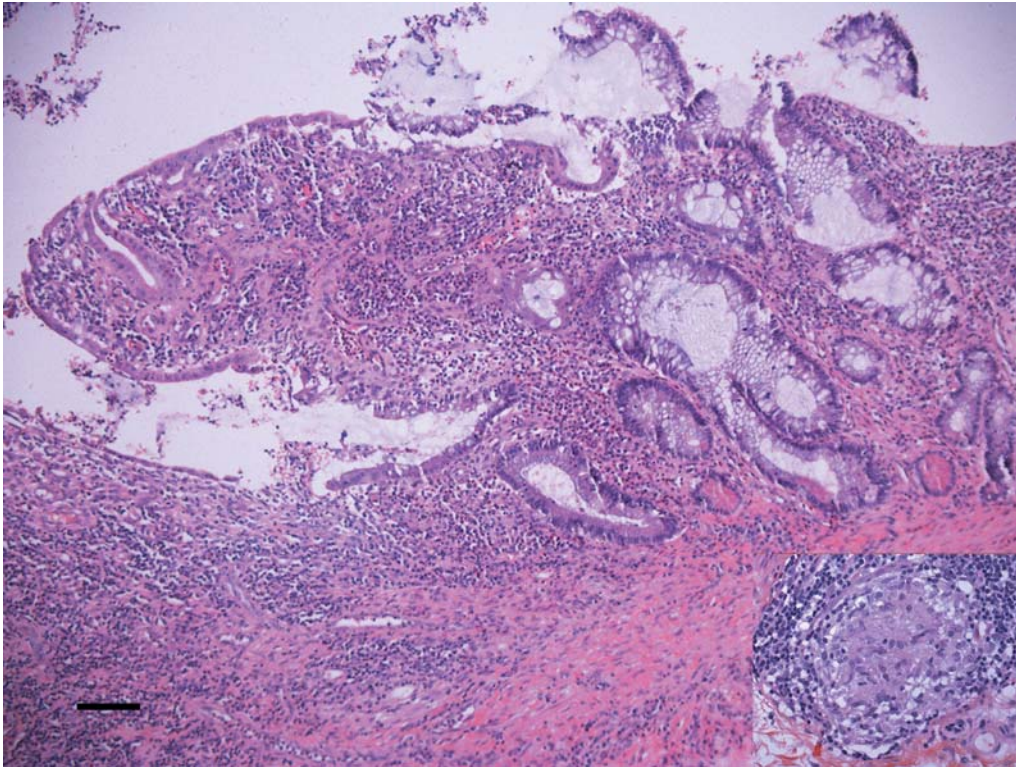


Figure 1. Colon mucosa with chronic active inflammation. The crypts are dilated, and loss of glandular structures is noted, as well as inflammatory cell infiltrate. Epithelioid cell granulomas were also seen (inset). Bar=100  $\mu$ m.

digestion: 0.4% pepsin (Merck 1.07190, 2000 FIP-u/g, Darmstadt, Germany) at 37°C for 30 min. Digestion was stopped in PBS at room temperature. Immunoperoxidase staining of CMV was carried out on an automatic immunostainer Lab Vision Autostainer 480 and mouse monoclonal antibody, clone CMV01 (Thermo Fisher Scientific, Fremont, USA). Sections were dampened in PBS with 0.05% Tween 20, and endogenous peroxidase activity was blocked by 3% hydrogen peroxide in purified water. The PowerVision+ Detection System (ImmunoVision Technologies, Co., Burlingame, CA, USA) served for the detection of antibody. This procedure consists of pre-antibody blocking for 10 min, primary antibody at a dilution of 1:100, and incubation for 60 min, washing twice with PBS for 5 min, post-antibody blocking for 10 min, washing twice with PBS for 5 min, polyHRP (peroxidase-anti-mouse/Rabbit IgG) for 30 min, washing twice with PBS for 5 min, and 3,3'-diaminobenzidine tetrahydrochloride (DAB) for 10 min. Finally, sections were counter stained lightly with haematoxylin, dehydrated, and coverslipped. All positive control sections exhibited CMV-positive cells (Figure 2).

## Results

The study population of 16 patients (eight of each gender) were of a mean age of 30.6 years (95% CI = 22.6-38.5 years) at their Crohn's diagnosis and 38.8 years (95% CI=31.7-45.8 years) at the time of surgery. The mean time from

diagnosis of Crohn's disease to surgery was 7.6 years (95% CI = 2.6-12.6 years). Before surgery, 14 patients had taken 5-aminosalicylic acid, 13 steroids, 12 azathioprine, 3 methotrexate, 8 anti-tumournecrosis factor (TNF)-alpha inhibitor, and 11 antibiotics.

Indications for surgery were acute abdominal pain (2 patients); failure of medical treatment (1); obstructive symptoms or colonic stricture or both (7); perforation (1); abscess (1); fistulae (1); simultaneous obstruction and abscess (3). In all, five patients had colonic, four ileocolonic, and seven patients colorectal Crohn's disease. Thirteen patients underwent elective surgery, and three had emergency surgery. The surgical procedures were as follows: ileocolonic resection (1), ileocolonic and sigmoid resection (3), right-sided hemicolectomy (3), left-sided hemicolectomy (2), left-sided hemicolectomy and proctectomy (2), colectomy (3), proctocolectomy (1) and proctectomy (1).

In immunohistochemistry, no CMV antigen was detectable in any of the surgical specimens (Figure 3). Moderate or strong inflammatory activity was detectable in 14 specimens, and in two the activity was mild or absent. For nine patients, histopathological examination revealed granulomas.



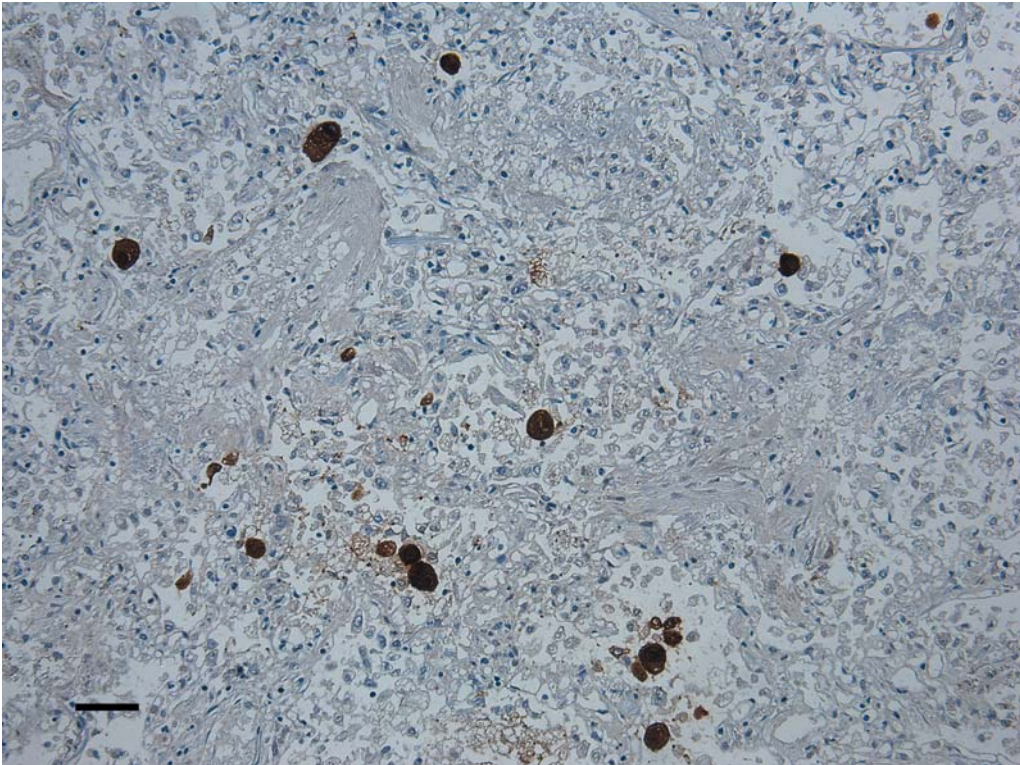


Figure 2. *Positive control of CMV immunostaining (lung). Bar=80  $\mu$ m.*

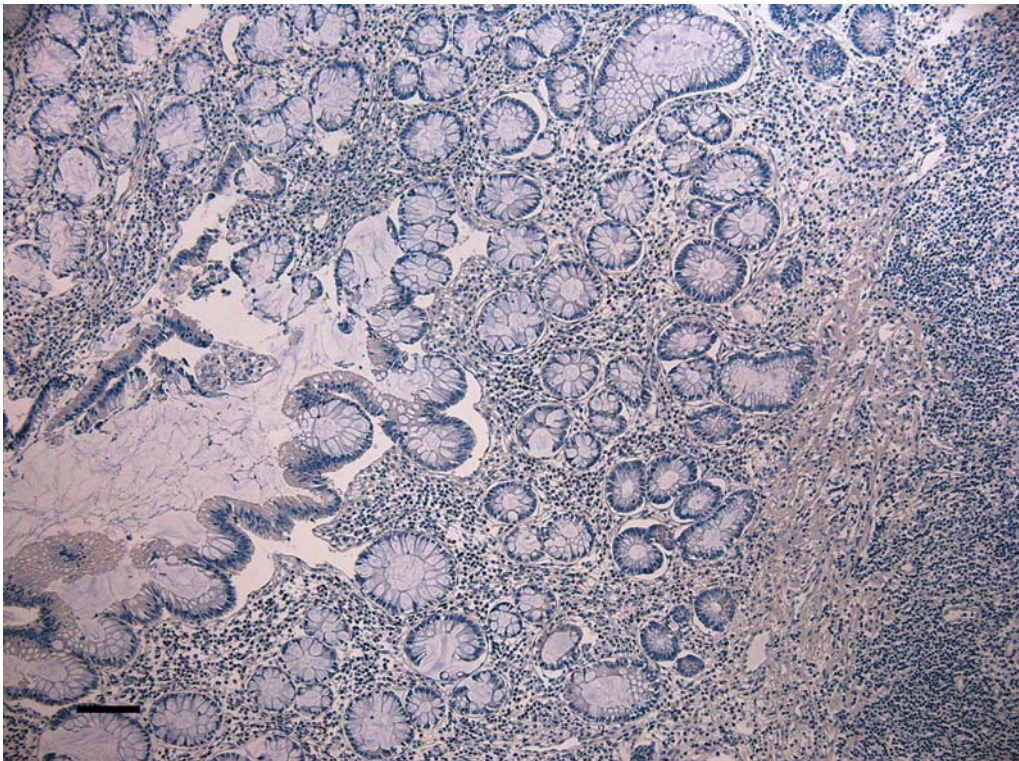


Figure 3. *No positivity was seen using CMV immunohistochemical staining. Bar=100  $\mu$ m.*



## Discussion

Theoretically in patients with Crohn's disease CMV could be an opportunistic infection or a true pathogen causing flare-ups and complications. CMV has been detected more often in patients with steroid-refractory cases of chronic IBD (4, 5, 11). Crohn's disease itself, malnutrition, and advanced age, as well as immunosuppressive therapy with or without leucopenia, are possible risk factors for CMV-infection (12).

We did not detect a single CMV-positive case among the patients with Crohn's disease who underwent surgery. The major limitation of the present study is that it was a retrospective analysis with a small number of patients. Due to the small number of patients, we cannot exclude the possibility there may be a proportion of the patients in whom CMV activates Crohn's colitis. On the other hand, all patients in the present study had Crohn's colitis diagnosed by endoscopy and histology which has been the case in only a few earlier studies. Our results are concordant with a report from France showing, by real-time PCR assay, no correlation between severity of IBD and CMV viral load (13). In histopathological specimens of 56 patients with Crohn's disease, Knösel and co-authors reported a low CMV prevalence of 3.6% (14). Some reports reveal CMV infection to be more common in patients with refractory IBD or complicated disease (3, 4, 15, 16). However, ulcerative colitis and Crohn's disease are usually combined in calculations of CMV prevalence (15, 16). Local reactivation of CMV reportedly is detectable in one-third of IBD cases with active inflammation of the colonic mucosa, although regardless of CMV status, clinical outcome is similar (17). It has been suggested that differing immune responses between Crohn's disease and ulcerative colitis may result, in these patient groups, in differing CMV incidence rates (18).

Early treatment of CMV infection in Crohn's colitis may, according to some reports, reduce mortality and the need for emergency surgery (5, 10). In the present study, three patients underwent urgent surgery because of severe colitis. These patients were CMV negative by immunohistochemistry. Despite this finding, we agree with these investigators (5, 10) that CMV infection should be ruled out in patients with acute colitis. The clinical significance of CMV infection in mild or moderate Crohn's colitis is, however, unclear. In our study, most of the patients belonged to this category and none of them had CMV infection.

For the detection of CMV infection, we used histology and immunohistochemistry. Detection of CMV in the gastrointestinal mucosa is considered the gold standard for gastrointestinal CMV disease, and the sensitivity of histopathology is enhanced by immunohistochemistry (19), the sensitivity of which for detecting CMV may be as high as 93% (1,20). The polymerase chain reaction may enhance diagnostic yield, but the specificity of this test in detecting active CMV infection is low (19).

Patients with corticosteroid-dependent and -refractory IBD are commonly treated with azathioprine, 6-mercaptopurine, cyclosporine, or TNF-alpha inhibitors or a combination of these, which may elevate risk for CMV infection (1, 5). Before surgery, most of our patients underwent traditional immunosuppressive therapy, infliximab therapy, or both, but our study does not support the hypothesis that these medications enhance the risk of activation of CMV infection. This finding is concordant with Italian findings of no CMV-PCR-positive patients after infliximab therapy (21). Nor did two other recent reports reveal any CMV activation during immunosuppressive therapy (18, 22).

In conclusion, our results do not support the suggestion that CMV infection is involved in the pathogenesis of Crohn's disease leading to obstructive or penetrating complications of ileocolitis and colitis. However, further studies are needed to determine the true significance of CMV infection in the exacerbation of Crohn's disease, especially in patients with severe colitis.

## Acknowledgements

This study was supported by grants from Jyväskylä Central Hospital.

## References

- 1 Kandiel A and Lashner B: Cytomegalovirus colitis complicating inflammatory bowel disease. *Am J Gastroenterol* 101: 2857-2865, 2006.
- 2 Karakozis S, Gongora E, Caceres M, Brun E and Cook JW: Life-threatening cytomegalovirus colitis in the immunocompetent patient: report of a case and review of the literature. *Dis Colon Rectum* 44: 1716-1720, 2001.
- 3 Maconi G, Colombo E, Zerbi P, Sampietro GM, Fociani P, Bosani M, Cassinotti A, Casini V, Russo A, Ardizzone S, Porta M and Bianci Porro G: Prevalence, detection rate and outcome of cytomegalovirus infection in ulcerative colitis patients requiring colonic resection. *Dig Liver Dis* 37: 418-423, 2005.
- 4 Maher MM and Nassar MI: Acute cytomegalovirus infection is a risk factor in refractory and complicated inflammatory bowel disease. *Dig Dis Sci* 54: 2456-2462, 2009.
- 5 Papadakis KA, Tung JK, Binder SW, Kam LY, Abreu MT, Targan SR and Vasiliauskas EA: Outcome of cytomegalovirus infections in patients with inflammatory bowel disease. *Am J Gastroenterol* 97: 2137-2142, 2001.
- 6 Khan FN, Prasad V and Klein MD: Cytomegalovirus enteritis mimicking Crohn's disease in a lupus nephritis patient: a case report. *World J Gastroenterol* 15: 4327-4330, 2009.
- 7 Coban S, Ensari A, Kuzuma M, Yalcin S, Palabiyikoglu M and Ormeci N: Cytomegalovirus infection in a patient with Crohn's ileocolitis. *Can J Gastroenterol* 19: 109-111, 2005.
- 8 Roses RE and JL Rombeau: Recent trends in the surgical management of inflammatory bowel disease. *World J Gastroenterol* 14: 408-413, 2008.
- 9 Aarnio M, Mecklin J-P and Voutilainen M: The role of surgery in the treatment of Crohn's disease – A retrospective analysis from a single hospital. *Scand J Surg* 99: 208-212, 2010.

- 10 Olsen S and Gilbert J: Cytomegalovirus infection in Crohn's colitis. *J Royal Soc Med* 97: 335-336, 2004.
- 11 Kuwabara A, Okamoto H, Suda T, Ajioka Y and Hatakeyama K: Clinicopathologic characteristics of clinically relevant cytomegalovirus infection in inflammatory bowel disease. *J Gastroenterol* 42: 823-829, 2007.
- 12 Epple H-J: Therapy- and non-therapy-dependent infectious complications in inflammatory bowel disease. *Dig Dis* 27: 555-559, 2009.
- 13 Lévêque N, Brixi-Benmansour H, Reig T, Renois F, Talmud D, Brodard V, Coste JF, De Champas C, Androletti L and Diebold MD: Low frequency of cytomegalovirus infection during exacerbations of inflammatory bowel diseases. *J Med Virol* 82: 1694-1700, 2010.
- 14 Knösel T, Schewe C, Petersen N, Dietel M and Petersen I: Prevalence of infectious pathogens in Crohn's disease. *Pathol Res Pract* 205: 223-230, 2009.
- 15 Dimitroulia E, Spanakis N, Konstantinidou AE, Legakis NJ and Tsakris A: Frequent detection of cytomegalovirus in the intestine of patients with inflammatory bowel disease. *Inflamm Bowel Dis* 12: 879-884, 2006.
- 16 Kishore J, Ghoshal U, Ghoshal UC, Krishnani N, Kumar S, Singh M and Ayygari A: Infection with cytomegalovirus in patients with inflammatory bowel disease: prevalence, clinical significance and outcome. *J Med Microbiol* 53: 1155-1160, 2004.
- 17 Lawlor G and Moss AC: Cytomegalovirus in inflammatory bowel disease: pathogen or innocent bystander. *Inflamm Bowel Dis* 16: 1620-1627, 2010.
- 18 Nakase H, Yoshino T, Honzawa Y and Chiba T: Low prevalence of CMV infection in patients with Crohn's disease in comparison with ulcerative colitis: effect of different immune response on prevalence of CMV infection. *Dig Dis Sci* 55: 1498-1499, 2010.
- 19 Nakase H, Matsumura K, Yoshino T and Chiba T: Systematic review: cytomegalovirus infection in inflammatory bowel disease. *J Gastroenterol* 43: 735-740, 2008.
- 20 Kambham N, Vij R, Cartwright CA and Longacre T: Cytomegalovirus infection in steroid-refractory ulcerative colitis: a case control study. *Am J Surg Pathol* 28: 365-373, 2004.
- 21 Lavagna A, Bergallo M, Daperno M, Sostegni R, Costa C, Leto R, Crocella L, Molinaro G, Rocca R, Cavallo R and Pera A: Infliximab and the risk of latent viruses reactivation in active Crohn's disease. *Inflamm Bowel Dis* 13: 896-902, 2007.
- 22 Kim JJ, Simpson N, Klipfel N, Debose R, Barr N and Laine L: Cytomegalovirus infection in patients with active inflammatory bowel disease. *Dig Dis Sci* 55: 1059-1065, 2010.

*Received September 1, 2011*

*Revised October 4, 2011*

*Accepted October 5, 2011*