

## Expression of Maspin in Colorectal Cancer

YOSHIHISA UMEKITA, MASAKAZU SOUDA and HIROKI YOSHIDA

Department of Tumor Pathology, Field of Oncology, Kagoshima University  
Graduate School of Medical and Dental Sciences, Kagoshima, Japan

**Abstract.** *Background:* Maspin, a member of the serpin family of protease inhibitors, is known to be a tumor suppressor. Although the relationship between its expression and biological significance has been investigated in several types of cancer, the clinicopathological significance of maspin expression in colorectal cancer has not been fully elucidated. *Materials and Methods:* The expression of maspin in colorectal adenocarcinomas from 104 patients (T1, T2: 20 patients, T3, T4: 84 patients) was investigated using immunohistochemical methods and the extent of tumor budding was evaluated. *Results:* The expression of maspin was observed in 66% (69 of 104) of colorectal adenocarcinomas and was significantly correlated with the depth of invasion ( $p < 0.0001$ ), higher Dukes' classification ( $p < 0.0001$ ) and high-grade tumor budding ( $>9$  foci in a field) ( $p = 0.0001$ ); however, no significant correlation was noted concerning lymph node metastases, vascular invasion and tumor differentiation. The intensity of immunostaining was most strongly observed at the invasion front, especially at the site of tumor budding. *Conclusion:* These results suggest that the expression of maspin may correlate with the aggressiveness of colorectal adenocarcinomas.

Maspin is a unique member of the serpin superfamily and is located on chromosome 18q21.3-q23, a region of frequent loss of heterozygosity in colorectal cancer (1, 2). Maspin was originally described as a tumor suppressor gene inhibiting cell motility, invasiveness and metastases (1). However, the correlation between the expression of maspin and worse prognoses has been reported in cancers of the ovary (3), breast (4, 5) and lung (6). Little is known about the expression and function of maspin and its association with clinicopathological parameters in colorectal cancer. In this study, the frequency of

maspin expression and its correlation with clinicopathological factors in colorectal adenocarcinomas was investigated using immunohistochemical methods.

### Materials and Methods

*Specimens.* The patient specimens ( $n = 104$ ) examined in this study was retrieved from the surgical pathology files of the Department of Tumor Pathology, Kagoshima University Graduate School of Medical and Dental Sciences, Japan. The average age of the patients was 73.1 years (range: 50-94 years). All tumors were histologically diagnosed as adenocarcinoma according to the WHO classification, and tumor stage was determined based on the TNM classification system (7). All patients except four underwent lymph node dissection, as well as tumor resection.

*Immunohistochemistry.* Specimens were fixed in 10% neutrally-buffered formalin and embedded in paraffin. A representative block from each case containing an adequate amount of tumor tissue and normal colorectal epithelium was selected. After blocking endogenous peroxidase activity, deparaffinized sections (3- $\mu$ m thick) were pre-treated in 10 mM citrate buffer (pH 6) by microwaving (500W, full power) for 15 min. After cooling for 60 min, the sections were incubated with primary antibodies overnight at 4°C in a moist chamber. The primary antibodies used were monoclonal anti-human maspin antibody (clone EAW24; Novocastra, Newcastle-upon-Tyne, UK) diluted 1:200. The sections were incubated with biotinylated goat anti-mouse immunoglobulin (diluted in 1:150; Vector Lab., Burlingame, CA, USA) for 15 min, followed by horseradish peroxidase-conjugated streptavidin complex for 10 min (diluted 1:100; Zymed, San Francisco, CA, USA). To visualize immunoreactivity, diaminobenzidine tetrachloride containing 0.1% hydrogen peroxidase (30% w/v) was used. A negative control was performed using non-immune serum instead of the primary antibody. The cells were considered positive only when moderate/strong cytoplasmic staining was identified. At least 3 areas with the highest degree of positive cells were selected and counted, and the percentage of positive cells was estimated semiquantitatively under light microscopy. Tumors with more than 10% of positive cells were considered as maspin-positive. Breast carcinoma tissues, previously identified as strongly positive for maspin, were used as positive controls (4).

*Tumor budding.* The presence of tumor budding was determined according to criteria proposed by Ueno *et al.* (8), wherein budding is defined as an isolated single cancer cell or a cluster composed of

*Correspondence to:* Yoshihisa Umekita, MD, Ph.D., Department of Tumor Pathology, Field of Oncology, Kagoshima University Graduate School of Medical and Dental Sciences, 8-35-1, Sakuragaoka, Kagoshima 890-8544, Japan. Tel: +81 99 275 5263, Fax: +81 99 264 6348, e-mail: umekita@m2.kufm.kagoshima-u.ac.jp

*Key Words:* Maspin, immunohistochemistry, tumor budding, colorectal cancer.

fewer than five undifferentiated cancer cells appearing to bud from a large cancer gland at the invasive front. High-grade tumor budding was defined as >9 foci in a field (x20 objective lens) (8).

*Statistical analysis.* All statistical analyses were performed using the Dr. SPSS software package (Release 8.0J; SPSS Japan Inc., Tokyo, Japan). Chi-square analysis was used to calculate the significance of differences between maspin-positive and -negative groups. The cut-off for significance was taken as  $p=0.05$ .

## Results

The immunoreactivity of maspin was cytoplasmic in carcinoma cells, and stromal fibroblasts and inflammatory cells were negative for maspin (Figure 1). The staining pattern within specimens was heterogeneous, with both positively- and negatively-stained cells evident in the tumor foci. The intensity of immunostaining was most strongly observed at the invasion front, especially at the site of tumor budding (Figure 2). Normal colonic or rectal epithelium showed negative staining or focal and patchy immunoreactivity for maspin with faint to mild staining intensity. The expression of maspin in carcinoma cells was found in 69 (66%) out of the 104 cases. There was significant association between the expression of maspin and the depth of invasion ( $p<0.0001$ ), higher Dukes' classification ( $p<0.0001$ ) and high-grade tumor budding (>9 foci in a field) ( $p=0.0001$ ) (Table I). No significant association was observed concerning lymph node metastases, vascular invasion or tumor differentiation.

## Discussion

Maspin was introduced as a tumor suppressor gene of breast and prostate cancer because it inhibited cell motility, invasion and metastases (1, 9). However, contrasting data exist as to whether its acquisition or its loss facilitates tumor progression in human breast cancer (4, 10-12). In addition, there have been several reports suggestive of a significant relationship between cytoplasmic maspin expression and clinical aggressiveness in cancer of the ovary (3), breast (4, 5), stomach (13), pancreas (14), non-small cell lung (6) and thyroid (15). On the other hand, only three reports have investigated the correlation between maspin expression and colorectal cancer (16-18). Song *et al.* first reported cytoplasmic maspin expression in 49 colonic adenocarcinomas, but no photographs of immunostains were shown and it is unclear whether a monoclonal or a polyclonal antibody was used (16). Boltze *et al.* investigated cytoplasmic maspin expression in a large number of colorectal cancers (17), but they used tissue microarray analysis which may be less sensitive than whole tissue analysis in the case of immunohistochemistry with a heterogeneous staining pattern. We have previously reported that maspin mRNA was not detected in the large intestine of rats by Northern blotting analysis (18). It has been reported

Table I. Association between expression of maspin in colorectal carcinoma and clinicopathological factors.

	Maspin expression		p-value
	Positive	Negative	
Depth of invasion			
T1, T2	3	17	<0.0001
T3, T4	66	18	
Lymph node metastases			
present	34	11	0.287
absent	35	20	
Vascular invasion			
present	45	19	0.278
absent	24	16	
Differentiation			
well	41	27	0.198
moderate	24	7	
poor	4	1	
Tumor budding			
present	23	0	0.0001
absent	46	35	
Dukes' classification			
A	2	11	<0.0001
B	34	9	
C	33	11	

that very low or nearly absent levels of maspin mRNA were detected by relative quantitative real-time PCR analysis in normal colorectal epithelium (19). In this study, normal colorectal epithelium showed negative staining or focal and patchy immunoreactivity for maspin with faint to mild staining intensity, consistent with Song *et al.* (16) and Bettstetter *et al.* (19). The proportion of positively-staining adenocarcinoma in our study was 66% (69 out of 104), similar to the report of Boltze *et al.* (69%, 193 out of 280) (17), but lower than that of Song *et al.* (75.5%, 37 out of 49) (16). To our knowledge, it was revealed for the first time that the cytoplasmic expression of maspin correlated with the depth of invasion ( $p<0.0001$ ) and higher Dukes' classification ( $p<0.0001$ ). Isolated single cancer cells and a cluster composed of fewer than five cancer cells have been defined as 'tumor budding'(18). These scattered foci are observed in the stroma of the actively invasive frontal region, and high-grade 'tumor budding' (>9 foci in a field) was suggested to be an adverse prognostic indicator in patients with colon carcinoma (8, 20). In our study, the intensity of maspin immunostaining was most strongly observed at the invasion front, especially at the site of tumor budding, and there was a positive association between maspin expression and high-grade tumor budding (>9 foci in a field). Bettstetter *et al.* (19) also reported that maspin expression was frequently found at the invasion front of colorectal cancer, however, this was nuclear maspin

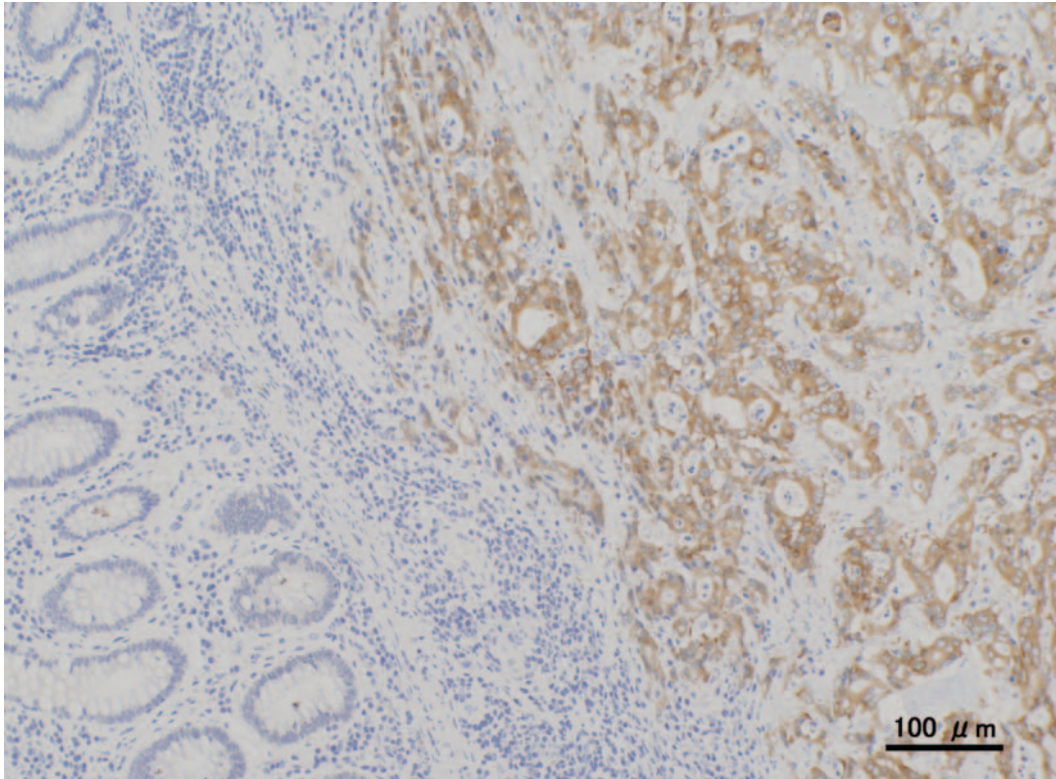


Figure 1. Cytoplasmic immunohistochemical staining for maspin in colonic adenocarcinoma. Normal colonic mucosa is unstained.

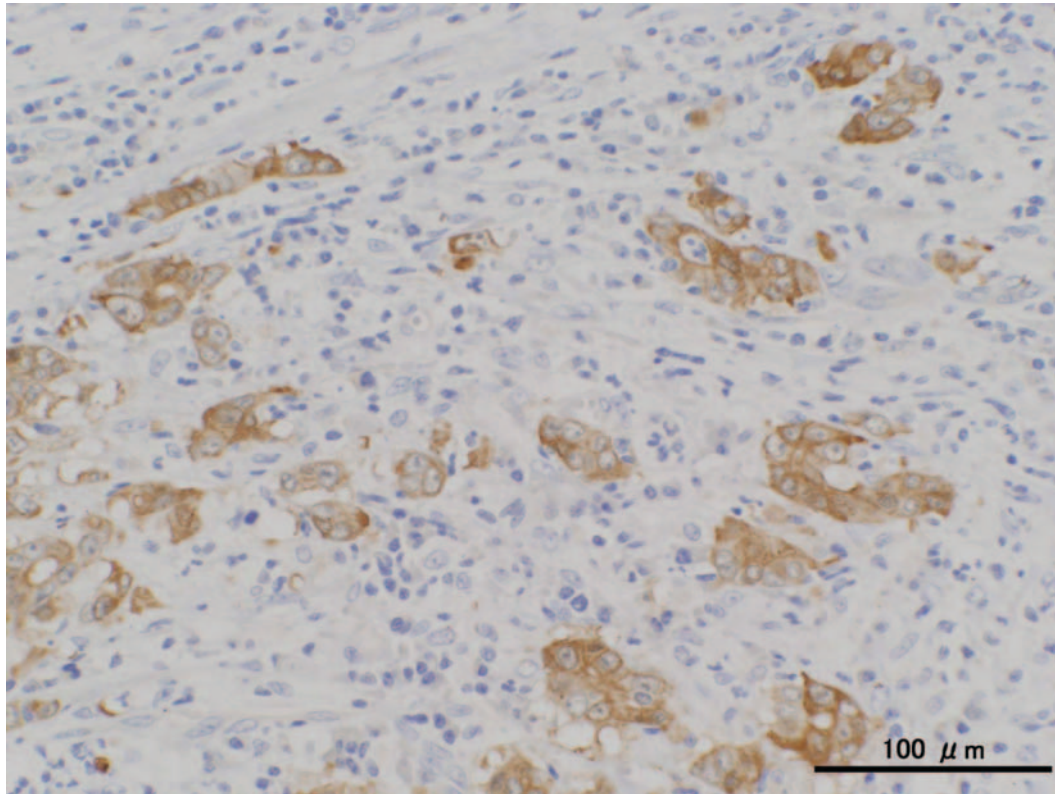


Figure 2. Representative immunohistochemical staining for maspin in tumor budding of colonic adenocarcinoma. Stromal cells are unstained.

expression, not cytoplasmic. Although a larger series and follow-up study are needed, our investigation suggested that cytoplasmic maspin expression may be correlated with the aggressive phenotype in colorectal cancer.

### Acknowledgements

We are grateful to Mr Takuro Kodama and Ms Yoshie Jitouhou for their assistance with the processing of tissue sections. This work was supported in part by Kodama Memorial Fund for Medical Research.

### References

- 1 Zou Z, Anisowicz A, Hendrix MJ, Thor A, Neveu M, Sheng S, Rafidi K, Seftor E and Sager R: Maspin, a serpin with tumor-suppressing activity in human mammary epithelial cells. *Science* 263: 526-529, 1994.
- 2 Carethers JM, Hawn MT, Greenson JK, Hitchcock CL and Boland CR: Prognostic significance of allelic loss at chromosome 18q21 for stage II colorectal cancer. *Gastroenterology* 114: 1188-1195, 1998.
- 3 Sood AK, Fletcher MS, Gruman LM, Coffin JE, Jabbari S, Khalkhali-Ellis Z, Arbour N, Seftor EA and Hendrix MJ: The paradoxical expression of maspin in ovarian carcinoma. *Clin Cancer Res* 8: 2924-2932, 2002.
- 4 Umekita Y, Ohi Y, Sagara Y and Yoshida H: Expression of maspin predicts poor prognosis in breast-cancer patients. *Int J Cancer* 100: 452-455, 2002.
- 5 Mohsin SK, Zhang M, Clark GM and Craig Allred D: Maspin expression in invasive breast cancer: association with other prognostic factors. *J Pathol* 199: 432-435, 2003.
- 6 Hirai K, Koizumi K, Haraguchi S, Hirata T, Mikami I, Fukushima M, Yamagishi S, Kawashima T, Okada D, Shimizu K and Kawamoto M: Prognostic significance of the tumor suppressor gene maspin in non-small cell lung cancer. *Ann Thorac Surg* 79: 248-253, 2005.
- 7 Stanley R, Hamilton R and Aaltonen LA (eds.): World Health Organization Classification of Tumours. Pathology and Genetics, Tumours of the Digestive System. Lyon, France, IARC Press, pp. 104-109, 2000.
- 8 Ueno H, Murphy J, Jass JR, Mochizuki H and Talbot IC: Tumour 'budding' as an index to estimate the potential of aggressiveness in rectal cancer. *Histopathology* 40: 127-132, 2002.
- 9 Sheng S, Carey J, Seftor EA, Dias L, Hendrix MJC and Sagar R: Maspin acts at the cell membrane to inhibit invasion and motility of mammary and prostatic cancer cells. *Proc Natl Acad Sci USA* 93: 11669-11674, 1996.
- 10 Maass N, Hojo T, Rosel F, Ikeda T, Jonat W and Nagasaki K: Down regulation of the tumor suppressor gene maspin in breast carcinoma is associated with a higher risk of distant metastasis. *Clin Biochem* 34: 303-307, 2001.
- 11 Maass N, Teffner M, Rosel F, Pawaresch R, Jonat W, Nagasaki K and Rudolph P: Decline in the expression of serine protease inhibitor maspin is associated with tumor progression in ductal carcinomas of the breast. *J Pathol* 195: 321-326, 2001.
- 12 Umekita Y and Yoshida H: Expression of maspin is up-regulated during the progression of mammary ductal carcinoma. *Histopathology* 42: 541-545, 2003.
- 13 Terashima M, Maesawa C, Oyama K, Ohtani S, Akiyama Y, Ogasawara S, Takagane A, Saito K, Masuda T, Kanzaki N, Matsuyama S, Hoshino Y, Kogure M, Gotoh M, Shirane M and Mori K: Gene expression profiles in human gastric cancer. Expression of maspin correlates with lymph node metastasis. *Br J Cancer* 92: 1130-1136, 2005.
- 14 Maass N, Hojo T, Ueding M, Luttgies J, Kloppel G, Jonat W and Nagasaki K: Expression of the tumor suppressor gene maspin in human pancreatic cancers. *Clin Cancer Res* 7: 812-817, 2001.
- 15 Ito Y, Yoshida Y, Tomoda C, Uruno T, Takamura Y, Miya A, Kobayashi K, Matsuzuka F, Matsuura N, Kuma K and Miyauchi A: Maspin expression is directly associated with biological aggressiveness of thyroid carcinoma. *Thyroid* 14: 132-138, 2004.
- 16 Song SY, Lee SK, Kim DH, Son HJ, Kim HJ, Lim YJ, Lee WY, Chun HK and Rhee JC: Expression of maspin in colon cancers. Its relationship with p53 expression and microvessel density. *Dig Dis Sci* 47: 1831-1835, 2002.
- 17 Boltze C: Loss of maspin is a helpful prognosticator in colorectal cancer: a tissue microarray analysis. *Pathol Res Pract* 200: 783-790, 2005.
- 18 Umekita Y, Hiipakka RA and Liao S: Rat and human maspin; structures, metastatic suppressor activity and mutation in prostate cancer cells. *Cancer Letters* 113: 87-93, 1997.
- 19 Bettstetter M, Woenckhaus M, Wild PJ, Rummele P, Blaszyk H, Hartmann A, Hofstadter F and Dietmaier W: Elevated nuclear maspin expression is associated with microsatellite instability and high tumour grade in colorectal cancer. *J Pathol* 205: 606-614, 2005.
- 20 Park KJ, Choi HJ, Roh MS, Kwon HC and Kim C: Intensity of tumor budding and its prognostic implications in invasive colon carcinoma. *Dis Colon Rectum* 48: 1597-1602, 2005.

*Received August 31, 2006  
Revised October 12, 2006  
Accepted October 17, 2006*