

## Expression of Vascular Endothelial Growth Factor (VEGF) and Association with Microvessel Density in Benign Prostatic Hyperplasia and Prostate Cancer

DIMITRIOS STEFANOU, ANNA BATISTATOU, SEVASTI KAMINA, EVDOKIA ARKOUMANI,  
DIONYSIOS J. PAPACHRISTOU and NIKI J. AGNANTIS

*Department of Pathology, University of Ioannina Medical School, 451 10, Ioannina, Greece*

**Abstract.** *Background:* Tumor angiogenesis is an absolute requirement for tumor growth and a prognostic factor for various malignant neoplasms. Recent reports in the literature have addressed the importance of the VEGF system in benign prostatic hyperplasia (BPH) and adenocarcinoma, however the results are controversial. The aim of the present study was to determine and compare the levels of VEGF expression and vascularity in BPH and prostate carcinoma. *Materials and Methods:* We examined 60 prostate adenocarcinomas and 64 benign prostatic hyperplasias. Angiogenesis was estimated by determining microvessel counts (MVC), with the use of anti-CD31 and anti-CD34 antibodies. Expression of VEGF was also evaluated immunohistochemically. *Results and Conclusion:* Our data showed that angiogenesis was more prominent in carcinomas than in BPH. Furthermore, increased MVC was significantly associated with high-grade carcinomas. Angiogenesis was correlated with VEGF expression and it was, at least in part, mediated by the latter. Thus, prostate adenocarcinoma may represent a suitable neoplasm for antiangiogenic treatment in combination with conventional therapies.

The prostate is a compound tubuloalveolar gland, which is commonly affected by two major processes, hyperplasia and malignancy. Benign prostate hyperplasia (BPH) is an extremely common disease in men over the age of 50. The cause is not completely understood, but there is little doubt that it is related to the action of androgens. Carcinoma of the prostate is the most common form of cancer in males

and the second leading cause of cancer deaths (1). Little is known about the cause of prostatic cancer, however hormone levels are believed to play a role. Prostatic carcinoma is an heterogeneous disease with various morphological patterns and underlying genetic alterations even in the same patient (2). The most consistent common denominator between benign and malignant prostate disease is angiogenesis. Angiogenesis is the generation of new blood vessels, once the primary vascular plexus has been formed. Prostate adenocarcinoma is the urological malignancy where angiogenesis may play a major role in the development and progression of the tumor. Recent experimental data have provided evidence that prostatic vasculature may be regulated by androgens in rats (3).

Solid tumor growth beyond the size of 2 mm is absolutely dependent on vascularization. Judah Folkman three decades ago revealed that tumors require new vessel formation for subsequent growth and development (4). Angiogenesis provides nutrients to growing tumor cells and it is also critical for the distant spread of neoplastic cells. The number/density of microvessels (MVC, microvessel count/MVD, microvessel density), as a measure of tumor angiogenesis, represents the neovascularization ability of the tumor and is an important prognostic factor for increased metastatic potential and worse prognosis in various human carcinomas (5-10).

In order to achieve a functional vasculature, tumor cells produce, or induce the production by other cells of a large number of angiogenic factors (11). Several growth factors and cytokines have been identified, some stimulating and some inhibiting the angiogenic process. Among them most prevalent are basic fibroblast growth factor (bFGF), angiogenin, transforming growth factor- $\beta$  (TGF- $\beta$ ) and vascular endothelial growth factor (VEGF) (12,13). VEGF is a secretory glycoprotein that acts as a specific endothelial mitogen and can induce vascularization around actively growing tumor cells. Recent studies have demonstrated the

*Correspondence to:* Professor N. J. Agnantis, MD, PhD, FRCPATH, Department of Pathology, University of Ioannina, Medical School, University Campus, P.O. Box 1186, 451 10, Ioannina, Greece. Tel: 302651097792, Fax: 30265109785, e-mail: nagnanti@cc.uoi.gr

**Key Words:** VEGF, angiogenesis, prostate, hyperplasia.

presence of increased VEGF mRNA and protein and correlated it with worse prognosis in gastric, colorectal, bladder and lung carcinomas (9,14-16).

Recent reports in the literature have addressed the issue of the importance of the VEGF system in the development of normal prostate, prostatic hyperplasia and carcinoma (1,17,18).

The aim of the present study was to determine and compare the levels of VEGF expression and vascularity in prostatic hyperplasia and carcinoma.

## Materials and Methods

Our material consisted of 60 radical prostatectomy specimens with prostate adenocarcinoma of various Gleason scores (36 low-grade, Gleason score 2-6 and 24 high-grade adenocarcinomas, Gleason score 7-10), all without lymph node metastases and 64 suprapubic prostatectomies for benign prostate hyperplasia. The mean age of the patients was 62 years for BPH (range 52-74) and 63 years for prostate adenocarcinoma (range 51-73).

**Immunohistochemistry.** We used the EnVision System and the monoclonal antibodies VEGF (Neomarkers-LabVision, Fremont, CA, USA), CD31 (DAKO, Carpinteria, CA, USA) and CD34 (Biogenex, San Ramon, CA, USA). Briefly, 5- $\mu$ m-thick histological sections from formalin-fixed paraffin-embedded blocks of tumor tissue were dewaxed in xylene, rehydrated through graded alcohols, immersed in 10mM Tris and 0.5 M EDTA, pH 9.0 and microwaved twice for 5 minutes each. Subsequently, the sections were incubated with 0.3%  $H_2O_2$  for 30 minutes to block endogenous peroxidase activity. The sections were then incubated overnight at 4°C with the primary antibodies (dilutions: VEGF, 1:50; CD31, 1:50; and CD34, 1:50). Non-specific binding was blocked by incubating the sections for 30 minutes with Blocking Solution (DAKO). Detection was carried out using the EnVision System kit (DAKO) with diaminobenzidine as chromogen. Counterstaining was performed with hematoxylin Harris.

**Microvessel detection and counting.** Vascularity was measured by the average number of CD31-and CD34-positive vessels, as described previously (19). Briefly for each slide the most intense region of neovascularization ("hot spot") was identified at low power (X10 objective lens and X10 ocular lens). Within this selected area three X200 fields were counted (X20 objective lens, X10 ocular lens, 0.72 mm<sup>2</sup> per field), and the average count of the three fields was recorded (MVC: microvessel count). In most of the counted vessels a lumen was identified. Vessels within muscular walls or lumens larger than approximately eight red blood cells were excluded from the count. Vessels had to be separated clearly from each other to be counted. No counts were performed in areas of necrosis or inflammation. In all cases MVC was determined independently by two pathologists. The median value of MVC with the use of the CD34 antibody was 90 microvessels (range: 40-200 microvessels). This count was used as the cut-off point to distinguish low from high MVC. The median value of MVC with the use of the factor CD31 antibody was 82 (range: 28-230 microvessels).

**VEGF expression.** The percentage of epithelial cells that exhibited a positive cytoplasmic immunoreactivity to VEGF was determined by counting at least 500 epithelial cells in each case. The median

value (25%) was used as the cut-off point to distinguish low (0-25% positive cells) from high (>25% positive cells) VEGF-expressing specimens. The intensity of the staining was recorded as follows:-; no staining, +; mild staining, 2+; moderate staining, 3+; intense staining.

**Statistical analysis.** For the statistical analysis, VEGF expression and MVC were considered dichotomous variables, using the cut-off values described above. VEGF and MVC were compared in the carcinoma group with respect to Gleason score with the Pearson's Chi-squared test. The strength of the association between VEGF expression and MVC was assessed with Kendall's tau-b test. Analyses were performed in SPSS 10.0. *P*-values were two-tailed.

## Results

**VEGF expression in BPH and prostatic carcinoma.** VEGF immunoreactivity was detected in 52 (81.25%) out of 64 hyperplasias and in all adenocarcinomas. Cytoplasmic immunostaining was detected in all cases (Figures 1A, 1B). In prostate cancer cases different grades expressed various intensities of VEGF staining. Specifically, 14 of the 36 low-grade carcinomas (38.9 %) and 22 of the 24 (91.7%) high-grade carcinomas showed high expression of VEGF (Table I). Besides tumor cells, in many cases tumor stromal cells and vascular endothelium were stained as well. The immunoreactivity varied from negative to strongly positive and was heterogeneous within positively stained foci. A small proportion of non-malignant glandular epithelium within prostate cancer specimens (<10% of epithelial cells) was also positively stained for VEGF, but the staining intensity was low.

BPH specimens contained foci of positively stained gland including stromal cells. 37.5% of BPH cases showed high expression of VEGF (Table I).

VEGF immunoreactivity in epithelial cells ranged from negative to strongly positive and was statistically significantly higher in malignant than in benign prostate ( $p<0.05$ ). Increased expression of VEGF was significantly associated with high tumor grade ( $p<0.01$ ). Highly differentiated carcinomas showed a predominantly low expression of VEGF (Table I).

**Microvessel counts in BPH and prostatic carcinoma.** By staining with two different antibodies, we noted small differences in microvessel staining. The central tumor areas appeared to be more highly vascularized ("hot spots"). Among the 60 prostatic carcinomas, 37 (61.7%) exhibited increased microvessel count (MVC>90) (Figure 2A). Specifically, 47.2% of the low-grade (17/36) and 83.3% of high-grade (20/24) carcinomas showed a high microvessel count (Table I). The vascular networks, as highlighted by immunohistochemistry, appeared more disorganized in malignant than in normal prostate. Regarding BPH, 50% of the cases studied exhibited high MVC (Figure 2B, Table I).

There was a statistically significant difference in MVC between BPH and prostatic carcinoma ( $p < 0.001$ ). Increased MVC was significantly associated with high tumor grade ( $p < 0.05$ ).

Assessment of the relationship between VEGF expression and angiogenesis revealed a statistically significant relationship between VEGF staining and MVC ( $p < 0.01$ ).

## Discussion

Angiogenesis in cancer plays a pivotal role in tumor growth, maintenance and metastatic potential (5-10). The new microvessels that are generated in tumors differ from those of non-neoplastic tissues. They are more fragile and irregular, with increased permeability and higher proliferation rate than that of normal endothelial cells. In current studies angiogenesis is preferentially assessed by immunodetection of the endothelial marker CD31, which recognizes the PECAM-1 endothelial membrane antigen or CD34, which displays lymphatic immunostaining as well. Immunostaining for CD31 and CD34 is more specific for capillary detection than Factor VIII, which does not stain all capillary endothelia in tumor tissues (10,20).

Much research has focused on the key molecules that regulate the new vessel formation. One of the most important angiogenetic molecules is VEGF, also known as VPF (vascular permeability factor), a potent and specific angiogenesis-related cytokine that is responsible for endothelial cell differentiation, migration, proliferation, tubular formation and vessel assembly (12). There are five known VEGF isoforms: VEGF<sup>121</sup>, VEGF<sup>165</sup>, VEGF<sup>145</sup>, VEGF<sup>189</sup> and VEGF<sup>206</sup>, of which VEGF<sup>165</sup> is the most abundant in human tissues (21). VEGF<sup>121</sup> and VEGF<sup>165</sup> are secreted isoforms and are potent mitogens for endothelial cells. In the present study we used an antibody that recognizes all isoforms. Several studies have shown that VEGF is closely correlated with the process of neovascularization and prognosis in many solid tumors (5-10, 22).

Regarding prostate cancer, it is clear that it leads to patient death when tumor cells progress to a dedifferentiated state, where they become completely androgen-independent and form metastases (mainly in bones). Several processes participate in generating such poorly-differentiated and invasive prostatic cancer cells. One of them is the formation of a network of new capillaries, which are believed to be dependent on angiogenic factors originating from neoplastic cells (1). Along these lines, in prostate gland several inducers of angiogenesis such as FGF-2, interleukin-8 (IL-8), TGF- $\beta$ 1, thymidine phosphorylase *etc.* have been shown to be expressed by the epithelial and stromal cells (23-27). Increased expression of VEGF has been observed in BPH and in prostatic cancer (24, 27-30). In cancer, it has been shown that VEGF levels correlated with Gleason score,

tumor grade and disease-free survival (28, 31). Based on such data, some investigators have proposed that VEGF-induced neovascularization begins in BPH and that it keeps progressing in a stepwise fashion in the malignant states (30, 31). However, not all researchers agree (24, 32) and thus the exact role of angiogenesis in prostate cancer has not yet been determined.

In our study, detectable VEGF staining was observed in all carcinoma cases and in a high proportion of benign hyperplasias. The localization of the immunohistochemical staining in combination with published reports on VEGF mRNA (24,30,32) support the concept that VEGF is synthesized predominantly by prostatic hyperplastic and neoplastic epithelial cells. The majority of staining of endothelial cells could be accounted for by VEGF-binding to specific endothelial cell receptors. Stromal VEGF immunoreactivity could be attributed to binding of VEGF, which is a heparin-binding growth factor, to extracellular matrix proteins (30) or to production of VEGF by stromal cells. Along these lines, stromal cells are believed to play a role in prostate cancer development and progression (33). Consistent with most reports, we noted no significant VEGF expression in normal prostatic epithelium.

In the statistical analysis of our data we noted a positive correlation between the expression of VEGF and microvessel density. This is in accordance with previous studies (19, 23), where tumor vasculature was accessed by CD31, CD34 or Factor VIII immunodetection, and reflects the impact of VEGF on the angiogenetic process of the prostate gland.

Regarding microvessel count, we observed a higher mean value in BPHs than in normal prostate, suggesting that angiogenesis plays a role in the benign neoplastic process of BPH. Thus, the hyperplastic prostate differs from the normal one from the pathological and the angiogenetic points of view.

It is not clear from the literature whether angiogenesis in prostate cancer, as expressed by MVD or MVC, is a prognostic indicator. The reports in the literature are controversial (13, 34-42). Weidner *et al.* examined patients with prostate adenocarcinoma and found a correlation between MVD and metastatic disease (34), while Brauer *et al.* found correlation between MVD and stage (35). Offersen *et al.* showed that MVD was an independent prognostic parameter useful in conjunction with other known markers in human prostate cancer (36). Silverman *et al.* examined radical prostatectomy specimens with Gleason scores between 5-7 and found that MVD correlated with PSA (37). However, Rubin *et al.* did not find any association between Gleason score, tumor stage, surgical margin status or seminal vesicle invasion (19). Bettencourt *et al.* demonstrated an association between MVD and Gleason score and tumor stage (38), and Lissbrant *et al.* showed that vascular density is a predictor of cancer-free survival in patients with adenocarcinoma (39),



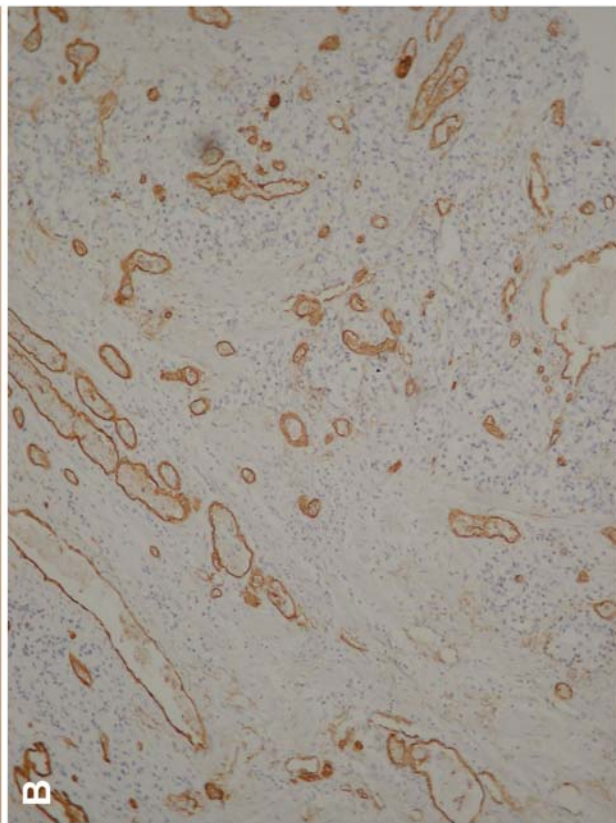
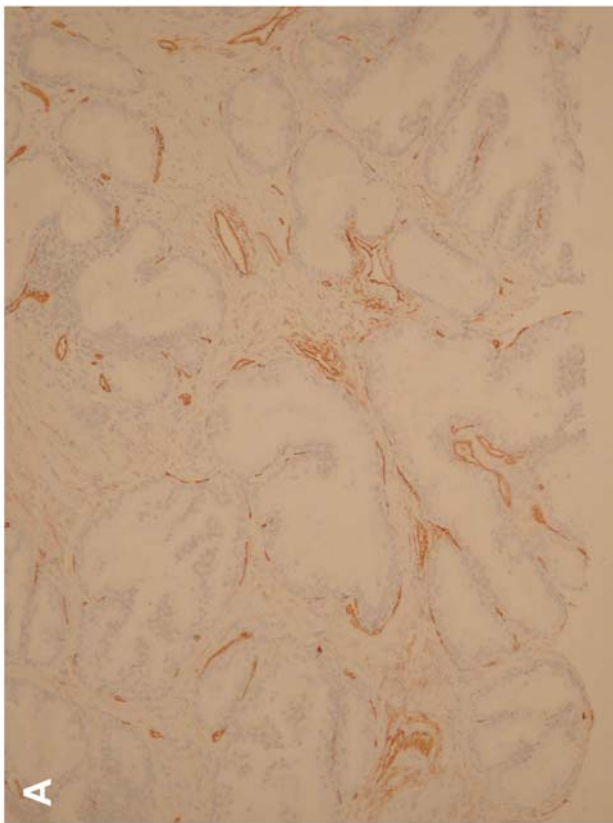


Figure 2. A. Immunohistochemical detection of CD31 in benign prostatic hyperplasia (X100).  
B. Immunohistochemical detection of CD31 in high-grade prostate carcinoma (X100).

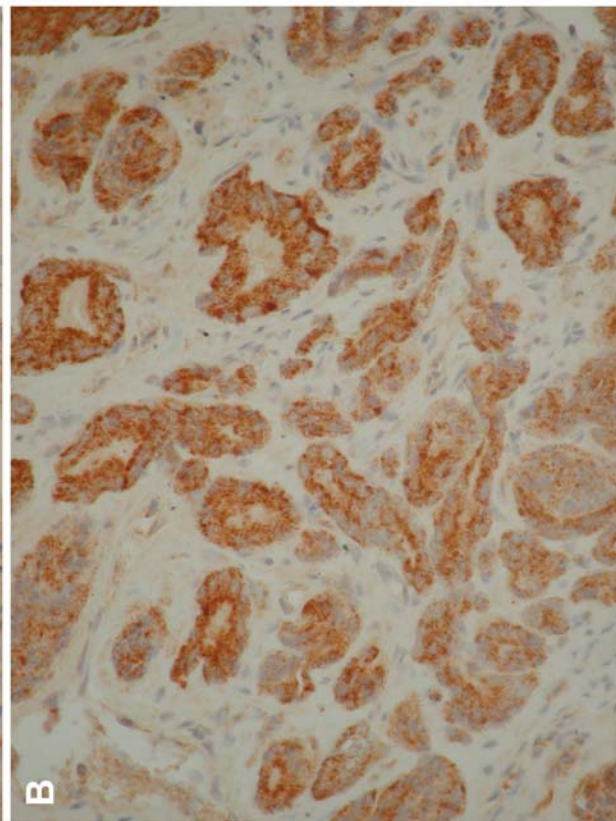
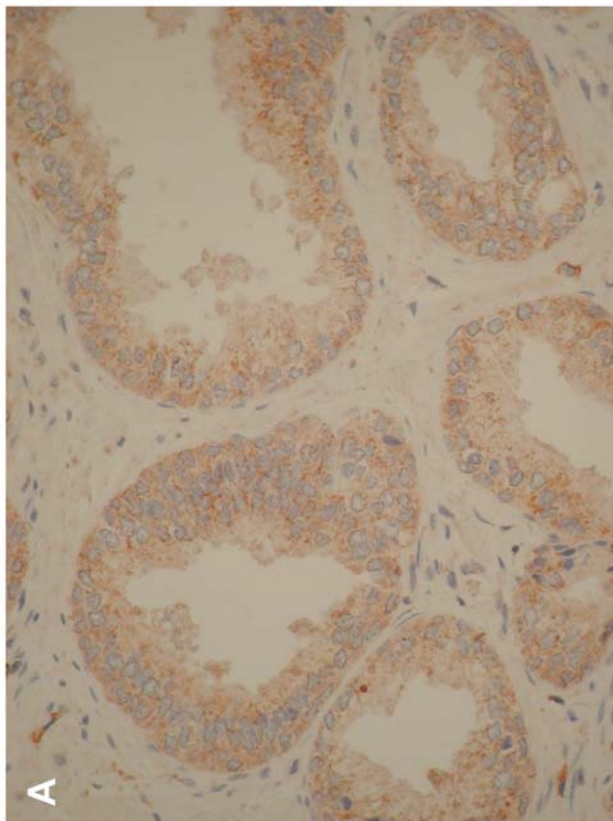


Figure 1. A. Expression of VEGF in benign prostatic hyperplasia (X400). B. Expression of VEGF in high-grade prostate carcinoma (X400).

Table I. Microvessel counts and VEGF expression in BPH and prostate carcinoma.

Histology	n	High MVC	High VEGF
BPH	64	32 (50%)	24 (37.5%)
Carcinoma			
Low-grade	36	17 (47.2%)	14 (38.9%)
High-grade	24	20 (83.3%)	22 (91.7%)

while Gettman *et al.* reported on the lack of significant microvessel density in patients with T2 adenocarcinoma of the prostate (40). We have shown that increased MVC was significantly associated with low differentiation.

Finally, our results show a widespread distribution of VEGF in prostate cancer and BPH specimens and suggest that VEGF contributes significantly to the increased vascularity observed in these conditions. Besides being an important angiogenic inducer, VEGF may play an active role in growth and progression of prostate tumors (43). This hypothesis is supported by studies showing that the VEGF and VEGF receptor Flk-1 system may be involved in the process of prostate malignant transformation and tumor progression (44). Interestingly, androgens seem to regulate VEGF expression in the prostate, since castration acts through the VEGF system to inhibit angiogenesis and thus induce apoptosis in prostatic cancer cells (45). In addition, our data indicate that the angiogenic phenomenon may have an important role in the progression of these neoplasms and this finding is in agreement with most reported studies.

In conclusion, our data showed that angiogenesis was more prominent in carcinomas than in BPH. Furthermore, increased MVC was significantly associated with high-grade carcinomas. Angiogenesis was correlated with VEGF expression and it is, at least in part, mediated by the latter. Our observations, strengthen the case for novel research avenues on VEGF and other angiogenesis-inducing molecules, which may become useful prognostic markers and serve as a basis for the development of antiangiogenic strategies within the therapeutic interventions in prostatic cancer (46,47).

## References

- Gittes RF: Carcinoma of the prostate. *N Engl J Med* 324: 236-245, 1991.
- Macintosh CA, Stower M, Reid N and Maitland NJ: Precise microdissection of human prostate cancer reveals genotypic heterogeneity. *Cancer Res* 58: 23-28, 1998.
- Burchardt M, Burchardt T, Chen MW, Hayek OR, Knight C, Shabsigh A, de La Taille A and Buttyan R: Vascular endothelial growth factor-A expression in the rat ventral prostate gland and the early effects of castration. *Prostate* 43: 184-194, 2000.
- Folkman J: What is the evidence that tumors are angiogenesis dependent? *J Nat Cancer* 82: 4-6, 1990.
- Tomisaki S, Ohno S, Ichiyoshi Y, Kuwano H, Maehara Y and Sugimachi K: Microvessel quantification and its possible relation with liver metastasis in colorectal cancer. *Cancer* 77: 1722-1728, 1996.
- Weidner N, Semple JP, Welch WR and Folkman J: Tumor angiogenesis and metastasis-correlation in invasive breast carcinoma. *N Engl J Med* 324: 1-8, 1991.
- Papamichael D: Prognostic role of angiogenesis in colorectal cancer. *Anticancer Res* 21: 4349-4353, 2001.
- Sanz-Ortega J, Steinberg SM, Moro E, Saez M, Lopez JA, Sierra E, Esponere J and Merino MJ: Comparative study of tumor angiogenesis and immunohistochemistry for p53, c-erb-B2, c-myc and EGFr as prognostic factors in gastric cancer. *Histol Histopathol* 15: 455-462, 2000.
- Giatromanolaki A: Prognostic role of angiogenesis in non-small cell lung cancer. *Anticancer Res* 21: 4373-4382, 2001.
- Teo NB, Shoker BS, Martin L, Sloane JP and Holcombe C: Angiogenesis in pre-invasive cancers. *Anticancer Res* 22: 2061-2073, 2002.
- Diaz-Flores L, Gutierrez R and Varela H: Angiogenesis: an update. *Histol Histopathol* 9: 807-843, 1994.
- Ferrara N and Davies-Smyth T: The biology of vascular endothelial growth factor. *Endocr Rev* 18: 4-25, 1998.
- Ferrara N, Houck K, Jakeman L and Leung DW: Molecular and biological properties of the vascular endothelial growth factor family of proteins. *Endocrin Rev* 13: 18-32, 1992.
- Takanashi Y, Susan LT and Kitdai Y: Vessel counts and expression of vascular endothelial growth factor as prognostic factors in node-negative colon cancer. *Arch Surg* 132: 541-546, 1997.
- Tanigawa N, Amaya H and Matsumura M: Metastasis in gastric carcinomas. *Cancer Res* 56: 2671-2676, 1996.
- Streeter EH and Crew JP: Angiogenesis, angiogenic factor expression and prognosis of bladder cancer. *Anticancer Res* 21: 4355-4363, 2001.
- Hrouda D, Nicol DL and Gardiner RA: The role of angiogenesis in prostate development and the pathogenesis of prostate cancer. *Urol Res* 30: 347-355, 2003.
- Sugamoto T, Tonji N, Sato K, Fujita H, Nishio S, Sakanaka M and Yokoyama M: The expression of basic fibroblast growth factor and vascular endothelial growth factor in prostatic adenocarcinoma: correlation with neovascularization. *Anticancer Res* 21: 77-88, 2001.
- Rubin MA, Buyyounouski M, Bagiella E, Sharir S, Neugut A, Benson A, de la Taille A, Katz AE, Olsson CA and Ennis RD: Microvessel density in prostate cancer: Lack of correlation with tumor grade, pathologic stage and clinical outcome. *Urology* 53: 542-547, 1999.
- Tsoli E, Zacharatos P, Dasiou-Plakida D, Peros J, Evangelou K, Zavras A, Yannoukakos D, Konstantopoulou I, Asimakopoulos PJ, Kittas C and Georgoulis V: Growth index is independent of microvessel density in non-small-cell lung carcinomas. *Hum Pathol* 33: 812-818, 2002.
- Yano T, Tanikawa S, Fujie T, Masutani M and Horie T: Vascular endothelial growth factor expression and neovascularization in non-small cell lung cancer. *Eur J Cancer* 36: 601-609, 2000.



- 22 Takanami I, Tanaka F, Hashizume T, Kikuchi K, Yamamoto Y, Yamamoto T and Kodaira S: Vascular endothelial growth factor and its receptor correlate with angiogenesis and survival in pulmonary adenocarcinoma. *Anticancer Res* 17: 2811-2814, 1997.
- 23 Giri D, Ropiquet F and Ittmann M: Alterations in expression of basic fibroblast growth factor (FGF)-2 and its receptor FGFR-1 in human prostate cancer. *Clin Cancer Res* 5: 1063-1071, 1999.
- 24 Ferrer FA, Miller LJ, Andawis RI, Kurtzman SH, Albertsen PC, Laudine VP and Kreutzer DL: Angiogenesis and prostate cancer: *in vivo* and *in vitro* expression of angiogenesis factors by prostate cancer cells. *Urology* 51: 161-167, 1998.
- 25 Moore BB, Arenberg DA, Stoy K, Morgan T, Addison CL, Morris SB, Glass M, Wilke C, Xue YY, Sitterding S, Kunkel SL, Burdick MD and Strieter RM: Distinct CXC chemokines mediate tumorigenicity of prostate cancer cells. *Am J Pathol* 154: 1503-1512, 1999.
- 26 Wilkstrom P, Stattin P, Franck-Lissbrant I, Damber JE and Bergh A: Transforming growth factor beta 1 is associated with angiogenesis, metastasis, and poor clinical outcome in prostate cancer. *Prostate* 37: 19-29, 1998.
- 27 Sivridis E, Giatromanolaki A, Papadopoulos I, Gatter KC, Harris AL and Koukourakis MI: Thymidine phosphorylase expression in normal, hyperplastic and neoplastic prostates: correlation with tumor-associated macrophages, infiltrating lymphocytes and angiogenesis. *Br J Cancer* 86: 1465-1471, 2002.
- 28 Kwak C, Jin RJ, Park MS and Lee SE: Thrombospondin-1, vascular endothelial growth factor expression and their relationship with p53 status in prostate cancer and benign prostatic hyperplasia. *BJU Int* 89: 303-309, 2002.
- 29 Brown LF, Yeo KT, Berse B, Morgentaler A, Dvorak HF and Rosen S: Vascular permeability factor (vascular endothelial growth factor) is strongly expressed in the normal male genital tract and is present in substantial quantities in semen. *J Urol* 154: 576-579, 1995.
- 30 Jackson MW, Bentel JM and Tilley WD: Vascular endothelial growth factor expression in prostate cancer and benign prostatic hyperplasia. *J Urol* 157: 2323-2328, 1997.
- 31 Kollerman J and Helpap B: Expression of vascular endothelial growth factor (VEGF) and VEGF receptor Flk-1 in benign, premalignant and malignant prostate tissue. *Am J Clin Pathol* 116: 115-121, 2001.
- 32 Harper ME, Glynne-Jones E, Goddard L, Thurston VJ and Griffiths K: Vascular endothelial growth factor (VEGF) expression in prostatic tumors and its relationship to neuroendocrine cells. *Br J Cancer* 74: 910-916, 1996.
- 33 Condon MS and Bosland MC: The role of stromal cells in prostate cancer development and progression. *In Vivo* 13: 61-65, 1999.
- 34 Weidner N, Carroll PRE, Flax J, Blumenfeld W and Folkman J: Tumor angiogenesis correlates with metastasis in invasive prostate carcinoma. *Am J Pathol* 143: 401-409, 1993.
- 35 Brawer MK, Deering RE, Marianne B, Preston D and Bigler SA: Predictors of pathologic stage in prostate carcinoma: the role of neovascularity. *Cancer* 73: 678-687, 1994.
- 36 Offersen BV, Borre M and Overgaard J: Immunohistochemical detection of tumor angiogenesis measured by the maximal microvessel density in human prostate cancer. *APMIS* 106: 463-469, 1998.
- 37 Silverman MA, Partin AW, Veltri RW and Epstein JI: Tumor angiogenesis correlates with progression after radical prostatectomy but not with pathologic stage in Gleason sum 5 to 7 adenocarcinoma of the prostate. *Cancer* 79: 771-779, 1997.
- 38 Bettencourt M-C, Bauer JJ, Sesterhenn IA, Connelly RR and Moul JW: CD34 immunohistochemical assessment of angiogenesis as a prognostic marker for prostate cancer recurrence after radical prostatectomy. *J Urol* 160: 459-465, 1998.
- 39 Lissbrant IF, Stattin P, Damber LE and Bergh A: Vascular density is a predictor of cancer-specific survival in prostatic carcinoma. *Prostate* 33: 38-45, 1997.
- 40 Gettman M, Bergstrahl E, Blute M, Zincke H and Bostwick DG: Prediction of patient outcome in pathologic stage T2 adenocarcinoma of the prostate: lack of significance for microvessel density analysis. *Urology* 51: 79-85, 1998.
- 41 Papadopoulos I, Sivridis E, Giatromanolaki A and Koukourakis MI: Tumor angiogenesis is associated with MUC1 overexpression and loss of prostate-specific antigen expression in prostate cancer. *Clin Cancer Res* 7: 1533-1538, 2001.
- 42 Mydlo JH, Kral JG, Volpe M, Axotis C, Macchia RJ and Pertschuk LP: An analysis of microvessel density, androgen receptor, p53 and Her-2/neu expression and Gleason score in prostate cancer. *Eur Urol* 34: 426-432, 1998.
- 43 Chevalier S, Defoy I, Lacoste J, Hamel L, Guy L, Begin LR and Aprikian AG: Vascular endothelial growth factor and signaling in the prostate: more than angiogenesis. *Mol Cell Endocrinol* 189: 169-179, 2002.
- 44 Hahn D, Simak R, Steiner G, Handisutya A, Susani M and Marberger M: Expression of the VEGF-receptor Flt-1 in benign, premalignant and malignant prostate tissues. *J Urol* 164: 506-510, 2000.
- 45 Richard C, Kim G, Koikawa Y, Salm SN, Tsujimura A, Wilson EL and Moscatelli D: Androgens modulate the balance between VEGF and angiopoietin expression in prostate epithelial and smooth muscle cells. *Prostate* 50: 83-91, 2002.
- 46 Fox WD, Higgins B, Maiese KM, Drodznjak M, Cordon-Cardo C, Scher HI and Agus DB: Antibody to vascular endothelial growth factor slows growth of an androgen-independent xenograft model of prostate cancer. *Clin Cancer Res* 8: 3226-3231, 2002.
- 47 Becker CM, Farnebo FA, Ioardanescu I, Behonick DJ, Shih MC, Dunning P, Christofferson R, Mulligan RC, Taylor GA, Kuo CJ and Zetter BR: Gene therapy of prostate cancer with the soluble vascular endothelial growth factor receptor flk1. *Cancer Biol Ther* 1: 548-553, 2002.

Received July 9, 2003

Revised October 22, 2003

Accepted December 11, 2003