

# Impact of Superoxide Dismutase-Gliadin on Radiation-induced Fibrosis: An Experimental Study

SERAP YÜCEL<sup>1</sup>, BILGEHAN ŞAHİN<sup>1</sup>, ZEYNEP GÜRAL<sup>1</sup>, VAKUR OLGAC<sup>2</sup>, GÖRKEM AKSU<sup>3</sup>, FULYA AĞAOĞLU<sup>4</sup>, ESRA SAĞLAM<sup>4</sup>, İŞİK ASLAY<sup>4</sup> and EMİN DARENDELİLER<sup>4</sup>

<sup>1</sup>Department of Radiation Oncology, Acibadem University, Istanbul, Turkey;

<sup>2</sup>Department of Pathology, Oncology Institute, and <sup>4</sup>Department of Radiation Oncology, Medical Faculty, Istanbul University, Istanbul, Turkey;

<sup>3</sup>Department of Radiation Oncology, Medical Faculty, Kocaeli University, Kocaeli, Turkey

**Abstract.** Aim: Radiation-induced fibrosis (RIF) has since long been considered as irreversible. Further understanding of its mechanisms has led to trials investigating RIF treatment and prevention. The effect of superoxide dismutase (SOD)-gliadin, an oral form of SOD that resists gastrointestinal inactivation, on RIF treatment was evaluated in this experimental study. Materials and Methods: A total of 36 Wistar albino mice were randomly distributed into four groups. According to group, 25 Gy radiation or sham-radiation were performed on day 0. Acute and late reactions were recorded. After 6 months, mice were treated with SOD-gliadin, 10,000 units per kg per day, or placebo. SOD-gliadin and placebo treatments were administered daily for 8 days by oral gavage. Later the mice were sacrificed, dissected and histopathologically analyzed. Accumulated hyaline and collagen at the dermis is an indicator of fibrosis. Therefore measurements of the dermal thickness were used to quantify the degree of RIF. Additionally, the morphological changes were analyzed, and the differences reported. Results: The mean and standard deviation for dermal thickness were 0.45±0.09 mm in the sham-irradiated placebo-treated group, 0.51 mm±0.16 mm in the sham-irradiated SOD-gliadin-treated group, 0.92 mm±0.23 mm in the irradiated placebo-treated group and 0.71 mm±0.17 mm in the irradiated SOD-gliadin-treated group. The difference in mean dermal thickness between irradiated placebo-treated and irradiated SOD-gliadin-treated mice was statistically

significant ( $p=0.002$ ). Conclusion: Quality of life while prolonging survival has an increasing importance in patients with cancer. RIF can be a crucial problem after all radiotherapy modalities. SOD-gliadin has advantageous effects on conditions that call for an increased expression of antioxidant enzymes. The results of our study suggest that oral SOD-gliadin may prevent or ameliorate RIF and patients can benefit from the positive effects of SOD.

Radiation therapy (RT) aims to provide high tumor control with the least possible damage. Radiation-induced fibrosis (RIF) is a complicated tissue response that is an extreme accumulation of extracellular matrix and dominant fibroblast proliferation after radiation. Although RIF was first described many years ago, studies explaining its mechanism of initiation and chronic processes are still ongoing. Today, with advanced technology, RT is particularly advantageous for normal tissue; however, it is not possible to completely prevent side-effects, and in some instances, the cure itself can lead to a low quality of life.

At present, progress in cellular and molecular biology technology is making the mechanism of fibrosis and atrophy understandable and providing new theoretical treatment methods. For many years, fibrosis has been defined as an irreversible accumulation of dead scar tissue. Recently, we learned that it is a dynamic process that consists of constant 'remodeling' and long-term fibroblast activation. However, the cause of continuous fibroblast activation in chronic fibrosis is still unclear (1-4).

Various factors that contribute to fibrosis have been identified, and antioxidant agents have emerged as the leading treatment. Studies have shown that these agents are efficacious for both fibrosis and RIF (5-7). Despite these studies, antioxidant agents are still not commonly used. The effects of antioxidants in treatment of RIF were first described in a French publication in 1983 (6). Liposomal

Correspondence to: Serap Yücel, Acibadem University Department of Radiation Oncology, Halkalı Merkez Mah. Turgut Ozal Bulvarı No:16 34303 Istanbul, Turkey. Tel: +90 2124044076, GSM: +90 5358181616, e-mail: serapbaskaya@yahoo.com

Key Words: Radiation-induced fibrosis, superoxide dismutase, radiotherapy late effects.

superoxide dismutase (SOD) was used to treat serious RIF and necrosis observed in two patients treated with high-dose pelvic RT. In a 1994 study, a 6-week treatment of topical SOD cream for patients with breast cancer with measurable superficial fibrosis showed that the area of fibrosis decreased by 57% on average, and 17% of the patients achieved full recovery (5). Later, an animal study was able to reproduce this effect (7). RIF was modeled with a skin dose of 160 Gy, and at 6 months post-irradiation, intramuscular SOD was applied for 3 weeks. The results were tracked clinically and with ultrasound imaging. By the twelfth week, an average 75% decrease in the width of fibrosis was observed at necropsy, providing the best result to date (at that time). In a French study that included 44 women with breast cancer with superficial RIF, topical SOD was used, and a 92% decrease in pain complaints was reported (8).

SOD is an enzyme that decomposes superoxide radicals to oxygen and hydrogen peroxide in all cells. It is proposed that increased SOD activity could stimulate other antioxidant enzymes by enhancing oxidative stress signals (9, 10). The main problem for SOD, and perhaps the cause of its limited usage, is its chemical inactivation rendering it ineffective due to low pH and high proteolytic activity in the digestive tract (11). To circumvent this bioavailability problem, several research groups designed different coatings. The most extensively studied SOD coating is wheat-derived gliadin (10, 12-15). There have been many studies that support parenteral treatment with SOD in the literature on RIF, but the response rates to oral administration is still unclear. Oral SOD preparations including SOD–gliadin are not preferred for treatment of RIF at RT centers. Herein, an animal study is described that aimed to examine the effectiveness of oral SOD–gliadin on RIF based on the experiences described in the literature.

## Methods and Materials

**Animal model and radiation.** Female Wistar albino mice aged 6-8 weeks with an average body weight of 240 to 260 g were supplied from Istanbul University Experimental Medicine Research Institute (DETAE). The study protocol was approved by the DETAE Committee on Animal Research with the protocol number of 11/12. The mice were housed two per cage, fed with standard laboratory chow, and managed according to the “The Interdisciplinary Principles and Guidelines for the Use of Animal in Research, Marketing and Education” issued by DETAE (16).

A total of 36 mice were divided randomly into four groups: i) an SOD-treated and irradiated group (S-R group, n=9); ii) placebo-treated and irradiated group (R group, n=9); iii) an SOD-treated and sham-irradiated group (S group, n=9); and iv) a placebo treated and sham-irradiated group (control; C group, n=9). The mice were anesthetized with ketamine (50 mg/kg *i.p.*) and xylazine (9 mg/50 kg *i.p.*) before irradiation. Irradiation was performed with the animal placed in the prone position. Radiation was delivered with a field

size of 4×4 cm over the right hind leg with 6 MeV electron energy at the Linear Accelerator Teletherapy Unit. A 1 cm bolus was used to obtain maximum dose at the skin with a source-to-skin distance of 100 cm seen over the bolus. Nominal standard dose (NSD) diagrams and single-fraction dose–response skin studies have shown a single dose of 21 Gy is the bioequivalent to a dose of 60 Gy delivered in 30 fractions of 2 Gy (17,18). To induce RIF and severe late effects on skin, a single fraction of 25 Gy was used. The sham-irradiated mice were handled in an identical fashion but were not irradiated.

**Radiotherapy effects.** The early skin changes were measured weekly and photographically recorded. The degree of the reaction was evaluated using Common Terminology Criteria Adverse Events (CTCAE v3.0) for acute dermatitis associated with radiation (19). The late radiation effects were assessed after 6 months from the day of irradiation or sham-irradiation by three professors of Radiation Oncology. They were blinded to the treatment groups and carried out their evaluations on mice that had been administered anesthesia with diazepam (10 mg/kg, *i.p.*). The Radiation Therapy Oncology Group late-effects scoring system was used for the evaluation (20).

**SOD treatment.** GliSODin®, a melon-derived SOD and gliadin formulation, was provided by Isocell Nutra SAS (Paris, France). The SOD activity was fixed at 10,000 U per kg per day which is above the effective dose for RIF showed by Lefaix *et al.* (21).

The day after the three physicians’ evaluation, 6 months after the day of irradiation, SOD treatment by oral gavage began. The S-R and S groups were treated with SOD. The R and C groups were not treated with SOD, but the same procedures were followed using only isotonic saline. No complications occurred during gavage. The procedure was applied daily for 8 days. On the day after completion of SOD treatment, the mice were sacrificed, and necropsy was performed.

**Histopathological evaluation.** The tissues in the irradiated field were dissected separately, fixed in formaldehyde, and embedded in paraffin. Samples were cut in coronal sections to measure 5.7 µm in thickness from the center and 1 cm inferior and superior to the center. Consequently, three slides from one coronal section were made for each mouse. All slides were stained with hematoxylin and eosin. The slides were evaluated by a blinded pathologist. To determine the degree of RIF, measurements of the dermal thickness beginning from the epidermis to the adipose tissue under the dermis were made using the computer program, Olympus Image Analysis Software analysis FIVE (Olympus Europa SE & CO. KG, Hamburg, Germany). In addition, morphological changes, such as the amount of collagen and necrosis, were noted.

**Statistical analysis.** The primary analysis compared the variable of dermal thickness between the groups. Student’s *t*-test was used to analyze the mean correspondence and  $p < 0.05$  was considered to be statistically significant.

## Results

Acute reactions were observed at the end of the second week and recorded daily. The highest scores were recorded in the third week. Interestingly, tumor growth was observed in the

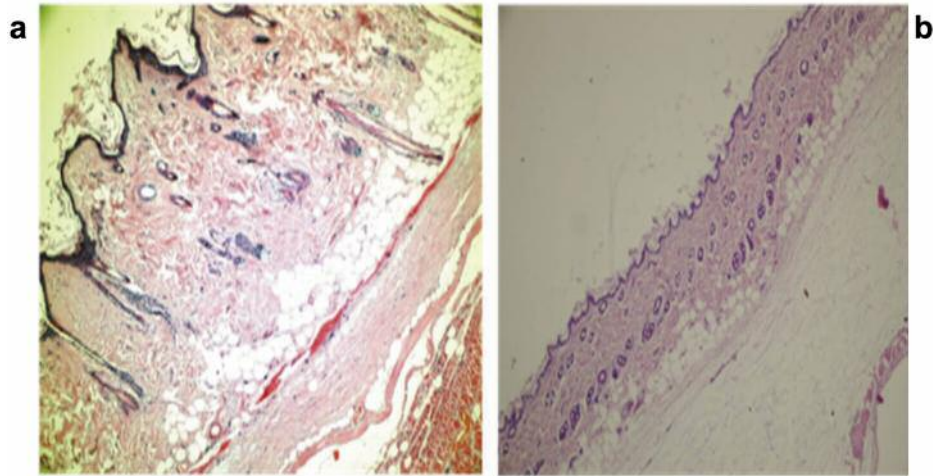


Figure 1. Pathological findings in the group R receiving radiotherapy alone (A) and group C which received placebo (B). Dermal thickness in the radiotherapy-treated group was greater due to greater deposition of collagen. The hematoxylin and eosin staining was carried out according to the regular staining method and 40-fold magnification was used.

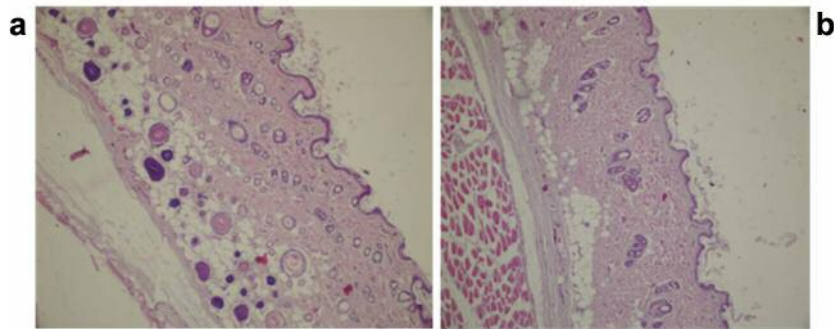


Figure 2. Pathological findings in group S-R receiving radiotherapy and superoxide dismutase (A) and group S which received only superoxide dismutase (B). Morphological differences due to the administration of radiotherapy are clearly visible. The hematoxylin and eosin staining was carried out according to the regular staining method and 100-fold magnification was used.

RT field in two mice, one in month 4 and one in month 6. Pathological analysis demonstrated RT-induced sarcoma in these mice. No abnormal changes in any other organs were observed in mice during necropsy.

For final pathological evaluation, morphological changes were recorded separately. Group R exhibited no distinctive invasion of the epidermis covering the surface. However, in the tissues under the epidermis, intense bundles of collagen fiber and hyalinizing areas were observed among the fibrosis and fibroblasts. These changes resulted in increased dermal thickness. During the same analysis, some preparations showed decreased fibrosis and fibroblasts filled with a tissue similar to hyalinized scar tissue, indicating high radiation effects. In the adipose tissue, there were many degranulated mast cells (Figure 1).

In the analysis of the S-R group, the collagen fiber bundles under the epidermis were thinner and partially shortened. The collagen fiber waste products and partly edematous connective tissues caused the dermis to thicken. Primarily non-degranulated mast cells were located at the edge of the adipose tissue and dermis (Figure 2).

The S and C groups, that were sham-irradiated with or without SOD, shared similar morphologies, and the dermis and subdermal tissue appeared normal.

The mean dermal thickness, as a predictor of RIF, was measured under microscopy for all samples. For group C, the mean dermal thickness was less than half that of group R ( $p < 0.0001$ ). The percentage difference in the dermal thickness between R and C groups was 45.24% (Table I). Thus, distinct differences were seen between the normal and

Table I. Statistical results for dermal thickness for the groups. Measurements of four groups, consisting of mice treated with only radiotherapy (RT: group R), only superoxide dismutase (SOD; group S), both RT and SOD (group S-R), and mice receiving placebo (group C), were compared. A significant difference was observed between groups with SOD usage.

Group	No SOD		SOD		Statistical comparison	
	Mean±SD (mm)	Median (range) (mm)	Mean±SD (mm)	Median (range) (mm)	t	p-Value
RT	0.92±0.23	0.95 (0.34-1.23)	0.71±0.17	0.69 (0.31-1.03)	3.347	0.002
No RT	0.45±0.09	0.44 (0.33-0.66)	0.51±0.1	0.54 (0.26-0.70)	-1.876	0.068
Difference (absolute)	0.47±0.27	0.5 (-0.09-0.83)	0.19±0.16	0.17 (-0.18-0.6)	3.5116	0.002
Difference (%)		45.24%		24.54%	2.769	0.009

irradiated tissues. The skin thickness and the morphological features were not statistically different between groups S and C. The mean dermal thickness was significantly lower for group S than group S-R ( $p=0.026$ ). There was also a significant difference between the means of the S-R and R groups ( $p=0.002$ ). The percentage difference was also significantly different between these groups ( $p=0.009$ ).

### Discussion

We performed this animal study to evaluate the impact of oral SOD–gliadin on RIF. In the initial study, SOD was the agent used to show that RIF is a curable disease (6). Although this result was a promising development for RIF treatment, the usage of SOD has not developed as expected because of the short circulatory half-life of SOD protein. Since then, SOD therapies have been combined with pharmacological agents to increase its cellular level and reach effective circulatory levels. Liposomal SOD was developed to take advantage of this mechanism; its half-life extends to nearly 24 h (7).

The likely reason that SOD usage has not become more widespread may be that its efficacy has not been demonstrated in fibrosis. Although SOD has been used in clinical trials, the effect of recovery could not be shown with objective criteria. For this study, RT fields were marked with permanent ink and sections were obtained from the center and the same distance from the center of the radiation field. Histopathological findings were evaluated as dermal thickness and comparisons between differences were also made. The recent literature presents fibrosis in two dimensions, with depth as an added measurement (7, 21). In our study, the pathologist recorded the thickness of the dermis that was bordered as a result of inflammatory reactions caused by RT and used staining techniques to identify collagen deposits in the dermis. In the literature, the possible causes of these deposits are prostaglandins, lysosomal enzymes, inflammatory reactions, and kinin system activation caused by permeability changes and the

extravasation of plasma proteins (22). An increase in collagen deposition was observed in mouse skin in the first week after RT, then decreases were reported between the 12th and 24th weeks. Collagen increase was seen again between the 36th and 48th weeks (23).

If there is scar tissue formation, which is the last stage of the fibrotic process, dermal thickness decreases. Additionally, dermal thickening hampers efforts to analyze scar formation as fibrosis. In this study, we observed decreased thickness of the dermis *via* hyalinized scar tissue in only one mouse.

The mechanisms and pharmacokinetics of SOD are well defined, and our data support using SOD–gliadin as a RIF treatment option. There have been many studies on other anti-inflammatory drugs, such as pentoxifylline and tocopherol (24-33). *In vitro* studies of pentoxifylline have shown inhibition of dermal fibroblast proliferation and extracellular matrix production and increased collagenase activity. Smaller studies on tocopherol have shown reduced RIF. However, neither tocopherol nor pentoxifylline has been reported as being a healing agent for RIF. Because of their positive effects, researchers have suggested that these drugs could act synergistically, and several studies have used combinations of these compounds (25-28). Good clinical results were observed with one combination in clinical and phase II trials. However, a “partial rebound affect” was observed with prolonged usage for over 12 months. The results of ongoing trials will be important in exploring the routine clinical usage of this combination (24).

Usage of SOD for RIF may also be limited because of suspicion of interactions between SOD, anti-inflammatory process and cancer. However, literature defining the effect of SOD on cancer are yet to be presented (34). No significant alteration of primary tumor growth were observed in the trial of Okada *et al.* (34). Additionally, the metastatic potential might be inhibited in tumor cells derived from SOD–gliadin-treated animals.

This study showed that SOD–gliadin was effective treatment for so-called ‘irreversible’ RIF. The beneficial effect

of SOD on tissues based on histopathological evaluations was demonstrated. RT should not reduce quality of life while prolonging survival in patients with cancer, and SOD–gliadin is a promising drug for such patients. SOD is a simple agent, and a principle enzyme in the natural antioxidant system. However, the lack of phase II and III clinical trials is undermining the proven clinical usage of SOD. Such studies should be conducted to ensure that patients can benefit from the positive effects of SOD in treating RIF.

## Conflicts of Interest

The Authors declare no conflict of interests in regard to this article.

## References

- Barcellos-Hoff MH: How do tissues respond to damage at the cellular level? The role of cytokines in irradiated tissues. *Radiat Res* 150(Suppl): S109-S120, 1998.
- Rodeman HP and Bamberg M: Cellular basis of radiation-induced fibrosis. *Radiation Oncol* 35: 83-90, 1995.
- Rubin P, Johnston CJ and Williams JP: A perpetual cascade of cytokines postirradiation leads to pulmonary fibrosis. *Int J Radiat Oncol Biol Phys* 33(1): 99-109, 1995.
- Skwarchuk MW and Travis EL: Changes in histology and fibrogenic cytokines in irradiated colorectum of two murine strains. *Int J Radiat Oncol Biol Phys* 42: 169-178, 1998.
- Delanian S, Baillet F and Huart J: Successful treatment of radiation-induced fibrosis using liposomal Cu/Zn superoxide dismutase: Clinical trial. *Radiation Oncol* 32: 12-20, 1994.
- Emerit J, Michelson A and Robert H: Treatment with superoxide dismutase of two cases of radiation-induced sclerosis. *Sem Hop* 59: 277-281, 1983 (in French).
- Lefaix JL, Delanian S and Leplat J-J: Successful treatment of radiation-induced fibrosis using Cu/Zn-SOD and Mn-SOD: An experimental study. *Int J Radiat Oncol Biol Phys* 35: 305-312, 1996.
- Campana F, Zervoudis S and Perdereau B: Topical superoxide dismutase reduces post-irradiation breast cancer fibrosis. *J Cell Mol Med* 8: 109-116, 2004.
- Vouldoukis I, Conti M, Krauss P, Kamate C, Blazquez S, Tefit M, Mazier D, Calenda A and Dugas B: Supplementation with gliadin-combined plant superoxide dismutase extract promotes antioxidant defences and protects against oxidative stress. *Phytother Res* 18: 957-962, 2004.
- Cloarec M, Caillard P, Provost JC, Dever JM, Elbeze Y and Zamaria N: GliSODin, a vegetal SOD with gliadin, as preventative agent versus atherosclerosis, as confirmed with carotid ultrasound-B imaging. *Eur Ann Allergy Clin Immunol* 39: 45-50, 2007.
- Regnault C, Soursac M, Roch-Arveiller M, Postaire E and Hazebroucq G: Pharmacokinetics of superoxide dismutase in rats after oral administration. *Biopharmaceut Drug Disp* 17: 165-174, 1996.
- Muth CM, Glenz Y, Klaus M, Radermacher P, Speit G and Lerverve X: Influence of an orally effective SOD on hyperbaric oxygen-related cell damage. *Free Radic Res* 38: 927-932, 2004.
- Houghton CA, Steels EL, Fassett RG and Coombes JS: Effects of a gliadin combined plant superoxide dismutase extract on self-perceived fatigue in women ages 50-65 y. *Phytomedicine* 18: 521-526, 2011.
- Mac-Mary S, Sainthillier JM, Courderotmasuyer C, Creidi P and Humbert P: Could a photobiological test be a suitable method to assess the antioxidant effect of a nutritional supplement GliSodin? *Eur J Dermatol* 17: 254-255, 2007.
- Skarpanska-Stejnborn A, Pilaczynska-Szczesniak L, Basta P, Deskur-Smielecka E, Woitas-Slubowska D and Adach Z: Effects of oral supplementation with plant superoxide dismutase extract on selected redox parameters and an inflammatory marker in a 2,000-m rowing-ergometer test. *Int J Sport Nutr Exerc Metab* 21: 124-134, 2011.
- Kucuk M, Cevik A and Kalayci R: The main applications for animal experiments. *J Exper Med* 2(4): 39-47, 2012 (in Turkish).
- Xiao Z, Su Y, Yang S, Yin L, Wang W, Yi Y, Fenton Bm, Zhang L and Okunieff P: Protective effect of esculentoside-a on radiation-induced dermatitis and fibrosis. *Int J Radiat Oncol Biol Phys* 65: 882-889, 2006.
- Archambeau JO, Pezner R and Wasserman T: Pathophysiology of irradiated skin and breast. *Int J Radiat Oncol Biol Phys* 31: 1171-1185, 1995.
- National Cancer Institute. Common Terminology Criteria for Adverse Events, Version 3.0. [http://ctep.cancer.gov/protocolDevelopment/electronic\\_applications/docs/ctcae\\_v3.pdf](http://ctep.cancer.gov/protocolDevelopment/electronic_applications/docs/ctcae_v3.pdf).
- Seegenschmiedt MH: Nebenwirkungen. *In: Der Onkologie*. Berlin, Springer, 1998.
- Molla M, Gironella M, Antonio Salas A, Closa D, Biete A, Gimeno M, Coronel P, Piquejm and Panes J: Protective effect of superoxide dismutase in radiation-induced intestinal inflammation. *Int J Radiat Oncol Biol Phys* 41: 1159-1166, 2005.
- Cooper JS, Fu K, Marks J and Silverman S. Late effects of radiation therapy in the head and neck region. *Int J Radiat Oncol Biol Phys* 31(5): 1141-1164, 1995.
- Panizzon RG, Hanson WR, Schwartz DE and Malkinson FD. Ionizing radiation induces early, sustained increases in collagen biosynthesis: A 48-week study in mouse skin and skin fibroblast, cultures. *Radiat Res* 116: 145-156, 1988.
- Delanian S, Lefaix JL and Porcher R. Randomised, placebo-controlled trial of combined pentoxifylline and tocopherol for regression of superficial radiation-induced fibrosis. *J Clin Oncol* 21(13): 2545-2550, 2003.
- Delanian S, Balla-Mekias S and Lefaix J-L: Striking regression of chronic radiotherapy damage in a clinical trial of combined pentoxifylline and tocopherol. *J Clin Oncol* 17: 3283-3290, 1999.
- Delanian S, Porcher R and Rudant J. Kinetics of response to long term treatment combining pentoxifylline and tocopherol in patients with superficial radiation-induced fibrosis. *J Clin Oncol* 23: 8570-8579, 2005.
- Georges C, Delanian S and Lefaix J-L. Resolution of progressive failed back surgery syndrome with a striking reduction of epidural fibrosis using combined pentoxifylline and tocopherol. *Br J Radiol* 77: 885-887, 2004.
- Gothard L, Cornes P and Brooker S. Phase II study of vitamin E and pentoxifylline in patients with late side-effects of pelvic radiotherapy. *Radiation Oncol* 75: 334-341, 2005.
- Cosset J-M. Breur Gold Medal Award Lecture 2001: Irradiation accidents lessons for oncology. *Radiation Oncol* 63: 1-10, 2002.

- 30 Delanian S and Lefaix JL. Current management for late normal tissue injury: radiation-induced fibrosis and necrosis. *Semin Radiat Oncol* 17: 99-107, 2007.
- 31 Gothard L, Cornes P and Earl J. Double blind placebo-controlled randomized trial of vitamin E and pentoxifylline in patients with chronic arm lymphedema and fibrosis after surgery and radiotherapy for breast cancer. *Radiother Oncol* 73: 133-139, 2004.
- 32 Haddad P, Kalaghchi B and Amouzegar-Hashemi F: Pentoxifylline and vitamin E combination for superficial radiation-induced fibrosis: A phase II clinical trial. *Radiother Oncol* 77: 324-326, 2005.
- 33 Hille A, Christiansen H and Pradier O. Effect of pentoxifylline and tocopherol on radiation proctitis/enteritis. *Strahlenther Onkol* 181: 606-614, 2005.
- 34 Okada F, Shionoya H, Kobayashi M, Kobayashi T, Tazawa H, Onuma K, Iuchi Y, Matsubara N, Ijichi T, Dugas B and Hosokawa M: Prevention of inflammation-mediated acquisition of metastatic properties of benign mouse fibrosarcoma cells by administration of an orally available superoxide dismutase. *Br J Cancer* 94(6): 854-862, 2006.

*Received February 9, 2016*

*Revised April 16, 2016*

*Accepted April 20, 2016*