

Skin Metastasis in Patient with Hairy Cell Leukemia: Case Report and Review of Literature

PASQUALE FINO, PAOLO FIORAMONTI, MARIA GIUSEPPINA ONESTI,
DANIELE PASSARETTI and NICOLÒ SCUDERI

*Department of Dermatology and Plastic, Reconstructive and Aesthetic Surgery,
La Sapienza University of Rome, Umberto I Polyclinics, Rome, Italy*

Abstract. *The reported case of Hairy cell leukemia (HCL) refers to a 47-year-old man with pancytopenia, splenomegaly, a month and a half history of dyspnea on mild effort and in common daily activities and a purplish-brown cutaneous node on the back of the left hand at the time of hospital admission. Bone marrow aspiration showed an infiltration by a lymphoproliferative malignancy and the following cytochemical studies on bone marrow sample led to diagnosis of HCL. The biopsy of the skin lesion revealed an infiltrate of medium and large-size cells in the dermis with the the same cytologic features of leukemic blasts appearing in the bone marrow, upon which the diagnosis of Leukemia cutis was established. The differential diagnosis of leukemia includes other neoplastic hematopoietic disorders, such as lymphoma, myelodysplastic syndromes, multiple myeloma, aplastic anemia, severe megaloblastic anemia, severe lymphocytosis, severe monocytosis, and bone marrow failure. In our case, the skin lesion was surgically removed and then left to heal by secondary intention due to the presence of bacterial infection by *Staphylococcus aureus* and *Streptococcus pyogenes*. The wound was finally medicated to total healing with Promogran[®], an advanced dressings which consists of a sterile, freeze-dried matrix composed of collagen and oxidised regenerated cellulose. The importance of our case lies in the fact that cases with association of HCL with leukemia cutis are very rare, and furthermore that after the excision of the skin lesion of the left hand, the surgeons heal to let the wound close by secondary intention.*

Hairy cell leukemia (HCL) is a lymphoproliferative malignancy characterized by the infiltration of bone marrow, liver, spleen, and occasionally lymph nodes with hairy cells. Hairy cells are a clone of mature memory B-cells with specific features of activation and hair-like cytoplasmic projections. The associated hematological complications, such as pancytopenia, are due not only to the enlarged spleen but probably also to hairy cells in the bone marrow. Hepatic involvement, although frequent, only occasionally leads to liver dysfunction. Infections are a major cause of morbidity and mortality in patients with HCL, presumably due to neutropenia. Other rare complications may include autoimmune disorders such as polyarthritis and vasculitis (1). Leukemia may be accompanied by two types of skin changes: the specific infiltrates, characteristic of leukemia cutis, or the nonspecific infiltrates, called leukemids. The incidence of leukemia cutis varies in different reports from 2% to 20% in patients with lymphocytic and granulocytic leukemia, and from 10% to 50% for patients with myeloid leukemia (2-4). Skin involvement is more frequent in older patients. Leukemia cutis most commonly manifests as, single or multiple erythematous papules and nodules (4). The skin lesions are located mainly on the trunk, legs and arms and only rarely on hands and feet. Leukemic changes in bone marrow or peripheral blood usually precede skin involvement and have been regarded as a factor of poor prognosis. In rare instances, leukemia cutis is the first sign of leukemia, preceding the diagnosis of systemic leukemia by several months or even years (2) .

Case Report

We report the case of a 47-year-old man with a history of HCL, for which he underwent chemotherapy. Our patient was admitted to the Emergency Department and then to the Internal Medicine ward of the Umberto I Polyclinic, University of Rome La Sapienza in July 2010. On admission, he appeared in good condition. The patient reported a month and a half history of dyspnea on mild effort and in common

Correspondence to: Pasquale Fino, MD, Department of Dermatology and Plastic, Reconstructive and Aesthetic Surgery, La Sapienza University of Rome, Policlinico Umberto I, Viale Pantelleria, 35, Scala B, Interno 1/A, 00141, Rome, Italy. Fax: +39 06/491525, e-mail: pasquale.fino@gmail.com, pasquale.fino@uniroma1.it

Key Words: Hairy cell leukemia, HCL, leukemia cutis, peripheral venous cannula.

daily activities. Physical examination revealed the presence of splenomegaly, confirmed by abdominal ultrasonography, and a purplish-brown skin nodule on the back of his left hand, approximately 2 × 2 cm, with an erythematous halo, ulcerated surface and squamous crusts (Figure 1). The skin lesion was located near the site of insertion of peripheral venous cannula which was used during previous hospitalizations for intravenous therapy.

Chest radiography showed no abnormalities. The patient also reported the occurrence of major depressive episodes which happened 19 years ago and two suicide attempts. Laboratory tests showed a significant pancytopenia (Red Blood Cell count: $2.44 \times 10^6/\text{ml}$; Hb: 8.3 g/dl, White blood cell count: $1.4 \times 10^3/\text{ml}$ (neutrophils: 16.8%; lymphocytes: 68.6%), Platelet count: $36 \times 10^3/\text{ml}$). A bone marrow aspirate was performed and revealed the presence of a lymphoproliferative malignancy, with infiltration of about 82% by cells characterized by a rich cytoplasm and an irregular margin (Figure 2). Finally an immunophenotypic study using a sample of bone marrow was performed. It showed the presence of 46% of cells expressing surface markers of B lymphocytes (CD20, CD25, CD103, DBA44, Ig light chains), 28% expressing markers of T lymphocytes (CD3), and 11% of cells expressing natural killer cell (NK) markers (CD16, CD45). Based on these results, the previous diagnosis of HCL was confirmed.

In addition, a biopsy of the skin lesion on the left hand of the patient was performed, which showed infiltration of dermal tissues by leukemoid cells with the same microscopic characteristics, positive for the same surface markers of the lymphoid blasts in the bone marrow and degenerative changes of the epidermis, dermoepidermal border and collagen. The skin lesion was therefore considered to be a metastasis of the systemic leukemia and the diagnosis of leukemia cutis was established.

The skin lesion was surgically removed and then left to heal by secondary intention due to the presence of bacterial infection by *Staphylococcus aureus* and *Streptococcus pyogenes*. The wound was finally medicated to total healing with Promogran[®], an advanced dressings of Systagenix Wound Management Ltd., Gargrave, North Yorkshire, U.K. Promogran[®] consists of a sterile, freeze-dried matrix composed of collagen and oxidised regenerated cellulose. In the presence of wound exudate, the matrix absorbs liquid and forms a soft, conformable, biodegradable gel that physically binds and inactivates matrix metalloproteases, which have a detrimental effect on wound healing when present in excessive quantities (5). The gel also binds to naturally occurring growth factors within the wound and protects them from degradation by the proteases, releasing them back into the wound in an active form as the matrix is slowly broken down. The matrix, which also has hemostatic properties, can be used in conjunction with compression therapy (Figures 3-5).

Discussion

The cases of HCL associated with leukemia cutis reported in the literature are very few, with a total of approximately 15, published from September 1979 until the current day (1, 6-19). In particular, four of these studies (6, 8, 10, 16) reported skin lesions at the presentation of leukemia, and three others reported on a detailed clinical review analyzing data from pools of 235 (11), 725 (12) and 84 (13) patients. Leukemia cutis occurs in approximately 8% of patients with HCL (9-10). In our study, the male patient developed a nodular eruption at the site of the exit of a peripheral venous cannula on the back of left hand and the histopathologic examination revealed an infiltrate of leukemia cells that was diagnosed as HCL. The differential diagnosis of leukemia (2) includes other neoplastic hematopoietic disorders, such as lymphoma, myelodysplastic syndromes, multiple myeloma, aplastic anemia, severe megaloblastic anemia due to folate or vitamin B12 deficiency, severe lymphocytosis due to infection such as Epstein-Barr Virus, severe monocytosis due to tuberculosis, and bone marrow failure with release of early cells such as in myelophthisis due to carcinoma. Examination of the bone marrow nearly always excludes the non-hematopoietic conditions because of the presence of, or due to increased number of blast cells.

Specific cutaneous lesions in leukemia (leukemia cutis), are characterized by skin infiltration by leukemic cells and usually occurs in the setting of marrow, peripheral blood, and internal organ involvement (2). Patients with leukemia typically present with a 1-to 4-month history of fatigue or malaise, easy bruisability or frank bleeding, dyspnea, minimal to modest weight loss, fever, bone pain, or abdominal pain. The physical examination typically shows pallor, consistent with anemia, and hemorrhage (in the gums, as epistaxis, in the stool, in the skin as petechiae or ecchymoses, or as fundal hemorrhage). Less commonly, there is hepatic or splenic enlargement and lymphadenopathy. Fever and infection, usually of respiratory origin, are frequent; sepsis may occur. Neurologic signs and symptoms are rare at presentation (2).

Leukemia cell dermal infiltration at the site of a venous cannula is an extremely rare phenomenon. Hitherto there have been few reported cases of leukemic dermal infiltrate, and particularly at the exit site of a central venous catheter (3, 20-22). The mechanism that leads to the preferential localization of this infiltration in the exit site of a peripheral venous cannula are not known. The presence of a previous hematoma or cannula infection has been etiologically linked to this phenomenon. Leukemia cells are known to migrate to skin windows and abrasions more rapidly and to form clusters in tissue cultures more readily than normal leukocytes, although this is particularly true for leukemia monocytes (3). Furthermore, leukemic infiltrates frequently arise in scars from recent surgery, trauma, burns, herpes

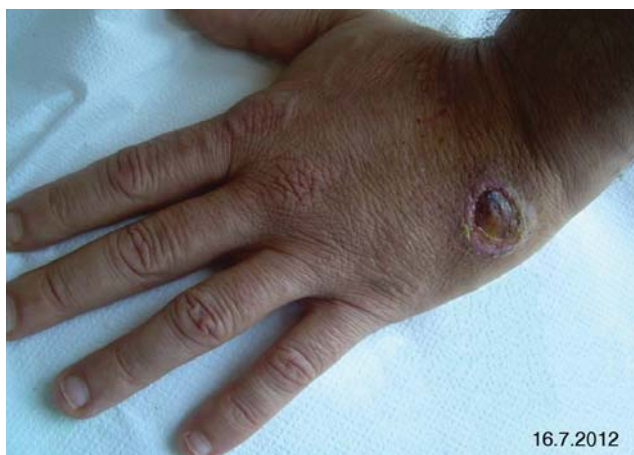

Figure 1. Purplish-brown skin nodule on the back of left hand, approximately 2 × 2 cm, with an erythematous halo, ulcerated surface and squamous crusts.

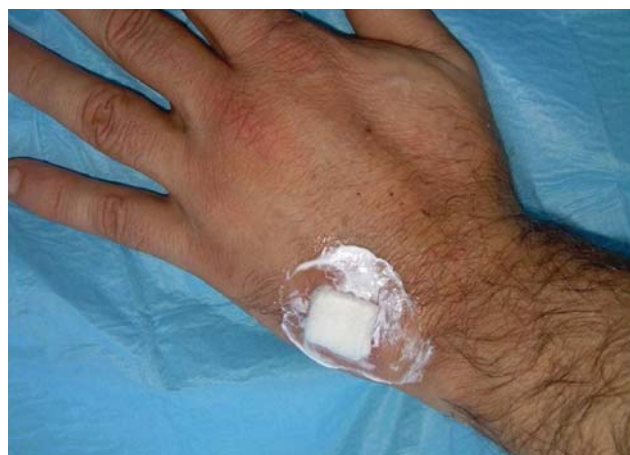

Figure 3. Advanced dressings (Promogran®) to total healing of the wound.

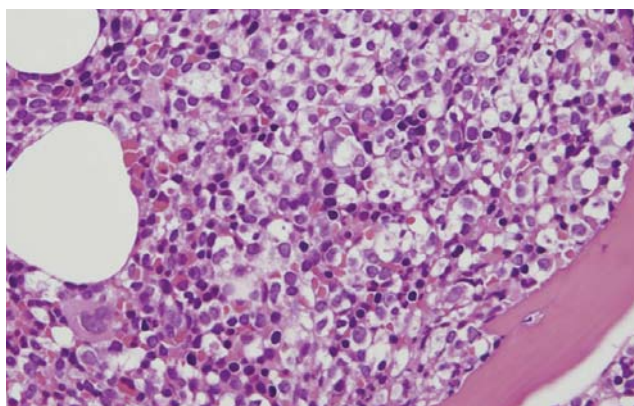


Figure 2. Photomicrography of the bone marrow biopsy: note that infiltration of atypical lymphocytes characterized by a rich cytoplasm and an irregular margin. (H&E stain, original magnification ×400).

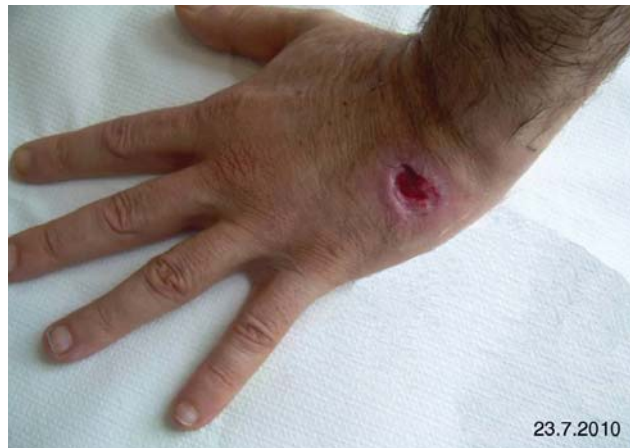

Figure 4. Wound during the process of re-epithelialization.

zoster, herpes simplex and in sites of intramuscular injections. However, these mechanisms are not the only ones to be involved in these skin lesions (3).

Conclusion

The importance of our case lies in the fact that the cases with associating HCL with leukemia cutis are very rare, but also due to the fact that after the excision of the skin lesion of the left hand, the surgeons chose to let the wound heal by secondary intention, although patients with leukemia do cicatrize more poorly than other patients because of the more frequent presence of the bacterial infection at the site of excision.

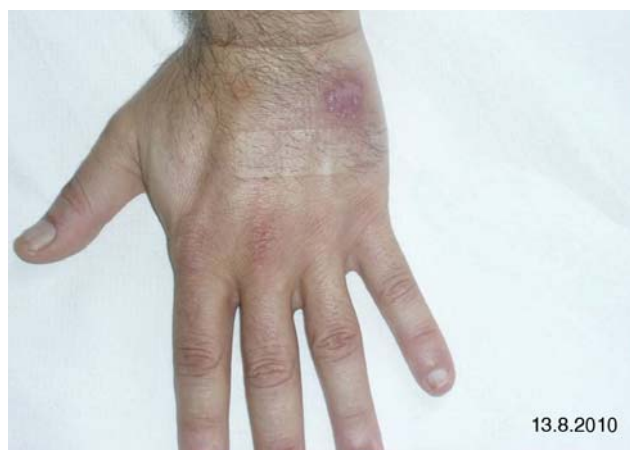

Figure 5. Re-epithelialization of the wound.

References

- 1 Remková A, Halcín A, Stenová E, Babál P, Kasperová V and Vranovský A: Acute vasculitis as a first manifestation of hairy cell leukemia. *Eur J Intern Med* 18(3): 238-240, 2007.
- 2 Arias F, Vives R and Gómez-Dorransoro ML: Cutaneous nodes in a patient with advanced papillary carcinoma of the thyroid. *Clin Transl Oncol* 8(9): 692-693, 2006.
- 3 Martino R, Sureda A, Sitjas D, Nomdedéu J and Domingo-Albòs A: Leukemic dermal infiltrate at the exit site of a central venous catheter. *Haematologica* 78(2): 132-134, 1993.
- 4 Tziotziou C and Makrygeorgou A: Leukemia cutis. *Cleve Clin J Med* 78(4): 226-227, 2011.
- 5 Wysocki AB, Staniano-Coico L and Grinnell F: Wound fluid from chronic leg ulcers contains elevated levels of metalloproteinases MMP-2 and MMP-9. *J Invest Dermatol* 101: 64-68, 1993.
- 6 Bilsland D, Shahriari S, Douglas WS, Chaudhuri AK and Todd WT: Transient leukaemia cutis in hairy-cell leukaemia. *Clin Exp Dermatol* 16(3): 207-209, 1991.
- 7 Su WP: Clinical, histopathologic, and immunohistochemical correlations in leukemia cutis. *Semin Dermatol* 13(3): 223-230, 1994.
- 8 Lawrence DM, Sun NCJ, Mena R and Moss R: Cutaneous lesions in hairy cell leukemia. Case report and review of the literature. *Arch Dermatol* 119: 322-325, 1983.
- 9 Raanani P, Thaler M, Keller N and Ben-Bassat I: Skin lesions in a patient with hairy cell leukaemia. *Postgrad Med J* 73(860): 375-377, 1997.
- 10 Arai E, Ikeda S, Itoh S and Katayama I: Specific skin lesions as the presenting symptom of hairy cell leukemia. *Am J Clin Pathol* 90: 459-464, 1988.
- 11 Damasio EE, Spriano M, Repetto M, Vimercati AR, Rossi E, Occhini D and Marmont AM: Hairy cell leukemia: a retrospective study of 235 cases by the Italian Cooperative Group (ICGHCL) according to Jansen's clinical staging system. *Acta Haematol (Basel)* 72: 326-334, 1984.
- 12 Fressoldati A, Lamparelli T and Federico M, Annino L, Capnist G, Pagnucco G, Dini E, Resegotti L, Damasio EE and Silingardi V: Hairy cell leukemia: a clinical review based on 725 cases of the Italian Cooperative Group (ICGHCL). *Leuk Lymphoma* 13: 307-316, 1994.
- 13 Carsuzaa F, Pierre C, Jaubert D and Viala JJ: Cutaneous findings in hairy cell leukemia. Review of 84 cases. *Nouv Rev Fr Hematol* 35(6): 541-543, 1994. (Article in English).
- 14 Finan MC, Su WP and Li CY: Cutaneous findings in hairy cell leukemia. *J Am Acad Dermatol* 11: 788-797, 1984.
- 15 Zak P, Chrobak L, Podyimek K, Hejzmanova D, Voglova J and Dulicek P and Mirová S: An unusual course in hairy-cell leukemia with marked abdominal lymphadenopathy, leukemic infiltration of the cornea and skin changes. *Vnitr Lek* 42: 463-466, 1996. (Article in Czech – Abstract in English)
- 16 Colović N, Peruničić M, Jurisić V and Colović M: Specific skin lesions in hairy cell leukemia at presentation: case report and review of literature. *Med Oncol* 27(2): 559-561, 2010.
- 17 Svecová D, Pallová A, Chmurová N and Babal P: Paraneoplastic vasculitis associated with hairy cell leukemia. *Prague Med Rep* 109(1): 83-87, 2008. (Article in English).
- 18 Westbrook CA and Golde DW: Autoimmune disease in hairy-cell leukaemia: clinical syndromes and treatment. *Br J Haematol* 61(2): 349-356, 1985.
- 19 Fay JW, Moore JO, Logue GL and Huang AT: Leukopheresis therapy of leukemic reticuloendotheliosis (hairy cell leukemia). *Blood* 54(3): 747-749, 1979.
- 20 Amiraian R, Penn TE, Hamann S, Asbury RF, Boros L, Markowitch W and Goodman TL: Leukemic dermal infiltrates as a complication of central venous catheter placement. *Cancer* 62(10): 2223-2225, 1988.
- 21 Baden TJ and Gammon WR: Leukemia cutis in acute myelomonocytic leukemia. Preferential localization in a recent Hickman catheter scar. *Arch Dermatol* 123(1): 88-90, 1987.
- 22 Niazi Z, Molt P, Mittelman A, Arlin ZA and Ahmed T: Leukemic dermal infiltrates at permanent indwelling central venous catheter insertion sites. *Cancer* 68(10): 2281-2283, 1991.

*Received November 5, 2011
Revised December 18, 2011
Accepted December 21, 2011*