in vivo *21*: 897-900 (2007)

Local Control and Distant Metastasis after Electrochemotherapy of a Canine Anal Melanoma

ENRICO P. SPUGNINI[1,2], MARINO FILIPPONI[3], LUCA ROMANI[3], IVAN DOTSINSKY[1], NIKOLAY MUDROV[1], ADONE BARONI[4], ELEONORA RUOCCO[4], MARIA TERESA LAIETA[5], VINCENZO MONTESARCHIO[6], ROBERTO CASSANDRO[7], GENNARO CITRO[2] and ALFONSO BALDI[1,8]

[1]*Centre of Biomedical Engineering "Ivan Daskalov", Sofia, Bulgaria;*
[2]*S.A.F.U. Department, Regina Elena Cancer Institute, Rome;*
[3]*Centro Veterinario Casal Monastero, Rome;*
[4]*Department of Dermatology,*
[5]*Istituto di Medicina del Lavoro, and* [8]*Department of Biochemistry, Section of Pathology, Second University of Naples, Naples;*
[6]*Third Division, Cotugno Hospital, Naples;*
[7]*San Giuseppe Hospital, Service of Pneumology, Milan, Italy*

Abstract. *Canine anal melanoma is an aggressive neoplasm that rapidly leads to constipation in dogs, thus mimicking the behavior of their human counterpart. In this paper, the successful local palliation of this neoplasm is described using cisplatin selectively driven within the tumor cells by trains of biphasic pulses. The dog experienced tumor reduction with restoration of normal defecation for three months, then experienced massive dissemination to the sublumbar lymph nodes that led to intestinal obstruction and euthanasia. Electrochemotherapy (ECT) is a safe palliative therapy for such neoplasm and warrants further investigations in dogs as well humans.*

Malignant melanocytic tumor are rather common canine tumors and have local aggressive behavior and a tendency for distal spread (1-2), The anus and perianal tissues are very unusual locations for malignant melanoma (MM) in domestic animals, with the exception of horses, and the vast majority of such cancers have proven to be highly malignant (3-6).

Case Report

A 6-year-old female neutered Yorkshire terrier was referred for a rapidly growing perineal mass that was causing constipation. According to the owner, the mass grew in 10 days. At presentation the dog was depressed, dehydrated, and had a large mass that almost completely obliterated the anus; digital rectal exam showed an annular mass of 10 cm in length that completely obstructed the anal canal (Figure 1A). A surgical biopsy was performed after the patient's sedation with a combination of medetodimine and ketamine as per manufacturers' instructions. The excised biopsy tumor specimen was fixed in 10% buffered-formalin and paraffin embedded. Sections of 5 μ were stained with haematoxylin-eosin, haematoxylin-van Gieson μm and PAS-haematoxylin. For immunohistochemistry, the avidin-biotin complex (ABC) method was applied. Antigen retrieval was performed on the slides by placing them in a bath of 10 mM citric acid (pH 6) and boiling for 16 min using an autoclave. The polyclonal antibody against Melan-A (DAKO, Carpinteria, CA, USA) was used at 1:200 dilution.

The histopathology exam showed that the neoplasm was made up of two different cell type: solid sheets of round to polygonal cells with interlacing bundles of fusiform cells. Most neoplastic cells contained coarse brown pigment granules in the cytoplasm, while the number of mitotic figures varied markedly and was as high as 7 per high-power field (x400). Neoplastic cells invaded both the stratified squamous epithelium of the anal sac and the external anal sphinter (Figure 1B). Immunohistochemistry showed that some of the round and fusiform neoplastic cells strongly expressed Melan A, which is a melanocyte tumor antigen (Figure 1C). The histological and immunohistochemical characteristics of this tumor were consistent with malignant melanoma.

The tumor was staged with a complete blood cell count, serum biochemical profile, urinalysis, chest radiographs

Correspondence to: Enrico P. Spugnini, SAFU Department Regina Elena Cancer Institute, Via delle Messi d'Oro 156,00158 Rome, Italy. Tel. +39 0652662512, Fax +39 0652662505, e-mail: info@enricospugnini.net

Key Words: Biphasic pulses, cisplatin, dog, anal melanoma, immunohistochemistry.

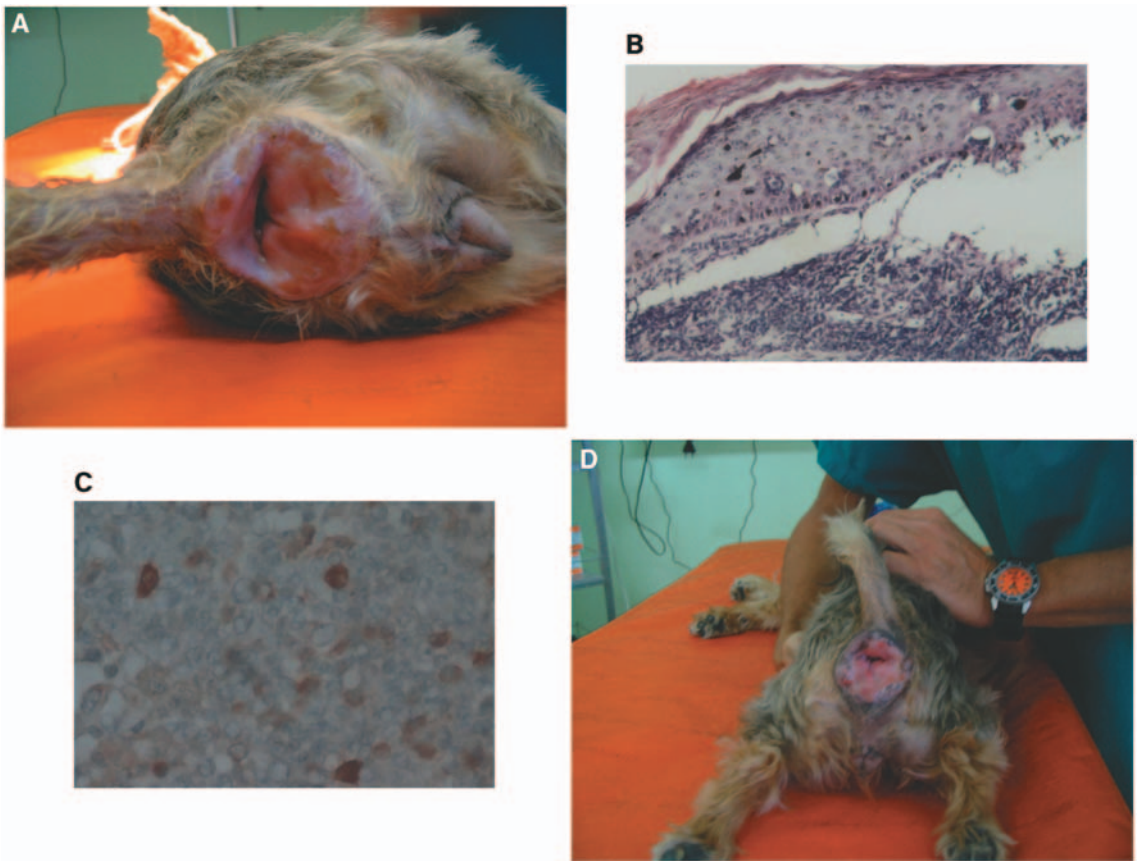

Figure 1. *Anal melanoma in a six-year-old female Yorkshire terrier. A) Gross appearance of the lesion before the treatment; B) Histological appearance of the neoplasm, showing the characteristics of a melanoma (haematoxylin/eosin; original magnification x20); C) The neoplastic cells express the melanocytic antigen Melan A (ABC; original magnification, x40); D) Gross appearance of the lesion after the treatment. Note the significant reduction of the neoplasm.*

(three projections) and abdominal ultrasonography. All the tests were within reference limits and the imaging studies showed no evidence of metastatic spread (data not shown). At this point, therapeutic options included surgical resection of the anal sphincter, coupled with systemic chemotherapy with doxorubicin or melphalan (1, 2), palliative radiation therapy (7), or electrochemotherapy (ECT) (8-13).

Since MM is a rather chemoresistant neoplasm in dogs and hypofractionated radiation therapy was unlikely to shrink the tumor mass in a short time so as to restore anal function, ECT was chosen as the only modality of treatment. The dog was sedated with a combination of medetodimine and propofol as per manufacturers' instructions and the tumor was pretreated with a combination of hyaluronidase and lidocaine (LIDO-HYAL B Laboratori Farmaceutici Giovanni Ogna & Figli S.p.A., Milan, Italy), to dissolve the ground substance and to increase local analgesia (12). Five minutes after the injection of hyaluronidase, the tumor and 1 cm of normally appearing margin were infiltrated with cisplatin (Platinex vial 50 mg/100 ml; Bristol-Myers Squibb, Sermoneta (LT), Italy) at a concentration of 0.5 mg/ml (total dose 8 mg). Five more minutes after the infiltration of the antiblastic agent, trains of 8 biphasic electric pulses (EP) lasting 50+50 ms each, with 1 ms interpulse intervals, were delivered by means of caliper electrodes (10). Adherence was enhanced by using an electroconductive gel. The dog recovered from the treatment and received a second session one weeks later. One week later the dog was scheduled for a follow-up appointment. At that time the neoplasm showed signs of marked reduction: the size had reduced to 7x5x2 cm and the lesion was better delimited from the surrounding tissues. After two more sessions, performed one week apart, the tumor had a volume reduction of 50%, the dog was bright, alert and responsive, had good appetite and was able to defecate without the administration of oral lactulose or of enemas, as occurred during the first two weeks of treatment (Figure 1D). The dog remained in partial remission for two more months. At that time the dog returned as an emergency case due to sudden onset of constipation.

Physical exam showed that the anal tumor was still in partial remission, but a large sublumbar mass dislodging the large intestine was found. An ultrasonographic exam showed a 5x3 cm sublumbar mass; fine-needle aspiration was suggestive of metastatic spread (not shown). At that time the owner elected euthanasia.

Discussion

Anal melanoma is an aggressive neoplasm whose control poses significant problems to human and veterinary clinicians, both in terms of tumor control and of preservation of sphincter function due to its invasiveness (3, 4, 14, 15). In our patient, due to the advanced stage of the disease, it was impossible to perform a surgical resection that could allow the preservation of the dog's continence. To the best of our knowledge, this is the first report of successful ECT palliation of a perianal melanoma in a dog. ECT is a new approach to solid neoplasms that combines the systemic or local administration of a chemotherapy agent with the application of square or biphasic electric pulses (EP) so to increase the uptake of drug by the cancer cells, thus resulting in increased chemotherapy efficacy (8-13). In the past five years, our group successfully treated feline sarcomas, canine malignant melanoma and mast cell tumors with ECT, obtaining high percentages of complete remission, as well as a high number of long-term responders (11-13). Furthermore, several reports in humans have underlined the usefulness of this technique to palliate MM and specifically anal melanoma (13, 14). In the present case, ECT, despite the distant spread that ultimately led to the patient's death, was proven to be a low toxicity therapy allowing the restoration of continence without local or systemic side-effects. Further studies are needed to improve ECT control of anal MM by investigating new protocols and drugs, also in view of the possible translation of data to treatment of humans.

Acknowledgements

This work has been supported by "Grant 2005" of the Italian Ministry of Health to E.P.S. and G.C. and by grants from The International Society for the Study of Comparative Oncology, Inc. (ISSCO, President HE Kaiser) Silver Spring, MD, USA and FUTURA-Onlus to A. Baldi.

References

1 Bolton B, Calderwood Mays MB and Hall BJ: Charecteristics of canine melanomas and comparison of histology and DNA ploidy to their biologic behavior. Vet Pathol *27*: 96-102, 1990.

2 Smith Sh, Goldschmidt MH and McManus PM: A comparative review of melanocytic neoplasms. Vet Pathol *39*: 651-678, 2002.

3 Emms SG: Anal sac tumors of the dog and their response to cytoreductive surgery and chemotherapy. Aust Vet J *83*: 340-343, 2005.

4 Kim DY, Mauldin GE, Hosgood G and Cho DY: Perianal malignant melanoma in a dog. J Vet Intern Med *19*: 610-612, 2005.

5 Cotchin E: A general survey of tumors in the horse. Equine Vet J *9*: 16-21, 1977.

6 Sundberg JP, Burnstein T, Page EH, Kirkham WW and Robinson FR: Neoplasms of Equidae. J Am Vet Med Assoc *170*: 150-152, 1977.

7 Blackwood L and Dobson JM: Radiotherapy of oral malignant melanoma in dogs. J Am Vet Med Assoc *209*: 98-102, 1996.

8 Daskalov I, Mudrov N and Peycheva E: Exploring new instrumentation parameters for electrochemotherapy. IEEE Eng Med Biol Mag *18*: 62-66, 1999.

9 Spugnini EP and Porrello A: Potentiation of chemotherapy in companion animals with spontaneous large neoplasms by application of biphasic electric pulses. J Exp Clin Cancer Res *22*: 571-580, 2003.

10 Spugnini EP, Citro G and Porrello A: Rational design of new electrodes for electrochemotherapy. J Exp Clin Cancer Res *24*: 245-254, 2005.

11 Spugnini EP, Dragonetti E, Vincenzi B, Onori N, Citro G and Baldi A: Pulse mediated chemotherapy enhances local control and survival in a spontaneous canine model of primary mucosal melanoma. Melanoma Res *16*: 23-27, 2006.

12 Spugnini EP, Baldi A, Vincenzi B, Bongiorni F, Bellelli C and Porrello A: Intraoperative *versus* postoperative electrochemotherapy in soft tissue sarcomas: a preliminary study in a spontaneous feline model. Cancer Chemother Pharmacol *59*: 375-381, 2007

13 Spugnini EP, Vincenzi B, Baldi F, Citro G and Baldi A: Adjuvant electrochemotherapy for the treatment of incompletely resected canine mast cell tumors. Anticancer Res *26(6B)*: 4585-4589, 2006

14 Snoj M, Rudolf Z, Cemazar M, Jancar B and Sersa G: Successful sphincter-saving treatment of anorectal malignant melanoma with electrochemotherapy, local excision and adjuvant brachytherapy. Anticancer Drugs *16*: 345-348, 2005.

15 Kubota Y, Tomita, Tsukigi M, Kurachi H, Motoyama T and Mir LM: A case of perineal malignant melanoma successfully treated with electrochemotherapy. Melanoma Res *15*: 133-134, 2005.

Received March 12, 2007
Revised April 26, 2007
Accepted May 16, 2007